

SHORT REPORT

A Large Odontogenic Keratocyst Containing A Third Molar Tooth in The Maxillary Antrum

Kerim ORTAKOĞLU, Berkay Tolga SÜER, Metin ŞENÇİMEN

Department of Oral and Maxillofacial Surgery, Gülhane Military Medical Academy, Ankara - Turkey

Received: December 14, 2004

Key Words: Keratocyst, Carnoy's solution, Maxillary antrum, Ectopic tooth

Remnants of odontogenic epithelium persist in oral tissues after odontogenesis is complete, and from these remnants a variety of tumors and cysts might possibly arise (1). Odontogenic keratocysts (OKCs) generally occur as a multilocular or unilocular radiolucency, often in a dentigerous relationship (2). While the most common occurrence location is the posterior portion of the mandible or the mandibular ramus, other locations have also been reported, such as the anterior portion of the maxilla, the maxillary sinus and the maxillary third molar area (3). In this paper, we shall present the case report of a keratocyst, which derived from an ectopic third molar, and which displaces both the orbital floor and the lateral wall of the nose, and whose expansion involves the whole right maxillary sinus.

Case Report

A 26-year old female patient was referred to the Department of Oral and Maxillofacial Surgery complaining of intermittent pain and swelling of the right cheek. The patient's medical history revealed that she had been having these complaints for one year. She was prescribed antibiotics by a general practitioner with the diagnosis of sinusitis. Afterwards, she underwent an operation using antrostomy technique by an ear, nose and throat surgeon; however, her complaints did not improve.

Extra-oral examination revealed slight swelling and tenderness over the right cheek. Intranasal examination

showed a right intra-nasal antrostomy and the absence of the inferior turbinate. Examination of the teeth showed that all the permanent teeth were present except the right upper third molar and the posterior aspect of the right maxilla revealed a mobile second molar, which was found to give a negative response to electrical stimulation.

Plain radiographs of face and skull including paranasal sinuses were performed. The Water's view showed a dense area indicating the presence of a tooth in the right maxillary sinus (Figure 1). Subsequently, orthopantomogram and computerized tomography (CT) scans of the maxilla confirmed an ectopic tooth that looked like the upper third molar at the medial wall of the maxillary antrum (Figures 2-4). There was a mass of soft-tissue around the tooth that displaced the roof and medial wall of the right maxillary sinus.

Under general anesthesia the right maxillary antrum was entered using a Caldwell-Luc technique. The anterior and posterior walls of the maxillary antrum were eroded by the cyst, which was well encapsulated and contained cheesy keratinous material. The tooth was visualized at the medial wall of the maxillary antrum as shown in CT scans. The cyst containing the ectopic tooth totally enucleated. Inspection of the antrum showed that the maxillary roof and floor were intact, but the medial wall of the maxillary opened into the nasal cavity because of the antrostomy. The cavity was treated with Carnoy's solution to reduce the risk of a recurrence. Histology of

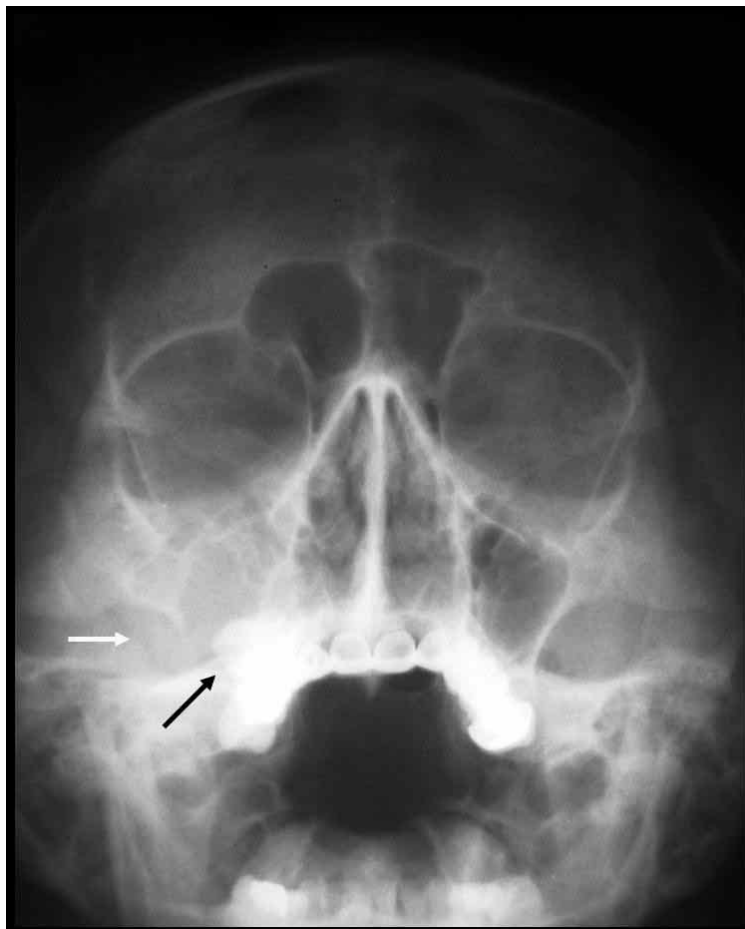


Figure 1. A Water's view showing an opaque right maxillary sinus (white arrow) with an irregular, ill-defined lateral wall and the ectopic third molar tooth in the right maxillary antrum (black arrow).

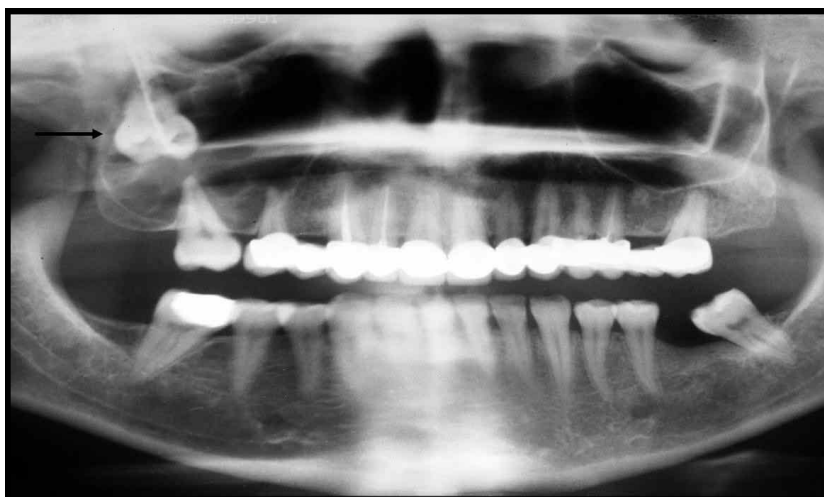

Figure 2. Pre-operative panoramic radiograph showing an osteolytic lesion in the right maxillary sinus. An ectopic third molar tooth is seen superiorly within the sinus.

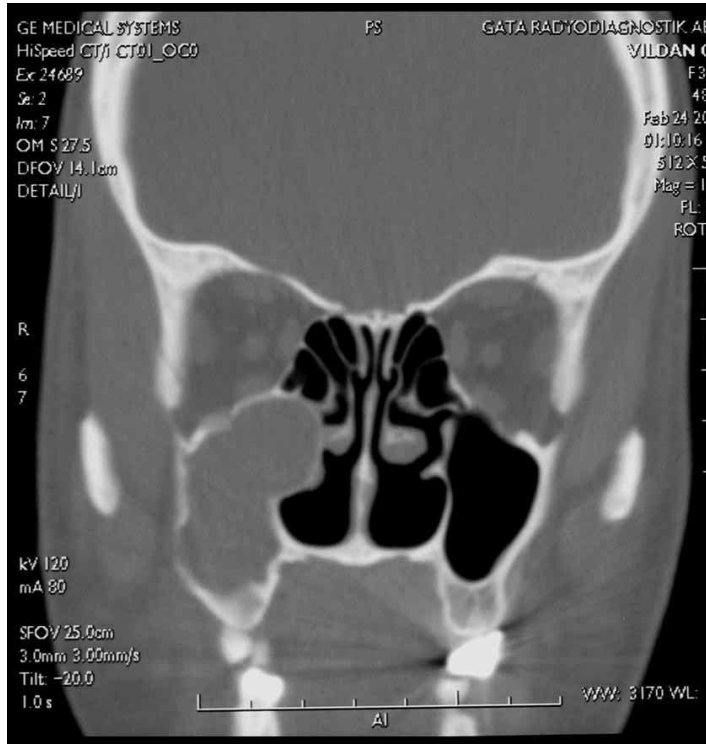


Figure 3. Coronal CT scan showing a radiolucent area on initial presentation of the patient. The radiolucent area extended to the right tuberosity region, right nasal cavity and right orbit.

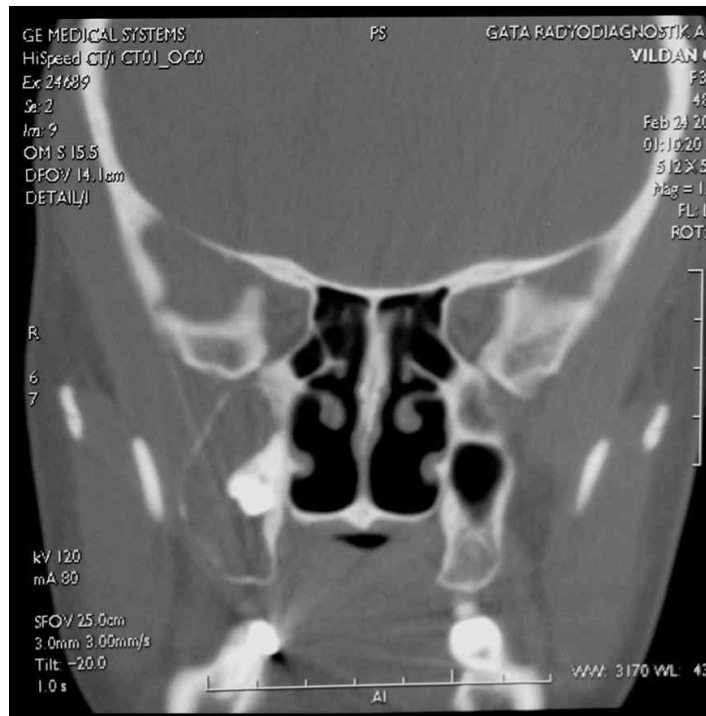

Figure 4. Coronal CT scan showing the ectopic third molar appear attached to the postero-medial wall of the sinus.

the cyst revealed that its wall was lined by parakeratinized stratified thin squamous keratinising epithelium.

The upper right second molar was extracted. The oro-antral exposure was closed by means of rotated palatal pedicle flap. The post-operative course was uneventful. Two years later, the surgical site was seen to be healing well and there was no evidence of any oro-antral communication or recurrence.

It is well known that odontogenic cysts are classified according to the nature of stimuli responsible for epithelial proliferation: developmental and inflammatory (4,5). It is also accepted that the rests of Malassez are the source of epithelium in inflammatory radicular cysts (6), whereas follicular cysts are thought to develop by passive pooling of fluid between the follicle and crown of an impacted tooth (7).

Although other odontogenic cysts including dentigerous, radicular, and residual cyst linings may become keratinized by metaplasia, these linings are distinctly different from the characteristic lining epithelium of the OKC (8,9). Therefore, although keratinization might be observed in many other types of cysts, it is distinguished by its specific histologic pattern of odontogenic keratocyst (9).

The common view is that the origin of the odontogenic keratocyst comes from dental lamina remnants in the mandible and maxilla (9,10). Another origin of the odontogenic keratocyst is from basal cells of the overlying oral epithelium (11,12).

Previously studies stated that most of the keratocysts were seen in the fifth and sixth decade; however, other studies reported a frequency in the second and third decade (5,13) and an occurrence frequency higher in males than females (5). The mandible is involved much more frequently than the maxilla, i.e. approximately a 2 to 1 ratio. The most common site is the posterior portion of the body or ramus region in the mandible. Other locations are the anterior portion of the maxilla, the maxillary third molar area and the maxillary antrum.

The most important feature of the OKC is its unusually high recurrence rate that ranges from 5% to 62.5% (3,14-17). Brannon (3) stated that the recurrence rate of keratocyst, which was treated with enucleation alone, was 12%. Browne (13) evaluated three different treatment methods, which were

marsupialization, enucleation and primary closure and enucleation and packing open.

Browne (13) concluded that there was no correlation between treatment method and the rate of recurrence. Recurrence of an OKC was due to the nature of the lesion itself, namely the presence of additional remnants of dental lamina, from which a cyst might develop. Schmidt and Pogrel (18) treated 26 keratocysts, with enucleation and cryotherapy, and three of the 26 patients (11.5%) developed a recurrence after treatment. The authors evaluated that 2 of the 3 recurrences might have been secondary to technical errors and the recurrence rate for enucleation and cryotherapy might in fact be lower than 11.5%.

Voorsmit et al (19) compared 2 treatment methods: 52 keratocysts were treated with enucleation alone, and 40 keratocysts were removed along with excision of the overlying mucosa and treatment of the cyst cavity with Carnoy's solution. In the first group, 13.5% of the cysts recurred, whereas 2.5% of the cysts in the second group recurred. In Voorsmit's series of cases, the use of Carnoy's solution and soft tissue excision gave a very low incidence of relapse.

The goal of using Carnoy's solution and cryosurgery was to kill epithelial remnants and dental lamina in the osseous margin. One advantage of liquid nitrogen is that it maintains the osseous architecture and facilitates new bone formation. Carnoy's solution is a tissue fixative that penetrates bone to a depth of 1.54 mm (19,20). The penetration and margin of cellular necrosis produced by liquid nitrogen cryosurgery in the minipig model was shown to be an average of 0.82 mm (21). In this present study we used the Carnoy's solution in addition to enucleation and aggressive curettage because of the OKCs high recurrence rate.

The main difference between OKCs and other jaw cysts are their potentially aggressive behavior. OKCs recur more often than any other type of jaw cyst. The recurrence rate is almost comparable to that of the ameloblastoma (22,23). Post-operative follow-up with annual radiological examinations is essential for at least five years following surgery. Recurrence is documented even after 10 years of follow-up and treatment. However, it is difficult to diagnose recurrence with regard to cysts in the maxillary sinus after the surgical removal of the initial lesion. Therefore CT is important in

assessing the full extent of the recurrent lesion preoperatively.

It is important to note that OKCs can be confused with inflammatory lesions since the patients with this type of cyst usually have inflammatory symptoms such as pain, swelling and drainage (24). In the presented case, our patient also had intermittent pain and swelling of the right cheek, which can also be seen in inflammatory lesions such as sinusitis. This was why she had been wrongly treated twice before she was referred our clinic.

Treatments of OKCs have ranged from marsupialization and enucleation to en bloc resection (19,25-27). According to Schmidt and Pogrel (18), the ideal treatment for the odontogenic keratocyst would be enucleation or curettage followed by treatment of the cavity with an agent such as liquid nitrogen or Carnoy's solution to kill the epithelial remnants or satellite cysts.

In this case of OKC we had success by means of enucleation, aggressive curettage and Carnoy's solution. There was no sign of recurrence on follow-up for two

years. The patient has been symptom free up to now and she is under long-term review.

The potential for recurrence of the OKC relates to the high proliferate activity of the keratocyst epithelium. Due to the high recurrence rate and aggressive behavior of OKCs, different treatment techniques can be chosen. Enucleation or curettage alone is the mostly preferred treatments in the management of OKCs.

However, we believe that it is better to use Carnoy's solution together with enucleation or curettage, since it may provide surgeons with more improved therapy by preventing the possible epithelial and dental lamina remnants which may cause recurrence.

Corresponding author:

Kerim ORTAKOĞLU

Gülhane Military Medical Academy,

Department of Oral and Maxillofacial Surgery,

06018 Etlük, Ankara - Turkey

References

1. Lund JV. Odontogenic keratocyst of the maxilla: A case report. *Br J Oral and Maxillofac Surg* 23:210-215, 1985.
2. Woo Sook-Bin, Eisenbud L, Kleiman M et al. Odontogenic keratocyst in the anterior maxilla: Report of two cases, one simulating a nasopalatine cyst. *Oral Surg Oral Oral Med Pathol* 64:463-465, 1987.
3. Brannon RB. The odontogenic keratocyst. A clinicopathologic study of 312 cases. Part I Clinical Features. *Oral Surg Oral Oral Med Pathol* 42:54-72, 1976.
4. Angelopoulou EK, Nicolatou O. Odontogenic keratocysts: Clinicopathologic study of 87 cases. *J Oral Maxillofac Surg* 48:593-599, 1990.
5. Shear M. Cysts of the oral regions (ed 2). Bristol, England, Wright PSG, p.4,1983.
6. Ten Cate AR. The epithelial cell rests of Malassez and the genesis of the dental cyst. *Oral Surg Oral Med Oral Pathol.* 34:956-964, 1972.
7. Browne RM. The pathogenesis of odontogenic cysts: a review. *J Oral Pathol* 4:31-46, 1975
8. Browne RM. The odontogenic keratocyst. Histological features and their correlation with clinical behavior. *Br Dent J* 131:249-259, 1971.
9. Regezi JA, Sciubba J. Oral Pathology. Clinical-Pathologic Correlations. 2nd ed. Philadelphia, Pennsylvania: W.B. Saunders Company. 1993, pp :337-341.
10. Brannon RB. The odontogenic keratocyst. A clinicopathologic study of 312 cases. Part II. Histological features. *Oral Surg* 43:233, 1977.
11. Stoelinga PJ. Recurrences and multiplicity of cysts. *Trans Int Conf Oral Surg* 4:77-80, 1973.
12. Stoelinga PJ. Studies on the dental lamina as related to its role in the etiology of cysts and tumors. *J Oral Pathol* 5: 65-73, 1976.
13. Browne RM. The odontogenic keratocyst: Clinical aspects. *Br Dent J* 128:225-231, 1970.
14. Voorsmit RA. The incredible keratocyst (thesis). University of Nijmegen, The Netherlands 1984.
15. Vedtofte P, Praetorius F. Recurrence of the odontogenic keratocyst in relation to clinical and histologic features: A 20-year follow-up study of 72 patients. *Int J Oral Surg* 8: 412-420, 1979.
16. Pindborg JJ, Hansen J. Studies on odontogenic cyst epithelium. 2. Clinical and roentgenographic aspects of odontogenic keratocyst. *Acta Pathol Microbiol Scand* 58: 283-294, 1963.
17. Absi EG, Sim RL. Odontogenic keratocyst involving the maxillary sinus: report of two cases. *Dentomaxillofac Radiol* 23:226-229, 1994.
18. Schmidt BL, Pogrel MA. The use of enucleation and liquid nitrogen cryotherapy in the management of odontogenic keratocysts. *J Oral Maxillofac surg* 59:720-725, 2001.
19. Voorsmit RA, Stoelinga PJ, van Haelst VJ: The management of keratocyst. *J Maxillofac Surg* 9: 228-236, 1981.

20. Williams TP, Connor FA. Surgical management of the odontogenic keratocyst: aggressive approach. *J Oral Maxillofac Surg* 52: 964-966 1994.
21. Pogrel MA, Regezi J, Fong B et al. Liquid nitrogen cryotherapy and immediate bone grafting : An animal model. *J Oral Maxillofac surg* 56:53-55 1998 (supply).
22. Ahlfors E, Larsson A, Sjögren S. The odontogenic keratocyst: a benign cystic tumor? *J Oral Maxillofac Surg* 42:10-19 1984.
23. Zachriades N, Papanicolaou S, Triantafyllou D. Odontogenic keratocysts: review of the literature and report of sixteen cases. *J Oral Maxillofac Surg* 43:177-182, 1985.
24. Tsukamoto G, Sasaki A, Akiyama T et al. A radiologic analysis of dentigerous cysts and odontogenic keratocysts associated with a mandibular third molar. *Oral Surg Oral Med Oral Pathol Oral Radiol Endod* 91:743-747, 2001.
25. Bramley PA. Treatment of cysts of the jaws. *Proc R Soc Med* 64:547-550, 1971.
26. Tucker WM, Pleasant JE, MacComb WS. Decompression and secondary enucleation of mandibular cyst: report of case. *J Oral Sur*; 30:669-673, 1972.
27. Ephros H, Yee YL. Treatment of a large odontogenic keratocyst using the Brosch procedure. *J Oral Maxillofac Surg* 49:871-874, 1991.