

SHORT REPORT

Juvenile Dermatomyositis Resistant to Steroids

Muzaffer POLAT¹, İpek AKIL¹, Tarkan İKİZOĞLU¹, Selim SERTER², Mine ÖZKOL²,
Özge YILMAZ İKİZOĞLU¹, Şenol COŞKUN¹

¹Department of Pediatrics, Faculty of Medicine Celal Bayar University, Manisa - Turkey

²Department of Radiology, Faculty of Medicine Celal Bayar University, Manisa - Turkey

Received: May 16, 2003

Key Words: Juvenile dermatomyositis, treatment, resistant to steroids

Juvenile dermatomyositis (JDM) is primarily a disease of the skin and muscle. However, systemic findings characterized by vasculitis and vasculopathy are also observed in the early phases (1). The incidence of this idiopathic inflammatory myositis (IIM) that presents with acute or chronic multisystemic destruction is 4/1,000,000 with a predominance of females and Caucasians (2). Diagnosis is suggested by clinical presentation accompanied by increased muscle enzymes and muscle MRI findings as well as a negative (-) rheumatoid factor, SS-A, SS-B, Sm, RNP and DNA (3). The frequency of calcinosis and functional deterioration that developed in 23%-70% of patients treated with historical techniques decreased significantly with high dose steroid therapy (4).

Corticosteroids, immunosuppressive agents, immunoglobulins and biological agents are used in treatment. However, a consensus on the treatment protocol has not been developed yet.

The presented case of JDM with an incidentally recognized right hypoplastic kidney did not respond to steroids but improved with methotrexate.

Case

A 9-year-old male patient presented with complaints of extremity pain over the previous month. He was referred from the medical center where he had been

started on penicillin and aminosalicylic acid treatment with a presumptive diagnosis of acute rheumatic fever. The extremity pain that appeared especially after climbing stairs limited his daily activities.

Physical examination revealed proximal muscle weakness and muscle tenderness upon palpation. Movements of the first, second and third metacarpophalangeal joints as well as of the hands, feet, knee and elbow joints were painful. Gower's sign was detected as the patient tried to stand up from a sitting position. Heliotropic rash and Gottron's papules (Figure 1) were observed.

Laboratory investigations revealed complete blood count levels of hemoglobin at 12.4 g/dl, hematocrit at 36%, white blood cells at 13,000/mm³, platelets at 420,000/mm³ and MCV at 81 fl. Erythrocyte sedimentation rate was 21 mm/h. Anti-streptolysin-O titer was 800 Todd units (normal upper limit: 240 Todd units). Rheumatologic testing revealed C-reactive protein at 28.3 mg/l, antinuclear antibody, rheumatoid factor and anti-double stranded DNA were all negative. Levels of complement 3 (N: 0.77-1.95 mg/l) and complement 4 (N: 0.07-0.4 g/l) were 1.2 g/l and 0.2 g/l respectively. Biochemical evaluations revealed aspartate aminotransferase levels of 199 IU/ml, alanine aminotransferase of 78.8 IU/ml, creatinine kinase of 5751 U/l, creatinine kinase-MB of 625 U/l, lactate dehydrogenase of 308 IU/ml and blood urea nitrogen of

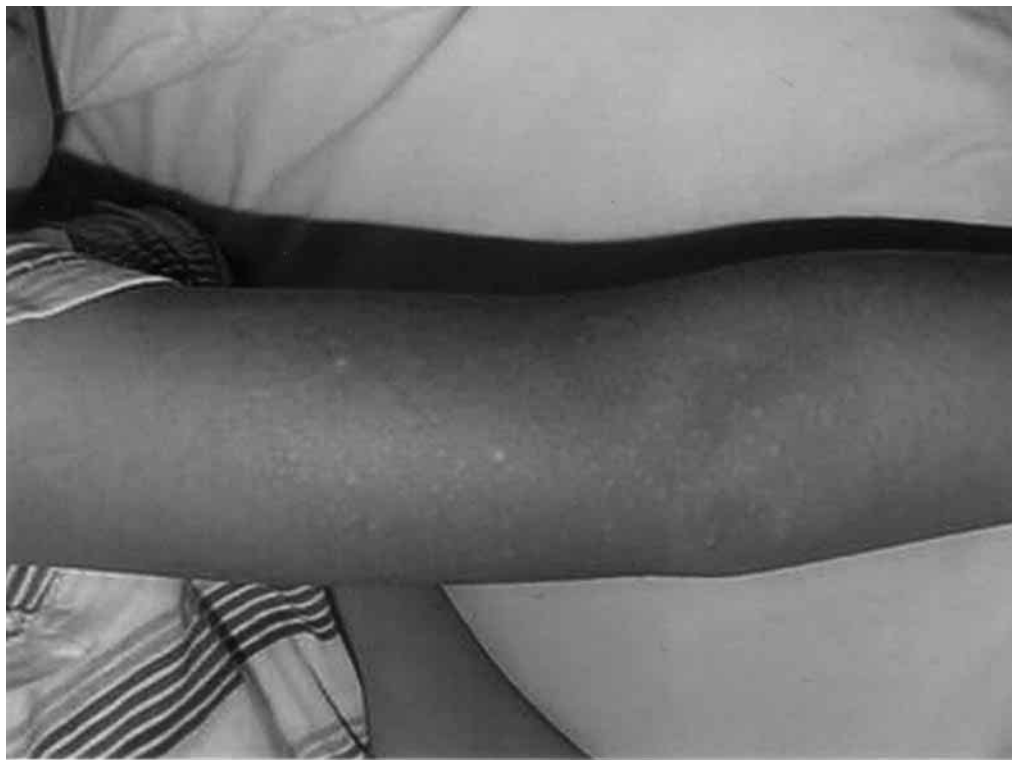

Figure 1. Gottron's papules.

34.1 mg/dl. Pulmonary function tests were normal. Occult blood in the stool was negative. ECG and echocardiography findings were normal.

Abdominal ultrasonography revealed hypoplasia of the right kidney, which was visualized as small with lobulated contours and a thin superior pole at IVP. All the calices on the right side, including the extrarenal pelvis, were dilated with convex middle and superior calices. IVP demonstrated a decreased number of calices and this confirmed the diagnosis of renal hypoplasia. Micturating cystourethrography, performed upon detection of this renal anomaly, was normal. Urine density and pH were 1025 and 5, respectively. Glomerular filtration rate, urinary protein excretion and urinary Ca/ creatinine ratio were 150 ml/min/per 1.73 m², 7.8 mg/m²/per h. and 0.48, respectively. Urinary protein levels were normal at subsequent examinations. Electrophoresis of urinary proteins revealed 43.4% albumin (N: 52-65%), 2.9% α_1 (N: 2.5-5.0%), 10.6% α_2 (N: 7-13%), 12.2% β (N: 8-14%) and 30.8% γ (N: 12-22%). Excretion of high molecular weight proteins including albumin, but not β_2 microglobulin, indicated the proteinuria to be of glomerular origin.

Esophagography, performed following the complaint of dysphagia, was normal.

Superficial muscle ultrasonography showed diffuse non homogeneous echogenicity changes among muscle plains with minimal liquid loculations. Non-homogeneous images were prominent in proximal muscles, consistent with infiltrative muscular changes in dermatomyositis. Signal intensity in anteromedial muscle groups was significantly different from that in distal areas at extremity MRI, and perimascular edema was detected (Figure 2).

EMG findings were interpreted as being in favor of muscle involvement.

The patient was diagnosed as having JDM with an incidental finding of a hypoplastic kidney.

Initial treatment consisted of 1 mg/kg prednisolone per day. However, during the second week of treatment, dysphagia developed despite the decrease in muscle findings. Therefore, oral steroid treatment was replaced with IV methylprednisolone at an equivalent dosage for 17 days. Methotrexate (15 mg/m²/per week) was added in the first week of parenteral steroid treatment to

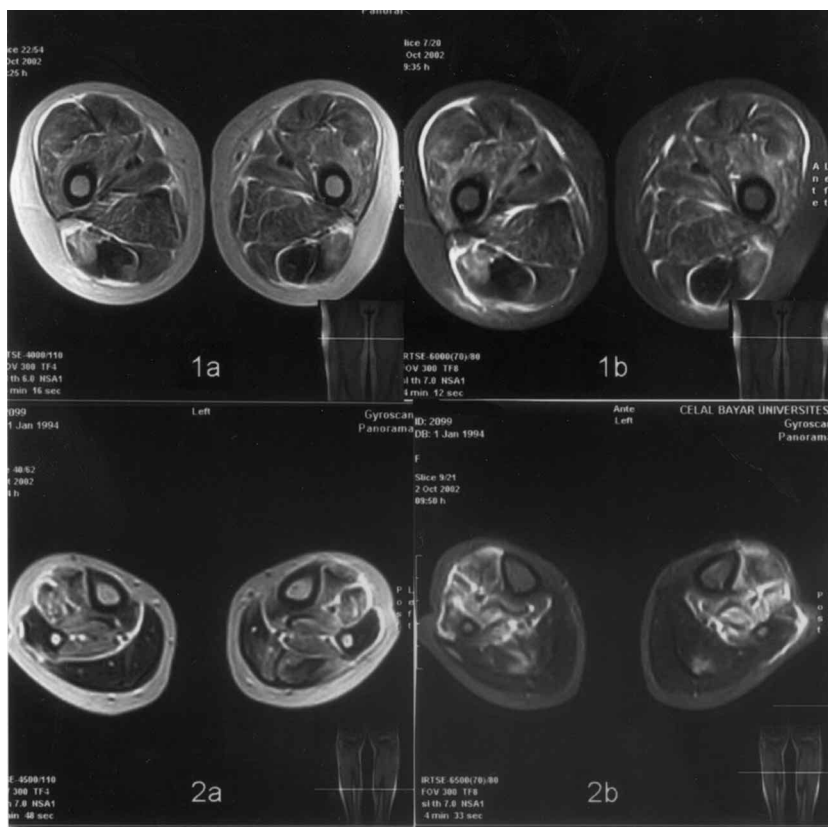


Figure 2. 1a and 1b, which are T2 weighted and fat saturated axial images of the thigh muscles, respectively, demonstrate increased size, hyperintense signal changes, and liquid intensity due to perimuscular edema in the quadriceps femoris, sartorius, adductor group and biceps femoris from the ischio-crural group muscles, as well as hyperintense signal changes in the subcutaneous fatty tissue as indicators of inflammation. 2a and b, which are T2 weighted and fat saturated axial images of the leg muscles, respectively, demonstrate similar MRI changes that are prominent in the anterior but limited in the posterior group muscles.

prevent steroid dependency. After 17 days, parenteral steroid treatment was replaced with oral steroids.

After 1 month of a combination treatment with methotrexate and steroids, muscle weakness decreased with disappearance of Gower's sign. Dysphagia disappeared slowly, as well as the edema on the patient's face. The patient was discharged after 39 days of hospitalization. He was on oral steroid and methotrexate treatment when he was discharged. He is still in remission after 1 year of follow-up despite the decrease in the steroid dose.

Idiopathic inflammatory myopathies are rare but serious systemic autoimmune diseases of childhood. The

most common of the pediatric IIMs is JDM. This autoimmune disease is characterized by inflammatory myopathy accompanied by systemic involvement of many organ systems, thought to be due to the vasculitic component of the disease (5).

Standard criteria for the diagnosis of IIM include the presence of a characteristic rash combined with at least 3 of such findings as symmetrical proximal muscle weakness, raised serum muscle enzyme levels and abnormal findings at muscle biopsy or electromyography. Bohan and Peter who proposed these criteria, distinguished JDM from the adult form by means of increased vasculitic characteristics, more common skin ulceration and calcinosis (5).

This patient, who presented with symmetrical proximal muscle weakness, raised serum muscle enzymes accompanying heliotropic rash and Gottron's papules, had positive electromyography results. Therefore, he was diagnosed as having JDM. He developed dysphagia and dysphonia during the course of the illness, which correlated with the findings from a study of a series of 69 patients, which reported 44% dysphagia and 37% dysphonia (6).

Systemic involvement includes many symptoms. For the gastrointestinal system, the most common symptom of JDM is dysphagia, which indicates a poorer prognosis (7). The other finding associated with severity of disease is change in voice. Dysphonia is a sign of nasal regurgitation and swallowing dysfunction (8). This patient had both dysphonia and dysphagia which progressed despite steroid treatment but regressed with the addition of methotrexate.

Symmetric arthralgia and/or arthritis of small joints may be observed in JDM (2). This case was misdiagnosed as acute rheumatic fever before referral to our center, which caused a delay in diagnosis and treatment. However, extremity pain decreased shortly after initiation of treatment for JDM.

Asymptomatic cardiac involvement is commonly observed in JDM patients. Nonspecific ECG changes, dysrhythmia and less commonly pericarditis and myocardial involvement may require aggressive immunotherapy (9,10). Although this patient had tachycardia, ECG and echocardiography failed to detect any pathology. Tachycardia along with high CKMB was assumed to be a nonspecific finding of myocarditis and did not respond to steroid treatment but did respond to methotrexate. Therefore, we suggest that methotrexate can be used as the initial treatment in severe systemic involvement of JDM.

Among connective tissue diseases, renal involvement is the least common in dermatomyositis. Although necrotizing vasculitis and membranous glomerulonephritis with C1q deposition have been reported in JDM, very little proof of endothelial

involvement of the kidneys exists (11,12). Although the renal involvement reported in JDM is vasculitis or glomerulonephritis, this patient was found to have a urological abnormality, which was assumed to be an incidental finding.

Steroids are the mainstay of JDM treatment, but these drugs have long-term side effects. Other disease-modifying drugs and immunosuppressives may also be used to reduce steroid use in children, especially in steroid resistant cases (4,5). In some studies, methotrexate added to steroid treatment has been shown to be effective in cases with systemic involvement, and it reduces steroid-related side effects (13). There have been recent reports on the use of methotrexate as the first line treatment for the management of JDM. This regimen may be effective in controlling disease activity while reducing the cumulative dose of steroids administered. Although a combination treatment with steroids and methotrexate is suggested as an initial treatment in cases without GIS involvement, methotrexate had to be added to the treatment at an early stage in this case due to the resistance to steroids and emergence of symptoms of impending respiratory failure (14). Although the mechanism of action of methotrexate is not known, it is thought to decrease inflammation (15). GIS and cardiac and muscle involvement in this case, which did not respond to steroid treatment, regressed dramatically with the addition of methotrexate.

In conclusion, early diagnosis and treatment of JDM with severe systemic involvement may necessitate considering methotrexate as a first line drug, due to its steroid sparing and disease modifying benefits, especially in severe cases that would not tolerate delay with a steroid treatment trial.

Corresponding author:

Ipek AKIL

6345 Sokak, 50/10, Bostanlı,

Karşıyaka, İzmir - TURKEY

E-mail: ipek.akil@bayar.edu.tr

References

1. Rider LG, Miller FW. Idiopathic inflammatory muscle disease: clinical aspects. *Baillieres Best Pract Res Clin Rheumatol* 14: 37-54, 2000.
2. Ramanan AV, Feldman BM. Clinical outcomes in juvenile dermatomyositis. *Curr Opin Rheumatol* 14: 658-62, 2002.

3. Callen JP. Dermatomyositis: diagnosis, evaluation and management. *Minerva Med* 93: 157-67, 2002.
4. Fisler RE, Liang MG, Fuhlbrigge RC et al. Aggressive management of juvenile dermatomyositis results in improved outcome and decreased incidence of calcinosis. *J Am Acad Dermatol* 47: 505-11, 2002.
5. Wedderburn LR, Li CKC. Paediatric idiopathic inflammatory muscle disease. *Best Pract Res Clin Rheumatol* 18: 345-8, 2004.
6. Pachman LM, Hayford JR, Chung A et al. Juvenile dermatomyositis at diagnosis: clinical characteristics of 79 children. *J Rheumatol* 25: 198-204, 1998.
7. Pachman LM. Juvenile dermatomyositis. Pathophysiology and disease expression. *Pediatr Clin North Am* 42: 1071-98, 1995.
8. Chandrasekaran AN, Rajendran CP, Thenmozhivalli PR et al. Spectrum of clinical and immunological features of systemic rheumatic diseases in a referral hospital in south India: juvenile dermatomyositis/polymyositis. *J Indian Rheum Assoc* 3: 141-3, 1995.
9. Brottier L, Coste P, Combe C et al. Cardiac complications of dermatopolymyositis. *Arch Mal Coeur Vaiss* 80: 1133-8, 1987.
10. Cloatre G, Sane M, Wade B et al. Cardiac manifestations of polymyositis. Apropos of 2 Senegalese cases. *Rev Med Interne* 19: 265-70, 1998.
11. Soylu A, Kavukcu S, Turkmen M et al. Dermatomyositis with membranous nephropathy. *Turk J Pediatr* 43: 143-145, 2001.
12. Pasquali JL, Meyer P, Christmann D et al. Renal manifestations in dermatomyositis and polymyositis. *Ann Med Interne* 138: 109-113, 1987.
13. Kasteler JS, Callen JP. Low-dose methotrexate administered weekly is an effective corticosteroid-sparing agent for the treatment of the cutaneous manifestations of dermatomyositis. *Am Acad Dermatol* 36: 67-71, 1997.
14. Zipitis CS, Baildam EM, Ramanan AV. Treatment approaches to juvenile dermatomyositis. *Expert Opin Pharmacother* 5: 1509-15, 2004.
15. Al-Mayouf S, Al-Mazyed A, Bahabri S. Efficacy of early treatment of severe juvenile dermatomyositis with intravenous methylprednisolone and methotrexate. *Clin Rheumatol* 19: 138-141, 2000.