

## SHORT REPORT

### Gunshot Wounds and Late Infection

Orhan YILDIZ<sup>1</sup>, Emine ALP<sup>1</sup>, Serap ŞİMŞEK<sup>1</sup>, Ahmet SELÇUKLU<sup>2</sup>, Mehmet DOĞANAY<sup>2</sup>

<sup>1</sup>Department of Infectious Diseases, Faculty of Medicine, Erciyes University, Kayseri - Turkey

<sup>2</sup>Department of Neurosurgery, Faculty of Medicine, Erciyes University, Kayseri - Turkey

Received: September 17, 2004

**Key Words:** Foreign bodies, gunshot, wound, infection

Infection is a major complication in patients with incomplete removal of foreign bodies (1-3). Animal models have confirmed the high susceptibility of artificial implants to low inocula of staphylococci (3,4). *Staphylococcus aureus* (*S. aureus*) is the dominant pathogen in early-onset infections (2). This organism is often found as a part of the normal cutaneous flora and can be transmitted from the skin into traumatized bone or soft tissue during the trauma (2,5). Infection due to artificial implants or foreign bodies is the result of the reactivation of a small number of surviving bacteria or bacteraemia. In this report, we present a case of late infection which occurred almost seven years after the original injury.

#### Case Report

A 60-year-old man was admitted to hospital because of a nonhealing wound of the neck with a firm mass, fistula and purulent drainage. Seven years before this referral, he had had accidental multiple pellet injuries to the neck and right shoulder after being shot. Because the patient had not been admitted to hospital at that time, many pellets become lodged in the surrounding tissues, and the wound improved without surgical therapy. The patient had been well until three months earlier, when he had expressed a large amount of yellow pus from the neck, without antecedent trauma.

On admission, the temperature was 36.9 °C, heart rate was 92 beats/min, respiratory rate was 16 breaths/min, and blood pressure was 120/70 mm Hg. Physical examination was normal except for the presence of a firm, circular, slightly tender mass, 7.5 cm, on the neck; the mass was raised 5 to 6 cm above the skin surface (Figure 1). There were edema, fistula and purulent drainage and slight erythema on the skin. Radiographs of the neck showed that most of the pellets were embedded in the thick muscles along the neck. The bones and joints appeared normal (Figure 2). Laboratory tests showed the following values: hemoglobin, 13.4 mg/dL; WBCs, 5,400 cells/mm<sup>3</sup>; platelets, 340,000 cells/dL; erythrocyte sedimentation rate, 14 mm/h. All biochemistry tests were normal.

During the first day of hospitalisation, the patient underwent wound debridements, and as many pellets were removed as possible (Figure 3) and culture from biopsy samples of the lesion was taken. Gram-stained specimens of materials obtained during the surgical procedure showed gram-positive cocci. Ampicillin-sulbactam (1 g four times a day intravenously) was started. On the 2<sup>nd</sup> day, wound cultures yielded methicillin-susceptible *S. aureus* (MSSA), so an intravenous infusion of ampicillin-sulbactam was continued. The isolate was also susceptible to ampicillin-sulbactam, cephazolin trimethoprim-sulfamethoxazole, and chloramphenicol by standard disk diffusion technique.

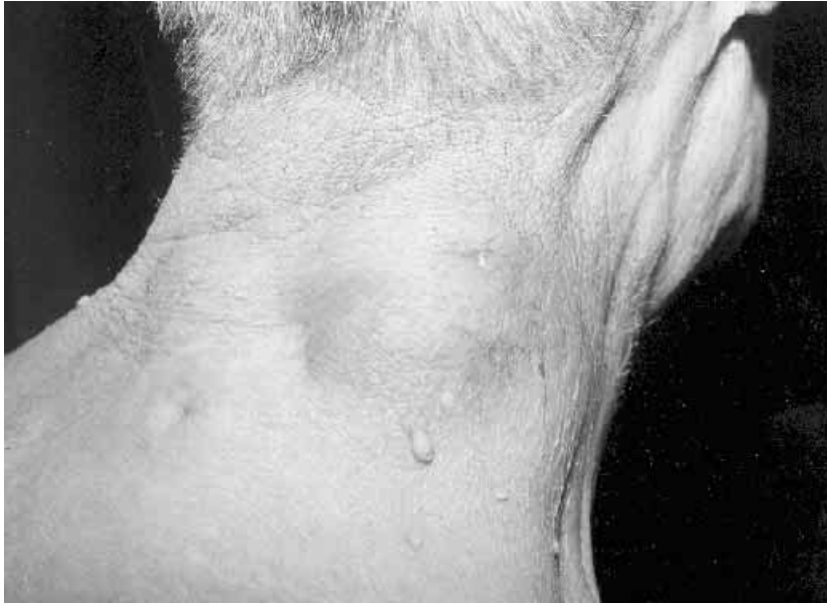

Figure 1. A firm, circular, slightly tender mass on the neck.

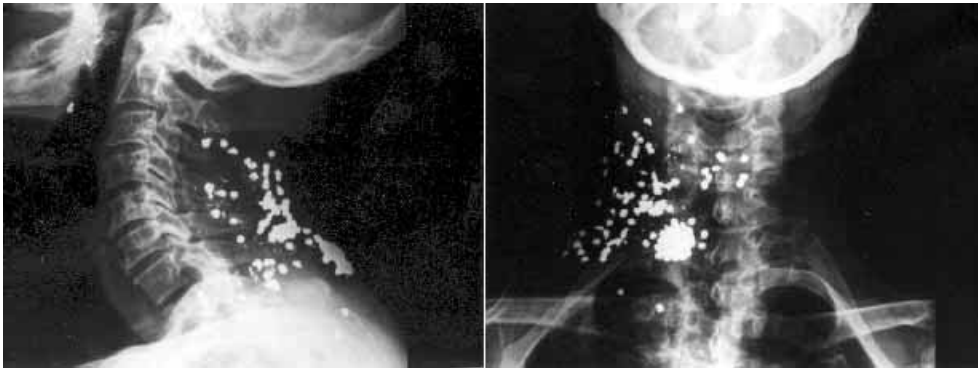


Figure 2. Shotgun pellets deep under the skin over the spine.

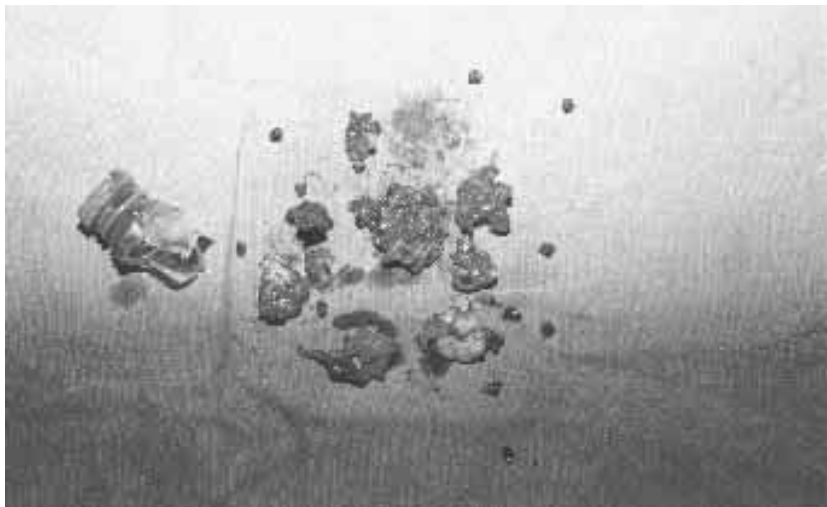

Figure 3. Debridement specimen from the neck.

Signs of inflammation on the skin and tissues improved substantially within the following 5 days. The patient was discharged on day 7, and instructed to take oral amoxicillin-clavulanate (3 g/d) for an additional 2 weeks. The patient was followed up for 5 months after the treatment. Healing occurred normally and no recurrence was observed.

Gunshot wounds, considered to be primarily contaminated, may promote infection through several mechanisms; penetration of soiled clothing into the skin and various tissues; introduction of debris and foreign material through the pulsation of the cavity into the wound canal; creation of nonviable tissue which enables the proliferation of microorganism; disruption of local blood supply and creation of shock with decreased host immunological defence (6,7).

We describe a case of late infection of the neck due to foreign bodies long after an injury by low-velocity gunshot. Late infection occurred almost seven years after the original injury, and the patient was otherwise asymptomatic, an extremely unusual presentation. The patient underwent wound debridements, as many pellets as possible removed and cultures from biopsy samples of the lesion were taken. Cultures from biopsy samples of the lesions revealed MSSA

Infections of prosthetic devices or foreign bodies may be acquired by three routes: haematogenously, direct inoculation or from an adjacent focus. The 'seeds of infection' will arise only at the time of surgery or penetrating trauma. *S. aureus* is generally the dominant pathogen in early-onset infections (2,9). It is carried in the anterior nares, skin folds and damaged skin surfaces but has considerable pathogenic potential. Other routes are bacterial seeding due to bacteraemia and transportation of bacteria through lymphatic vessels as in erysipelas (5,10). The period from inoculation of the foreign material to clinical manifestation of periprosthetic infection may last for years (11). These infections are also usually due to staphylococci (9,12).

Specifically, organic materials (e.g. wood, bone) are more likely fragments within the body and become superinfected due to their more porous nature than inorganic projectiles (e.g. glass, metal bullets). These fragments can later act as a nidus for early and late septic complications and standard antibiotic regimens are rarely able to cure these infections without removal of the foreign body (3,8).

Specific bacteria, such as staphylococci, are able to produce extracellular slime that allows bacteria to form in a primitive ecological system. This biofilm prevents sessile bacteria from being attacked from cellular host defense, which is able to eliminate bacteria from the host's inner environment the biofilm. Biofilm is usually formed on the surface of foreign bodies and bacteria are able to spread along the surface of artificial implants (4,5,13). This may last for an extended period until some of these bacteria leave the biofilm and switch over again to planktonic forms. Otherwise, a foreign body infection becomes established and may lead to life threatening infection, but most of them result in a low grade infection (3,5,14).

Several clinical and experimental studies have documented the frequent failure of antimicrobial agents to eradicate staphylococcal infections associated with the implanted foreign body (3,15,16). Once adhered to the foreign body or necrotic tissue, the microorganism changes its metabolism, becoming more resistant to antibiotics and to the host's defence. Decreased susceptibility to phagocytosis following bacterial attachment to foreign bodies and inadequate neutrophil response may act in concert to favor infection on foreign material (14). Such a hypothesis has yet to be confirmed by appropriate functional assays.

**Corresponding author:**

Orhan YILDIZ  
Department of Infectious Diseases,  
Faculty of Medicine, Erciyes University  
38039 Kayseri - Turkey  
E-mail: oyildiz@erciyes.edu.tr

## References

1. McNeill AM, Annett JL. The ongoing hazard of BB and pellet gun-related injuries in the United States. *Ann Emerg Med* 26:187-94, 1995.
2. Waldvogel FA. Staphylococcus aureus (including toxic shock syndrome). *Principles and Practice of Infectious Diseases* (Eds. Mandell GL, Bennett JE and Dolin R) Churchill Livingstone. New York 2000, pp: 2069-89.

3. Zimmerli W, Lew PD, Waldvogel FA. Pathogenesis of foreign body infection. Evidence for a local granulocyte defect. *J Clin Invest* 73:1191-200, 1984.
4. Passl R, Mueller C, Zielinski CC, et al. A model of experimental post-traumatic osteomyelitis in guinea pigs. *J Trauma* 24:323-6, 1984.
5. Vaudaux P, Francois P, Lew DP et al. Host factors predisposing to and influencing therapy of foreign body infections. *Infections Associated with Indwelling Medical Devices*. (Eds. Waldvogel FA and Bisno AL) American Society for Microbiology. Washington DC 2000, pp: 1-26.
6. Roth AI, Fry DE, Polk HC. Infectious morbidity in extremity fractures. *J Trauma* 26:757-61, 1986.
7. Ordog GJ, Balasubramaniam S, Wasserberger J. Outpatient management of 357 gunshot wounds to the chest. *J Trauma* 28:832-5, 1983.
8. Geissler WB, Teasedall RD, Tomasin JD, et al. Management of low velocity gunshot-induced fractures. *J Orthop Trauma* 4:39-41, 1990.
9. Elek SD, Conon PE. The virulence of *Staphylococcus pyogenes* for man: a study of the problem of wound infection. *Br J Exp Pathol* 38:573-86, 1957.
10. Bisno AL, Stevens DL. Streptococcal infections of skin and soft tissues. *N Engl J Med* 334:240-6, 1996.
11. Brand KG. Infection of mammary prostheses a survey and the question of prevention. *Ann Plast Surg* 30:289-95, 1993.
12. Kloster FE. Complications of artificial heart valves. *J Am Med Assoc* 241:2201-3, 1979.
13. Costerton JW, Lewandowski Z, Caldwell DE et al. Microbial biofilms. *Annu Rev Microbiol* 49:711-45, 1995.
14. Vaudaux PE, Zulian G, Huggler E et al. Attachment of *Staphylococcus aureus* to Polymethylmethacrylate Increases Its Resistance to Phagocytosis in Foreign Body Infection. *Infect Immun* 50:472-7, 1985.
15. Henry NK, Rouse MS, Whitesell AL et al. Treatment of methicillin-resistant *Staphylococcus aureus* experimental osteomyelitis with ciprofloxacin or vancomycin alone or in combination with rifampin. *Am J Med* 82:73-5, 1987.
16. Widmer AF, Frei R, Rajacic Z et al. Correlation between in vivo and in vitro efficacy of antimicrobial agents against foreign body infections. *Antimicrob Agents Chemother* 162:96-102, 1990.