

## SHORT REPORT

# Multiple Aneurysms of the Left External Jugular Vein

Sami KARAPOLAT, Bilgehan ERKUT, Yahya ÜNLÜ

Department of Cardiovascular Surgery, Faculty of Medicine, Atatürk University, Erzurum - Turkey

Received: November 19, 2004

**Key Words:** Multiple venous aneurysm, jugular vein, children

True venous aneurysms are rarely encountered local dilatations, in contrast to arterial aneurysms (1). Congenitally elastic layers and muscle cells are insufficient or even do not exist in vein walls and valves (2). Aneurysmal dilatations in cervical veins are rare due to low pressure in the vena cava system.

### Case Report

A 4-year-old male was admitted to the Department of Cardiovascular Surgery, Faculty of Medicine, Atatürk University. He had a progressive swelling in the left side of the neck. The swollen parts had developed in the past year and become larger when the patient cried. One of these was in the middle of the external jugular vein at the posterior of the left sternocleidomastoid muscle, while the other was in the submandibular part in the distal section of the vein. Physical examination revealed 2 soft, round, mobile, non-pulsating masses approximately 2 x 1 and 1 x 1 cm in diameters. There was no history of trauma. Results from the examination of the other systems were normal. Diagnosis was made using Doppler ultrasonography and magnetic resonance imaging. Venous magnetic resonance imaging of those regions revealed external jugular vein aneurysms (Figures 1,2). An operation was performed under general anesthesia in the supine position. The aneurysms were freed from the neighboring tissues by separation with 2 cervical incisions, and both aneurysmal dilatations were extracted

by binding from the proximal and distal. The postoperative course was uneventful. Histopathological examination revealed congestional vein structures with thinning in the elastic layer. The lesions were therefore evaluated as true venous aneurysms. The patient was discharged the day after surgery, and remained asymptomatic for the next 6 months.

Acquired aneurysms in the venous system develop with changes in the flow of blood and blood pressure. Etiologic factors are tumors, thoracic outlet syndromes and trauma. Inflammation has also been cited as a possible cause of venous aneurysms. True venous aneurysms are rarely observed localized dilatations with no observations of hemodynamic changes. Few cases of venous aneurysms involving the external jugular vein have been described in the literature (1-4).

We think that our case is interesting due to the fact that observations of true aneurysms in the venous system are rare.

Venous aneurysms are isolated fusiform or saccular dilatations that may occur at any age. Etiology is not clear in children. They are not related to either age or gender. They can affect any vein, and can present in any cervical vein. They are observed most frequently in the internal jugular and the external jugular vein (4). Varicose enlargement in the affected vein is not accompanied by stretching in the vein. Generally, there are no symptoms. The most important complications are pulmonary

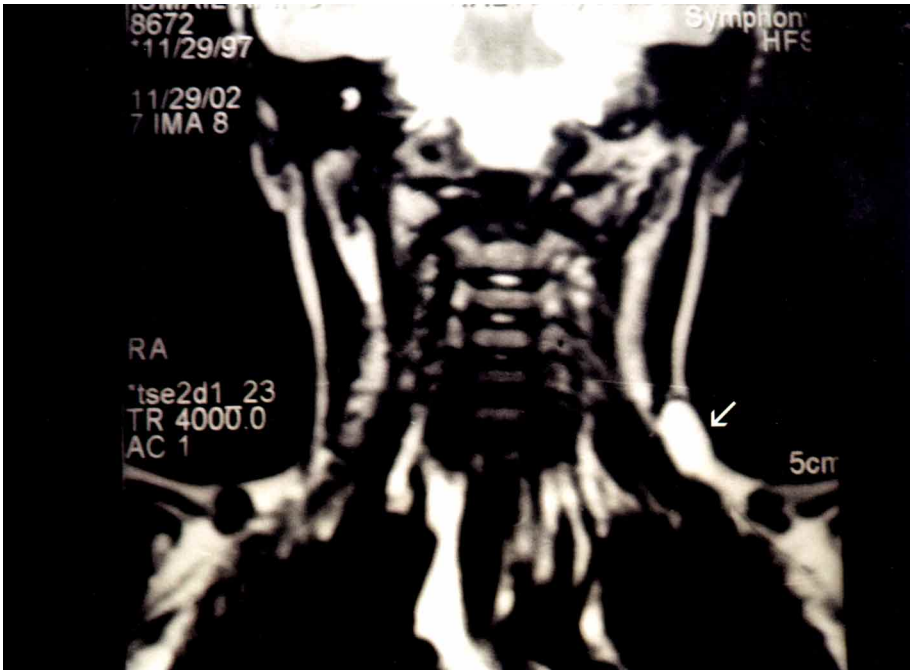

Figure 1. Venous magnetic resonance imaging showing the aneurysm proximal to the left external jugular vein.

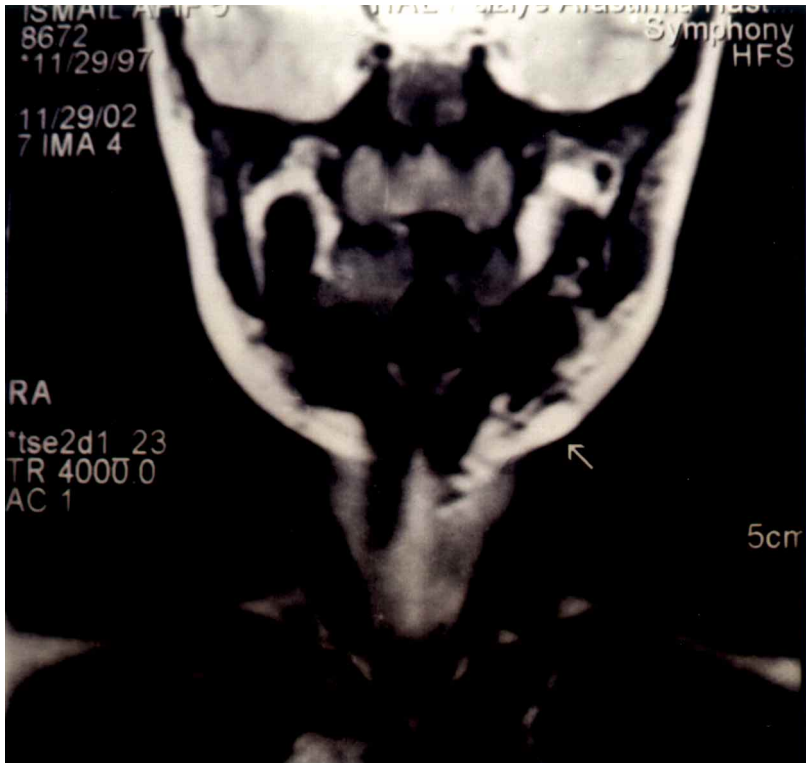


Figure 2. Venous magnetic resonance imaging showing the aneurysm distal to the left external jugular vein.

embolism, thrombophlebitis, rupture and thrombus formations, although these are quite rare. Jugular venous aneurysms may be easily confused with lymphocele, hygroma, hemangioma, laryngocele or some other tumors.

Venous doppler ultrasonography, computed tomography, magnetic resonance imaging and venography will assist in making a correct diagnosis, as in our case.

Thinning in the elastic and muscular layers in the venous aneurysm has been observed during pathologic investigation. Matsuura et al. (5) report that the thinning in the elastic layer is the most significant cause in terms of congenital fragility. Thinning in the elastic layers was also observed in our case.

In conclusion, known indications for surgery for this kind of venous aneurysm are progressive enlargement and cosmetic causes. Patients may experience symptoms such as tightness due to pressure, congested and choking feelings and pain, and because of the risk of thrombosis and subsequent pulmonary embolism, and the complication of rupture, we suggest that such venous aneurysms should be considered for surgery.

*Corresponding author:*

*Sami KARAPOLAT*

*Universite Loj, 12/7, 25240*

*Erzurum - Turkey*

*E -mail: samikarapolat@hotmail.com*

## References

1. Ekim H, Özen S. Primary venous aneurysm of the external jugular vein. *EJM* 7: 24-5, 2002.
2. Davis RK. Isolated aneurysm of internal jugular vein: a report of three cases. *J Pediatr Surg* 17: 130-1, 1982.
3. Regina G, Rizzo S, Impedova G. Aneurysm of external jugular vein: case report and review of literature -A case report. *Angiology* 108: 92-95, 1990.
4. Ceyran H, Akçalı Y, Oğuzkaya F et. al. Isolated jugular vein aneurysms. *Turk J Vasc Surg* 1: 32-5, 1999.
5. Matsuura Y, Higo M, Yamashina H et. al. A case report of venous aneurysm of the neck. *Jpn J Surg* 11: 39-42, 1981.