

Gülay YEGİNOĞLU¹
Osman AYNACI²
Ahmet Uğur TURHAN²

Intraarticular Cyst of the Knee

Department of ¹Anatomy, ²Orthopedic
Surgery, School of Medicine, Karadeniz
Technical University, 61080 Trabzon - Turkey

Received: February 02, 2001

Key Words: Cyst, Meniscus, Knee

The biomechanical examination of amputated knees from one hundred patients admitted to Farabi Hospital of Karadeniz Technical University between 1988 and 1997 reveal a rare case involving the location of a cyst. The formation of a cyst at the anterior horn of the lateral meniscus is very unusual, and was found to be a unique case in the literature. The formation of this intraarticularly located cyst may have some unexplained functional symptoms.

Case Report

Amputated extremities were collected for biomechanical study. A 70 year-old patient was admitted with the symptoms of peripheral arterial obstruction, and the Department of Orthopedic Surgery made a decision to amputate the left upper knee as the last resort. The tibia

and femur connections of this amputated knee joint were shortened to leave 10 cm. Later the joint capsule was dissected anteriorly and a 1.5 x 1.5 x 1 cm cyst was observed (Figure). The location of this cyst at the anterior horn of the lateral meniscus is very rare. The cyst was also located behind the intrapatellar fat globe. There were no lesions or tears in the lateral meniscus. Before the dissection of the joint, there was no apparent swelling indicating a cyst from the anterior position.

Generally, cysts of the meniscus are more commonly observed on the lateral side. Cysts of the meniscus usually appear with lateral or medial swelling of the joint. In addition, cysts of the meniscus must be clinically differentiated from lipomas, bursitis, exostosis and ganglion of the proximal tibio-fibular joint (2,4). Cyst of the lateral meniscus is frequently observed in the middle

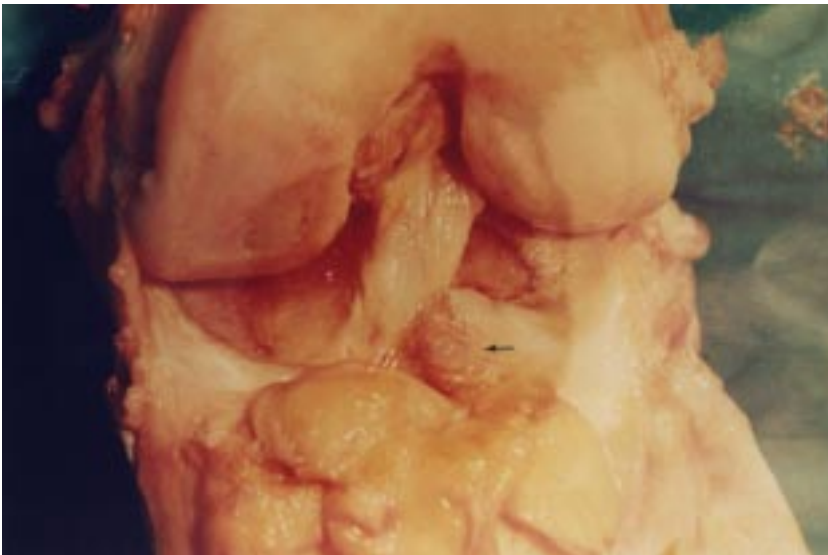


Figure. Intraarticular cyst located at the anterior horn of the lateral meniscus.

portion of the meniscus (3). Two intraarticular cysts of the lateral meniscus have been reported in the literature (2). In our case, the cyst was located on the anterior horn of the lateral meniscus that was grossly intact. This type of intraarticular cyst may cause pain and locking in the joint. It can be only treated by arthroscopic resection (1).

Correspondence author:

Gülay YEGİNOĞLU

Karadeniz Technical University

School of Medicine

Department of Anatomy

61080 Trabzon- TURKEY

References

1. Parisien S.J.: Arthroscopic treatment of cysts of the menisci. *Clinical Orthopedics*. 257: 154-58, 1990.
2. Passler J, Hofer HP, Fellingner M, Peicha G.: Intraarticular cyst of the knee. *International Orthopaedics*. 15: 357-58, 1991.
3. Tasker A.D, Ostlere S.: Relative incidence and morphology of lateral and medial cysts detected by magnetic resonance imaging. *Clinical Radiol*. 50 (11): 778-81, 1995.
4. Vergis A, Maletius W, Inessner K.: An unusual case of vascular abnormality mimicking a lateral meniscal cyst. *Arthroscopy*. 11 (5): 616-19, 1995.