

Gaye ÜNAL¹
Sibel GÜNDEŞ²
Melek ÜSTÜN³

Human Orf: Ecthyma Contagiosum Report of Five Cases

Departments of ¹Dermatology, ²Clinical
Bacteriology and Infectious Diseases,
³Pathology, Faculty of Medicine, Kocaeli
University, Kocaeli, Turkey

Received: April 04, 2001

Key Words: human orf, ecthyma contagiosum

Contagious ecthyma, contagious pustular dermatitis, or human orf, is a disease that is caused by the orf virus. The orf virus is an epitheliotropic DNA parapoxvirus with worldwide distribution that induces acute pustular lesions in the skin of sheep and goats, and can be transmitted to humans. Although the disease is classified as a near-neoplasm (1), the lesion is generally a benign, self-limited condition (2,3). Early clinical recognition is paramount; diagnosis is established by a history of contact with infected animals, the appearance of the lesions, viral cultures, fluorescent antibody tests, and electron microscopy. There is no specific treatment in immunocompetent patients. Compresses, culture and sensitivity testing, with appropriate antibiotics, are of value for secondary bacterial infection. Lesions heal within 2 to 3 weeks. Immunocompromised patients, however, can develop very large and atypical orf lesions, and multiple treatments, such as cryotherapy and 40% topical idoxudiridine application have been successfully used in such cases (5). No underlying disease has been found as a predisposition and the prognosis is excellent.

Case Reports

We report five cases of ecthyma contagiosum with six lesions. Although it is seldom reported in Turkey, we thought that many cases remain underestimated or misdiagnosed. Four of our patients had their only lesion on one finger (Figures 1,2), whereas one patient had an extra lesion on his naso-labial sulcus (Figure 3). Only one patient was a farmer living in a rural community, the others were living in urban areas. All of the patients

presented a 10-14-day history, following contact with an animal during the holiday of the Feast of Sacrifice. There was regional lymphadenopathy in two of the cases. Prodromal symptoms, such as malaise, night sweats and fever, were unremarkable. The lesion is most commonly located on the dorsal aspect of the right index finger and gradually developed after a knife wound caused accidentally while cutting mutton. They were 1 to 3 cm in diameter, and typically started as an painless itchy macule that became papular and subsequently purulent with a necrotic center. Bacteriological smears were negative. Biopsy results showed epidermal ulceration, and dense dermal inflammation with intranuclear, intracytoplasmic inclusions in the vacuolated epidermal cells (Figures 4,5). There was an infiltrate of plasma cells, macrophages, histiocytes, and lymphocytes. Microvesicles were present. The histologic examination indicated a diagnosis of orf lesion. Topical treatment with fucidic acid cream (twice a day) for a week was successful in inhibiting secondary infections. Complete regression was achieved in all of the cases without residual scarring.

Orf is endemic in sheep and goats, mainly affecting young lambs. It can occasionally be transmitted to man by inoculation from infected animals. It can be considered to be an occupational disease in farmers, shepherds, veterinarians and butchers. In Islamic countries, such as Turkey, diagnosis of human orf can be problematic, because of high endemicity of other zoonoses like anthrax. Following the religious holidays of the Feast of Sacrifice, cases reported as anthrax increase as well as those of human orf. Therefore, to be familiar with both

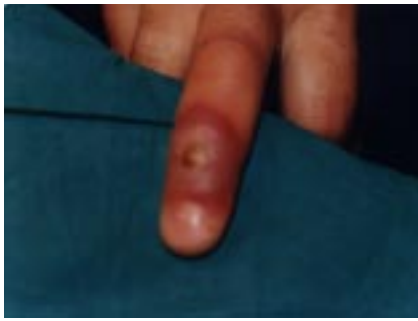

Figure 1. An orf lesion on the finger.

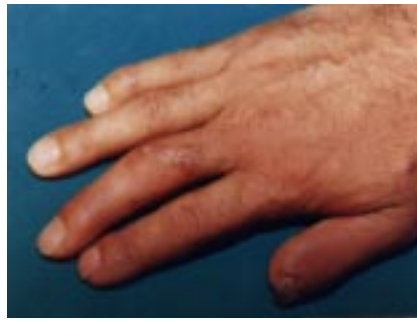

Figure 2. Another healed orf lesion on the finger.

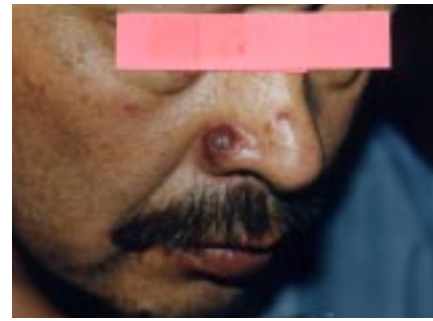

Figure 3. A patient had second lesion on his naso-labial sulcus.

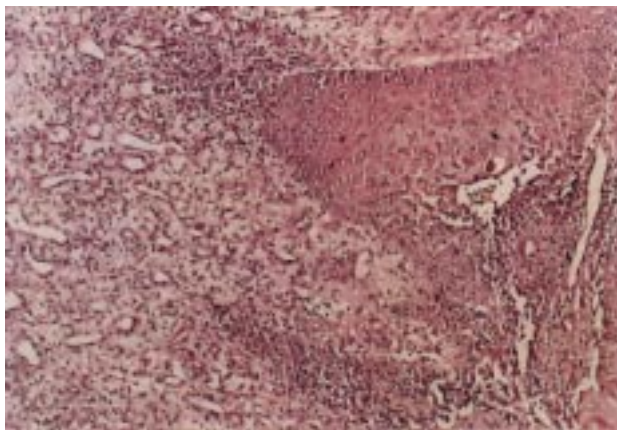


Figure 4. Scale crust and hyperkeratosis overlying markedly hyperplastic epidermis (HEX10).

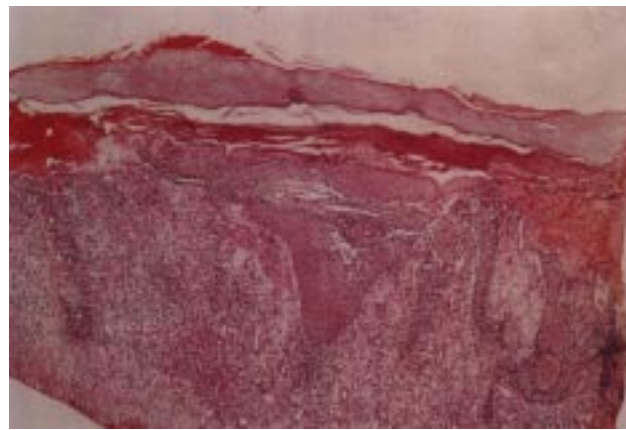


Figure 5. Capillary vessel proliferation mixed with chronic inflammatory infiltration in the dermis and intracytoplasmic inclusions in keratinocytes (HEX20).

of these diseases is important in order to be successful in differential diagnoses.

We report five cases of human orf, observed as a sporadic type of the disease over two years in our region. Four of the patients were amateur butchers, who had direct contact with the contaminated animals, and one was a farmer. The mean incubation time was two weeks, which is acceptable for human orf. Spontaneous resolution occurs within 4 to 6 weeks after the onset in all of the cases. Characteristic painless lesions developed on the fingers in all patients; one patient had a second lesion on his naso-labial sulcus. Orf in humans usually appears as a solitary papule on a finger or hand, although facial lesions have occasionally been reported (3). Lesions typically started as an itchy macule that became papulo-nodular with a necrotic center. Surrounding erythema was usually present. This is one of the reasons for the misdiagnosis of human orf as pyogenic granuloma. Since aspiration of the pustular lesions was difficult,

bacteriological tests were performed with cotton swabs. The following clinical diagnosis and histopathological examination indicated this diagnosis. Orf is a benign self-limited viral infection that warrants no specific treatment. Oral antibiotics should be reserved only for documented secondary bacterial infections. All of the our patients healed with no residual scarring. No significant systemic symptoms occurred and all of the microbiological and biochemical test results were negative. Diagnosis of orf is usually established by clinical examination and a history of contact with infected animals. It is confirmed by light or electron microscopy of the biopsy specimen (4). Other tests, such as complement fixation, neutralizing, and agglutinating antibodies, have been described but are of more epidemiologic than diagnostic significance (6). Orf produces a distinctive histology characterized by pallor and vacuolization of the cells in the upper one third of the epidermis, and eosinophilic intracytoplasmic inclusions in the vacuolated

epidermal cells (6). Complications associated with orf are not common, but can include fever, chills, lymphangitis, lymphadenopathy, and secondary bacterial infections (3,7,8). Erythema multiforme and an unusual vesicular exanthem have been reported (3). There were no complications in our patients.

In conclusion, human orf infections do occur in Turkey, although are seldom reported. They should be considered in the diagnosis of cutaneous lesions in

patients who have exposure to animals, such as sheep, that may be infected with the virus.

Correspondence author:

Gaye ÜNAL

Department of Dermatology,

Faculty of Medicine, Kocaeli University,

Kocaeli - TURKEY

References

1. Fraser KM, et al. Sequence analysis of the inverted terminal repetitions in the genome of the parapox virus, orf virus. *Virology* 176: 379-383, 1990.
2. Paiba GA et al. Orf (contagious pustular dermatitis) in farm workers: prevalence and risk factor in three areas of England. *Vet Res* (1): 7-11, 1999.
3. Gill MJ, Arlette J, Buchan KA, Barber K. Human orf? A diagnostic consideration. *Arch Dermatol* 126: 356-358, 1990.
4. Degraeve A, De Coninck A, Senneseael J, Roseeuw D. Recurrent Contagious Ecthyma (Orf) in an immunocompromised host successfully treated with cryotherapy. *Dermatology* 198: 162-163, 1999.
5. Bodnar MG, Miller OF, Tyler W: Facial Orf *J Am Acad Dermatol* 40: 815-7, 1999.
6. Gunes AT, Gezen C, Kapdaghi H, Marshall HJ: Ecthyma contagiosum epidemics in Turkey. *Hautartz* 33 (7): 384-387, 1982.