

Sema HÜCÜMENOĞLU¹
Nur ÇELİK¹
Gülben ERDEM¹
Sinan KOCATÜRK²

Papillary Adenocarcinoma of the Epiglottis

Departments of ¹Pathology,
²Otorhinolaryngology, SSK Training and
Research Hospital, Ankara, Turkey

Received: June 08, 2001

Key Words: adenocarcinoma, larynx

Most nonepidermoid laryngeal carcinomas are either adenocarcinomas, adenoid cystic carcinomas or mucoepidermoid carcinomas (1). The nonspecific adenocarcinomas represent 0.35% to 0.5% of laryngeal malignant tumors (1). Although adenocarcinoma of the larynx is an aggressive neoplasm that tends to spread to both regional lymph nodes and distant sites, papillary adenocarcinoma is relatively slow growing and non-aggressive (2). Primary papillary adenocarcinoma of the larynx is a rare tumor and primary involvement of the epiglottis with this tumor has been documented in very few cases. We studied an additional case of papillary adenocarcinoma arising on the laryngeal surface of the epiglottis.

Case report

A 53-year-old man was admitted to our hospital because of hoarseness and a lump in the neck of 6 months' duration. There was history of smoking but not of alcohol use. Suspension laryngoscopy disclosed an ulcerated fungating mass 20 mm in diameter, on the left portion of the laryngeal surface of the epiglottis. On physical examination, an enlarged node 20x20 mm in diameter was palpated in the neck. Biopsy of the lesion revealed a malign epithelial tumor. Laboratory investigations were normal except the positivity of hepatitis B surface Ag. Following tracheotomy under general anesthesia, a modified horizontal supraglottic laryngectomy was performed, including the upper portion of the thyroid cartilage. The margins of the resection appeared to be free of tumor. The histologic

diagnosis was moderately differentiated adenocarcinoma. Metastasis was detected in four lymph nodes belonging to the left neck dissection. The possibility of a tumoral origin from any viscera was not suggested, since abdominal ultrasonography, thyroid, bone, kidneys, liver/spleen and other abdominal viscera scans yielded no evidence of any tumoral origin.

The postoperative course was uneventful. After 3 months of follow up, the patient was well.

Pathologic findings

On gross examination, there was a polypoid tumoral mass 2x2 cm in diameter on the left part of the epiglottis (Figure 1). Histologic examination revealed an infiltrating adenocarcinoma often forming papillary fronds, covered by multiple layers of epithelial cells supported by a fibrovascular stalk (Figure 2). The epithelial cells were

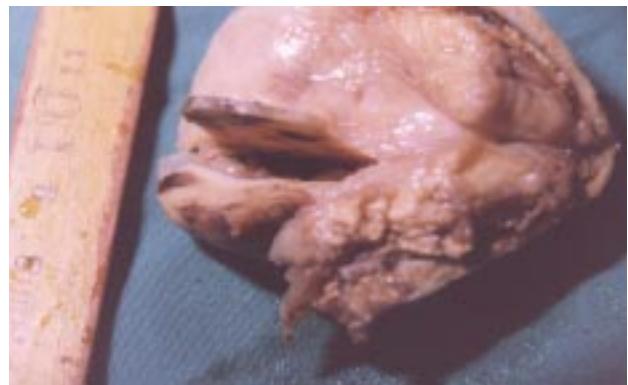


Figure 1. Macroscopic photograph showing the polypoid tumoral mass on the laryngeal surface of the epiglottis.

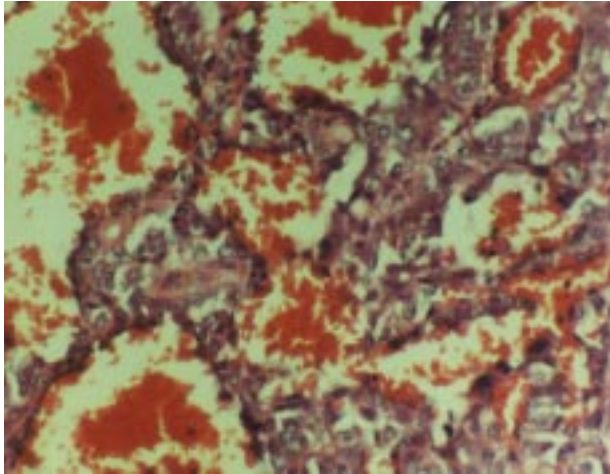


Figure 2. The tumor has a papillary configuration; the epithelial cells display nuclear pleomorphism and prominent nucleoli (Hematoxylin-eosin x400).

closely packed, with irregular round to oval nuclei and moderately abundant cytoplasm. Nucleoli were prominent, and mitoses were evident. Non-neoplastic mucosal glandular structures showed moderate dysplasia. Periodic acid-Schiff, alcian blue and Fontana stains disclosed no abnormality. Immunohistochemical studies revealed negative immunoreactivity to NSE, S-100, HMB45, vimentin and chromogranin; low molecular weight cytokeratin was strongly positive and carcinoembryonic antigen (CEA) was moderately positive (Figures 3,4)

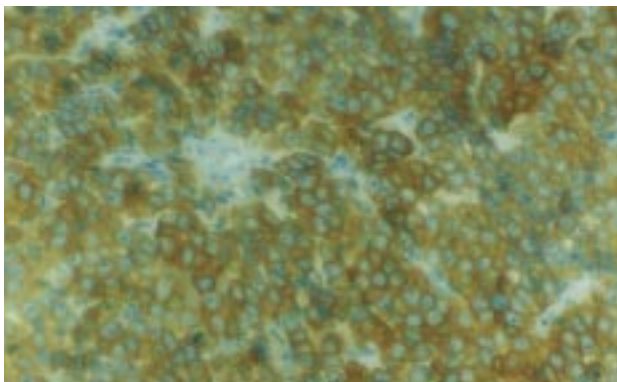


Figure 3. Photomicrograph of strongly positive immunoreactivity to low molecular weight cytokeratin in tumoral cells (Immunoperoxidase x400).

Glandular carcinomas of the larynx are rare tumors that constitute less than 1% of all laryngeal malignancies. The distribution of mucous glands in the larynx has been described in the literature (1,3-6). The true vocal cords

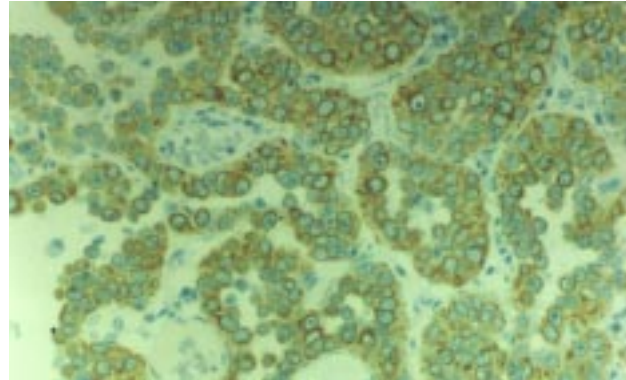


Figure 4. Immunohistochemical CEA positivity is seen in the tumoral cells covering the papillary fronds (Immunoperoxidase x400).

are thought to have no glands, while the greatest concentration of these glands is found on the false cords and the subglottic surface of the anterior commissure. The free portion of the epiglottis contains few glands mainly on the lingual surface (3,7). A review of the reports on mucous gland tumors of the larynx shows that the relative incidence of these tumors in different laryngeal sites correlates with the distribution of the mucous glands (1). New and Erich were probably the first to describe six patients with adenocarcinoma of the larynx among 1300 cases of laryngeal cancers (8). Cady et al. report, in their series from Memorial Hospital, that of the 2500 primary laryngeal cancers, 31 (1%) were nonepidermoid and the majority of these were adenocarcinomas (9). The adenocarcinomas were further subdivided into adenocarcinoma, adenoid cystic carcinoma, and mucoepidermoid carcinoma (2). Glandular neoplasms of the larynx may rarely represent metastatic foci from a distant site. During the histological examination, significant dysplasia or carcinoma in situ in laryngeal glandular structures is an important finding in the differential diagnosis of primary adenocarcinoma from a metastatic tumor.

Papillary adenocarcinoma of the larynx has been described once previously by Mertens et al. (10). Their patient was found to have papillary adenocarcinoma of the vocal cord. Roa et al. reported the second case of papillary adenocarcinoma of the vocal cord (2). Gadowsky et al. reviewed 1135 laryngeal cancers over a 24-year period and found a 1.7% incidence of nonepidermoid cancer, with no cases of papillary adenocarcinoma (11).

Since the glandular neoplasms of the larynx are rare, they can present a challenge in management to the otolaryngologist. Papillary adenocarcinoma is amenable to conservative surgical methods (2). In cases of regional lymph node involvement, as in our case, a radical neck dissection completes total or partial laryngectomy (11). Haberman reported a case of adenocarcinoma (not otherwise specified), treated with carbon dioxide laser excision and postoperative radiotherapy (12). Alavi

claimed that the 5-year survival rate was 57% in patients who underwent combination therapy versus 50% for those patients who received surgery alone in his study composed of 12 patients with glandular carcinomas (13).

Correspondence author:

Sema HÜCÜMENOĞLU

Hoşdere C. No: 164/3 Y. Ayrancı, Ankara - TURKEY

References

1. Bloom J, Behar A, Zik D, Shanon E. Adenocarcinoma of the epiglottis. Arch Otolaryngol Head Neck Surg 113: 1330-33, 1987.
2. Roa A, Atkins J, Cunnane M, Keane W. Papillary adenocarcinoma of the larynx: a case report. Otolaryngology Head and Neck Surg 99: 601-3, 1988.
3. Batsakis JG, Rice DH, Salomon AR. The pathology of head and neck tumors: squamous and mucous gland carcinomas of the nasal cavity, paranasal sinuses and larynx. Head and Neck Surg 2:497-508, 1980.
4. Toomey JM. Adenocarcinoma of the larynx. Laryngoscope 77: 931-961, 1967.
5. Ferlito A. Histological classifications of the larynx and hypopharynx cancers and their clinical implications. Acta Otolaryngol Suppl 342: 1-88, 1976.
6. Lawson W, Biller HF. Cancer of the larynx, in Suen JH, Myers EN (eds): Cancer of Head and Neck. New York, Churchill Livingstone Inc, pp 466-67, 1981.
7. Nassar VH, Bridger GP. Topography of the laryngeal mucous glands. Arch Otolaryngol Head Neck Surg 94: 490-98, 1971.
8. New GB, Erich JB. Adenocarcinoma of the larynx. Ann Otol Rhinol Laryngol 50: 706-14, 1941.
9. Cady B, Rippey JH, Frazell EL. Nonepidermoid cancer of the larynx. Ann Surg 167: 116-20, 1968.
10. Mertens J, Greisser GH, Kaiserling E, Rudert H. Papillary adenocarcinoma of the vocal cord: the first case in the literature. HNO 34: 81-4, 1986.
11. Gadomsky SP, Zwillenberg D, Choi HY. Nonepidermoid carcinoma of the larynx: the Thomas Jefferson University experience. Otolaryngol Head and Neck Surg 95: 558-65, 1986.
12. Haberman PJ, Haberman RS 2nd. Laryngeal adenocarcinoma, not otherwise specified, treated with carbon dioxide laser excision and postoperative radiotherapy. Ann Oto Rhinol Laryngol 101 (11): 920-4, 1992.
13. Alavi S, Namazie A, Calcaterra TC, Blackwell KE. Glandular carcinoma of the larynx: the UCLA experience. Ann Oto Rhino Laryngol 108 (5): 485-9, 1999.