

Ahmet ÖZYAZICIOĞLU  
Ahmet Yavuz BALCI

## Pneumopericardium Associated with a Steady Cough

Department of Cardiovascular Surgery, Faculty of Medicine, Atatürk University, Erzurum, Turkey

Received: December 24, 2001

**Key Words:** Pneumopericardium, barotrauma, open heart surgery

Air within the pericardial sac is an unusual finding and its mechanism remains elusive. Pneumopericardium may occur in patients with barotrauma secondary to a blast or valsalva maneuver. These patients need to be observed closely because of cardiac tamponade. Due to the possible asymptomatic presentation, a serial chest radiograph should be performed. Spontaneous resolution of pneumopericardium is possible.

### Case Report

A 40-year-old female patient was admitted to the hospital for double valve replacement (mitral, aorta). The mediastinal cavity was opened by median sternotomy. However, the bilateral thoracic cavity was not opened. She underwent surgery by means of cardiopulmonary bypass and cold potassium cardioplegic arrest. Aortic and mitral valves were replaced. On the first postoperative day, she was extubated and placed on a conventional face mask for oxygenation. The patient showed an uneventful recovery in the early postoperative period. As she had had significant elevation of pulmonary vascular resistance, she took oxygen with the face mask intermittantly. On the 4th postoperative day, both of the drainage tubes were removed, and the chest film showed a normal cardiac silhouette. Then the patient was treated with an angiotensin- converting enzyme inhibitor (ACEI) (Enalapril 5 mg/day). On the 7th postoperative day, the routine chest X-ray revealed that there were two obvious radiolucent areas along both heart borders with intrapericardial fluid, suggesting pneumopericardium. The chest radiograph also showed a thin radiolucent area outlining the right mediastinum, suggesting possible pneumomediastinum (Fig. 1). Computerized tomography showed bilateral airspace consolidation and

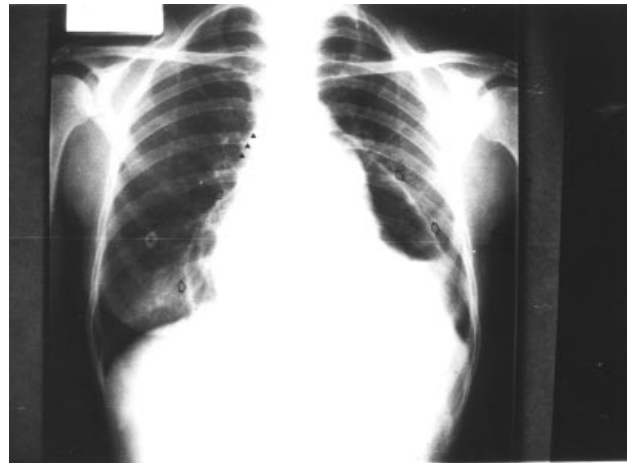


Figure 1. The chest X-ray revealed that there were two obvious radiolucent areas along both heart borders with intrapericardial fluids, suggesting pneumopericardium (open arrows). It also showed a thin radiolucent area outlining the right mediastinum, suggesting possible pneumomediastinum (arrow heads).

pneumopericardium but no pneumothorax (Fig. 2). She was asymptomatic, but coughing. She did not have a fever but had a pericardial friction rub. The ECG showed minimal diffuse ST-segment elevations. To detect the progressive accumulation of air around the heart (cardiac tamponade), subsequent chest X-ray and echocardiography were performed. The ACEI was discontinued. Serial chest radiographs over the following 10-day period showed the resolution of both the pneumopericardium-pneumomediastinum and the pericardial fluid.

Air within the pericardial sac is an unusual finding and its mechanism remains elusive (1-2). Pneumomediastinum and subcutaneous emphysema may be caused by the same mechanism. However,

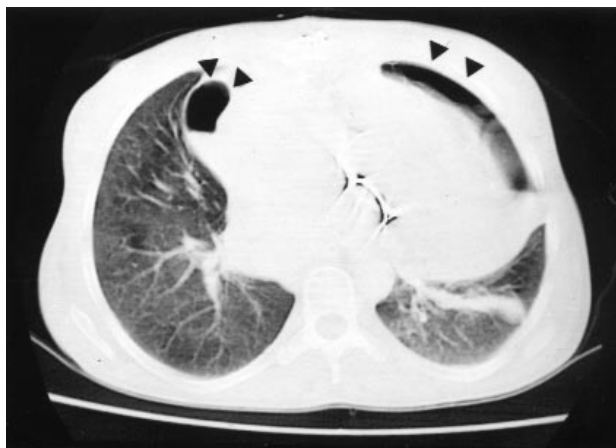

Figure 2. Computerized tomography showed bilateral airspace consolidation and pneumopericardium but no pneumothorax (arrow heads).

pneumopericardium is much less common than either pneumothorax or pneumomediastinum. Spontaneous development of pneumopericardium is extremely rare. In this form, alveolar rupture releases air that courses along the bronchi into the tissue planes leading into the pericardium (3). Frequently, an associated pneumothorax is identified. Generally, for pneumopericardium, a ruptured bulla attached to the mediastinal pleura is the usual explanation. A possible explanation in our case is that the mediastinal pleura and the lung might have been punctured during the insertion of wires to close the sternotomy incision. However, since the pneumopericardium appeared several days after surgery, this explanation is very unlikely. Open heart surgery may lead to the entry of air into the pericardial sac during inspiration. Our patient did not have sternal dehiscence, but the alteration of the normal mediastinal and pericardial structures during open heart surgery may have allowed air to enter directly into the pericardium from the mediastinum (4). If it had been so, the pneumopericardium would have occurred earlier or the air leak would have been bubbled in the drainage reservoir when the drains were in situ. Once air was in the mediastinum, in this case its movement in the pericardium would be difficult too. Pneumomediastinum may occur without subcutaneous emphysema or pneumothorax in patients with barotrauma secondary to a blast or valsalva maneuver (5). It implies a loss of pericardial integrity (2). It is possible that our patient developed alveolar disruption from severe acute lung injury because of a steady cough, and noninvasive

continuous high inspired oxygen contributed to increasing the pressure gradient between alveoli and the bronchovascular sheath leading to pneumopericardium. In our patient, when the inspired oxygen and ACEI were discontinued, pneumopericardium resolved completely.

Radiographically, pneumomediastinum and pneumopericardium are frequently confused since they can occur concomitantly (6). However, a chest radiograph can help in differentiating pneumopericardium from pneumomediastinum. In the pneumopericardium, a radiolucent halo of air partially or completely surrounds the heart but does not extend superiorly to the attachment of the pericardium. In our case, the chest radiograph showed a radiolucent area along the lateral borders of the heart, suggesting pneumopericardium. The chest radiograph also showed a thin radiolucent area outlining the right mediastinum, suggesting possible pneumomediastinum (Fig. 1).

In general, pneumopericardium causes few clinical effects. Cardiac tamponade may result from the progressive accumulation of air around the heart (3,7). Additionally, the presence of bacterial organisms may indicate infection.

Treatment of pneumopericardium is directed primarily toward its complications, most specifically the development of cardiac decompensation. Surgical intervention, catheter or needle drainage of the pericardial space are appropriate methods. These patients need to be observed closely because of cardiac tamponade. In our patient, the pneumopericardium resolved spontaneously after the discontinuation of high inspired oxygen and coughing due to ACEI. In this patient, if infection had been present, appropriate systemic antibiotics should have been administered in concert with pericardial drainage.

We agree that pneumopericardium is not an absolute indication of invasive intervention. Because of the possible asymptomatic presentation, a serial chest radiograph and hemodynamic monitoring should enable the physician to make an early diagnosis and to begin treatment as soon as possible.

**Correspondence authors:**

Ahmet ÖZYAZICIOĞLU  
 Atatürk University, Faculty of Medicine,  
 Department of Cardiovascular Surgery  
 Erzurum - TURKEY

## References

1. Carlos A, Albrecht CA, Jafri A, Linville L, Anderson HV. Images in cardiovascular medicine: Cocaine-induced pneumopericardium. *Circulation*; 102: 2792-93, 2000.
2. Mattox KL, Wall M. Thoracic trauma. Glenn's Thoracic and Cardiovascular Surgery (Ed. Baue AE) Prentice Hall International Inc. London 1996, pp: 91-115.
3. Douglas JM: The Pericardium. Surgery of the Chest (Eds. Sabiston DC, Jr Frank C) W.B. Saunders Company. Philadelphia. 1995, pp: 1365-86.
4. McEachern RC, Patel RG. Pneumopericardium associated with face-mask continuous positive airway pressure. *Chest*; 112: 1441-43, 1997.
5. Chitre W, Prinsley PR, Hashmi SMH. Pneumopericardium: An unusual manifestation of blunt tracheal trauma. *J Laryngol Otol*; 111: 387-388, 1997.
6. Semenkovich J, Freundlich IM. Abnormal thoracic air. A radiologic approach to diseases of the chest (Ed. Freudlich IM) Williams & Wilkins. Baltimore. 1992, pp: 186-98.
7. Hurd TE, Novak R, Gallagher J. Tension pneumopericardium: a complication of mechanical ventilation. *Crit Care Med*; 12: 200-01, 1984.