

Ramazan KÖYMEN  
Kerim ORTAKOĞLU  
Kemal Murat OKÇU  
Hasan Ayberk ALTUĞ  
Yavuz Sinan AYDINTUĞ

## Wound Closure By Skin Traction

Department of Oral and Maxillofacial Surgery,  
Gülhane Military Medical Academy, Dental  
Sciences Center, Etlik, Ankara, Turkey

Received: June 05, 2001

**Key Words:** Soft tissue, traction, skin, wound healing.

Large soft tissue defects due to odontogenic infection, high velocity missile injuries, tumoral lesions, burns and osteotomies cause psychological and physical handicaps (1-5). Reconstruction of soft tissue defects is usually achieved with skin flaps or grafts from the other parts of the body. This classical method of reconstruction can lead to secondary complications, such as serious contraction at the donor site (6,7). Recently a new method called wound closure by skin traction has been introduced with a satisfactory success rate and few complications. In this report, we present a case of soft tissue loss due to odontogenic infection that we treated with a surgical procedure of wound closure by skin traction (3-5,8).

### Case Report

A 42-year-old female patient presented with a swelling located on the right mandibular region at Gülhane Military Medical Academy, Department of Oral and Maxillofacial Surgery. Physical examination revealed a subcutaneous infection and 3x5 cm necrosis in the right submandibular area due to the infectious process (Figure 1a). Radiologically, in the first mandibular right molar periapical region, there was a radioluscent appearance (Figure 1b). Necrotic tissues were removed and the area was irrigated with antiseptic solution.

After the extraction of the first mandibular right molar tooth, infectious tissues were curated and repair was delayed a few days until the tissues looked healthy. A 2 mm Kirschner wire was inserted into the skin about 1 cm from the edge of the laceration and passed along the length of the wound. A similar wire was then introduced

on the contralateral side of the wound and stainless steel wires (0.5 mm) were passed beneath the skin just beyond the Kirschner wires using a 23-gauge needle. Finally the needle was inserted on the contralateral side of the wound and the ends of the wires were passed through the skin (Figure 1c). The ends of the wires were twisted simultaneously, bringing the ends of the wound closer together. Daily tightening was continued approximating the edges 2-3 mm per day until they were brought into contact. Then the edges were freshened by trimming and the skin was sutured using 3.0-black silk (Figure 2a). The Kirschner wires and sutures were left for one week and at the end of this period the sutures and the stainless steel wires were removed. For maintaining the distance between the wound edges, the Kirschner wires were tied with 0 black silk sutures (Figure 2b). Approximately six days after this procedure, the Kirschner wires and 0 black silk suture were removed. Subsequent visits brought about a good cosmetic outcome without any complications (Figure 2c).

If the specific treatment is not performed for odontogenic infections that occur intraorally, submucosal or subcutaneous abscesses may develop after bone destruction. If the treatment is neglected, the mucosa or skin will be thinner and, after the development of fistula, the abscess will drain and necrotic regions will occur. In addition, if the focus is not removed, chronic abscesses will recur. If the abscess is treated by means of drainage and removal of the focus at the proper time, a wide surgical intervention that may leave a scar will not be required.

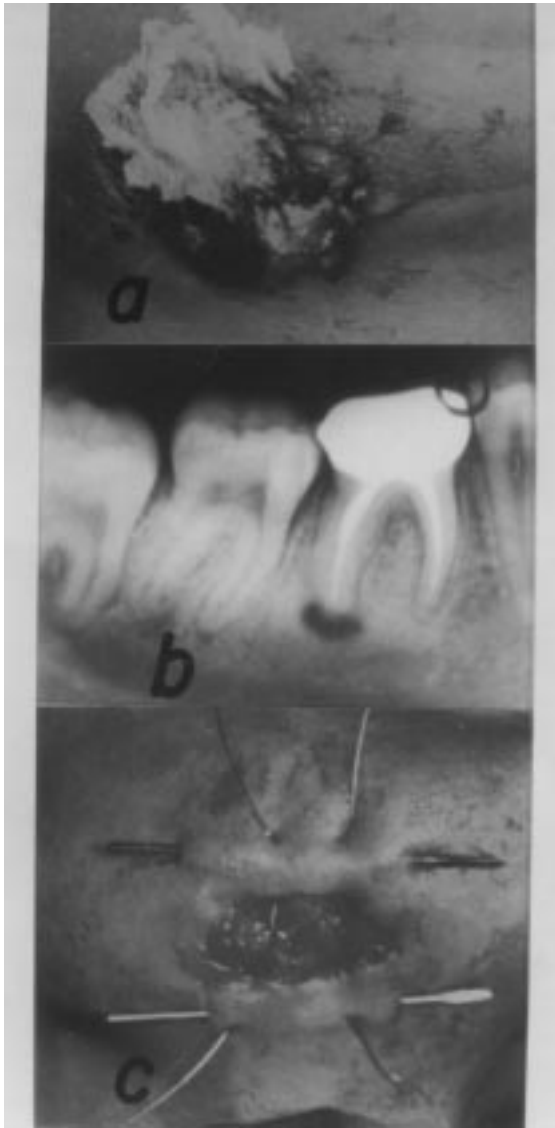


Figure 1. (a) Preoperative view of the wound, (b) Periapical view of the odontogenic lesion, (c) Introducing the Kirschner wires on the contralateral side of the wound and stainless steel passed beneath the skin just beyond the Kirschner wires.

Esthetic demands make the reconstruction of facial tissue in facial fistulas caused by odontogenic infection essential. Reconstruction of any lost tissue in the face can be achieved using distant flaps. It is difficult to restore full function, sensation, expression, and color. In the male, hair bearing distant flaps do not esthetically match the region's color, while a forehead flap leaves a defect at the donor site. In addition, distant flaps shrink and curl inward owing to lack of muscle function (9). The local tissue traction technique preserves sensibility and

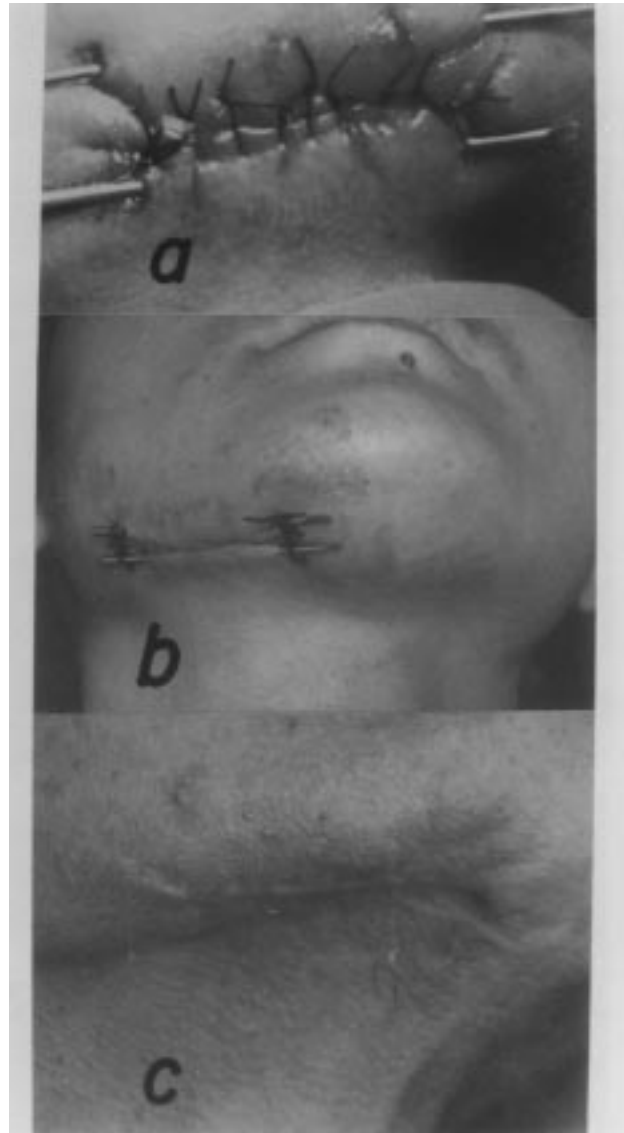


Figure 2. (a) The contact of the wound edges, (b) For maintaining the distance between wound edges the Kirschner wires were tied with 0 black silk sutures, (c) Postoperative view of the wound after 6 months.

function. Moreover, the remaining muscle tissue is helpful in functional rehabilitation (3).

Tissue traction as a means of tissue expansion is based on the findings of Gibson (9), who described the visco-elastic properties of vital skin in 1977. There are two such properties: creep and stress relaxation. Creep occurs when a piece of skin is stretched and when the stretching force is kept constant. The skin will continue to expand depending on the forces involved. Stress relaxation, the corollary of creep, occurs when a piece of skin is

stretched for a given distance and when that distance is held constant. The force required to keep it stretched is gradually decreased (9,10).

In 1987, Bashir (4) performed tissue traction using Kirschner wires for wound closure. Shuker (5) then introduced a technique, using local tissue traction for the management of severe lower lip disfigurement resulting from war injuries. Kirschner wires were used in what remained of the lower lip and the upper teeth.

Günaydın (1) *et al.* used soft tissue traction to reconstruct large soft tissue defects due to odontogenic infections. Following the application of this technique, clinicians have not reported any esthetic or functional problems.

The advantages of skin traction are as follows: it is simple, easy to perform and requires no general

anesthesia. Daily visits and twisting leads to few infectious and wound healing complications. This technique needs no donor area for flap or skin grafts and the cosmetic results are satisfactory. Progressive skin extension performed with Kirschner wires is inexpensive, and can give comparable results. In conclusion, we recommend that Kirschner wires should be used in skin traction to bring the wound edges into contact.

*Correspondence author:*

*Ramazan KÖYMEN*

*Department of Oral and Maxillofacial Surgery,*

*Gülhane Military Medical Academy Dental Sciences Center,*

*Etilik, 06018, Ankara - TURKEY*

## References

1. Günaydın Y, Doğan N, Köymen R, Şimşek A. Odontojenik enfeksiyona bağlı geniş doku kaybının yumuşak doku traksiyonu yöntemi ile tedavisi. *Türk Oral ve Maxillfac Cerr Dergisi* 2 (1-2): 12-16, 1998.
2. Clark N, Birely B, Manson PN, Slezak S, Kolk CV, Robertson B, Crawley W. High-energy ballistic and avulsive facial injuries: Classification, patterns and an algorithm for primary reconstitution. *Plast Reconstr Surg* 98 (4): 583-601, 1996.
3. Shuker ST. Management of severe facial injuries by local tissue traction. *J Oral Maxillofac Surg* 52: 817-820, 1994.
4. Bashir AH. Wound closure by skin traction: An application of tissue expansion. *Br J Plast Surg* 40: 582, 1987.
5. Shuker ST. Severe lower lip disfigurement resulting from war injuries. *J Cranio Max Surg* 18: 304-390, 1990.
6. Kaspar PW, Laskin DM. The effect of porcine skin and autogenous epithelial grafts on the contract of experimental oral wounds. *J Oral Maxillofac Surg* 41: 143-152, 1983.
7. Irvine TT. *Wound Healing: Principles and Practice*, Chapman and Hall. London, New York 1981, pp: 146-151.
8. Molea G, Schonauer F, Blasi F. Progressive skin extension: clinical and histological evaluation of a modified procedure using Kirschner wires. *Br J Plast Surg* 52: 205-208, 1999.
9. Converse JM. *Reconstructive Plastic Surgery* (2nd Ed). Saunders. Philadelphia 1977, pp: 1548, 69-77.
10. Mustoe TA, Bartell TH, Garner WL. Physical, biomechanical, histologic and biochemical effects of rapid versus conventional tissue expansion. *Plast Reconstr Surg* 83 (4): 683-691, 1989.