

Yahya ÜNLÜ¹
Naci CEVİZ²
Bilgehan ERKUT¹
Yusuf VELİOĞLU¹
Hikmet KOÇAK¹

The Large Aortopulmonary Window Without Pulmonary Vascular Disease

Departments of ¹Cardiovascular Surgery,
²Pediatric Cardiology, Faculty of Medicine,
Atatürk University, Erzurum - TURKEY

Received: April 10, 2001

Key Words: Aortopulmonary window, repair

Aortopulmonary window (APW) is a rare congenital cardiac anomaly first described by Elliotson in 1830 in an autopsy study (1). It is hemodynamically similar to large patent ductus arteriosus (PDA) or persistent truncus arteriosus. Since the first successful repair of an APW was reported in 1952 (2), there have been 7 reported series of ≥ 10 cases of APW repair (3-7). We report a good operative course and medium-term outcome of this operative technique for APW with important pulmonary vascular disease in an older patient.

Case Report

The patient was an 8-year-old male who had undergone cardiac catheterization four years before in another medical center. Left ventricle pressure was 127 mmHg, right ventricle pressure was 71 mmHg and main pulmonary artery pressure was 69/33 mmHg (mean: 52mmHg). Aortopulmonary window and pulmonary hypertension had been observed in angiography. Although an operation had been offered in this center, the parent refused due to financial difficulties.

The patient was admitted to the Pediatric Cardiology Unit with the complaints of palpitation and nose bleeding. On admission to our clinic four years later, when the patient was eight years old, physical examination showed that his functional capacity was class II. He was acyanotic and his precordium was hyperdynamic. Corrigan pulse and a grade IV/VI continuous murmur at the left midsternal border were detected. There was left ventricular hypertrophy on electrocardiography and

increased cardiothoracic ratio (65%) on chest roentgenography. Two-dimensional transthoracic echocardiogram demonstrated a large APW with evidence of left-to-right shunt between the ascending aorta and proximal main pulmonary artery, a 40-mmHg-pressure gradient between the aorta and pulmonary artery, a dilated left atrium and ventricle, and a dilated main pulmonary artery. Left ventricular end diastolic diameter (LVEDD) was 62 mm, ejection fraction (EF) 80%, and fractional shortening (FS) 41%. No associated heart defect was detected (Figure 1). Complete cardiac catheterization was performed, which confirmed the presence of APW with main pulmonary arterial pressures of 65/34 mmHg (mean: 50 mmHg) and a pulmonary-to-systemic flow ratio of 3.75, $R_p/R_s = 1.89 \text{ U/m}^2$, $R_s = 11.54 \text{ U/m}^2$ ($R_p/R_s = 16.38\%$) (Figure 2). Our patient had type I APW according to Richardson and colleagues' classification (3,8).

The operation was performed through a median sternotomy. The aortopulmonary window was reached by the transaortic approach. Coronary arteries were normal. The diameter of the APW orifice was about 12 mm. The window was closed with internal patch to the main pulmonary artery. The postoperative course was uneventful. The control echocardiogram early after the operation showed no residual shunt and no stenosis of the ascending aorta and pulmonary artery.

In the fifth postoperative month, the patient was asymptomatic and functional capacity was class I. Electrocardiogram revealed left ventricular hypertrophy,

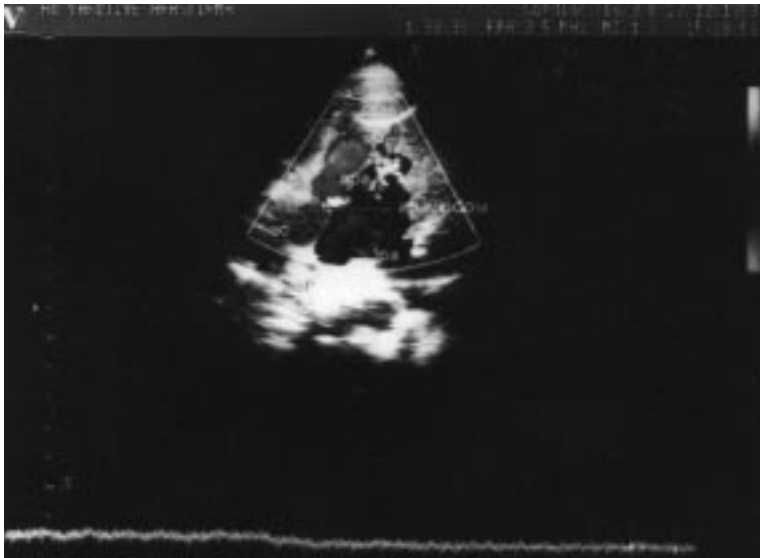

Figure 1. Preoperative echocardiogram of the patient. Parasternal short-axis demonstrates a large APW between the ascending aorta (ao) and pulmonary artery (pa). lpa= left pulmonary artery.

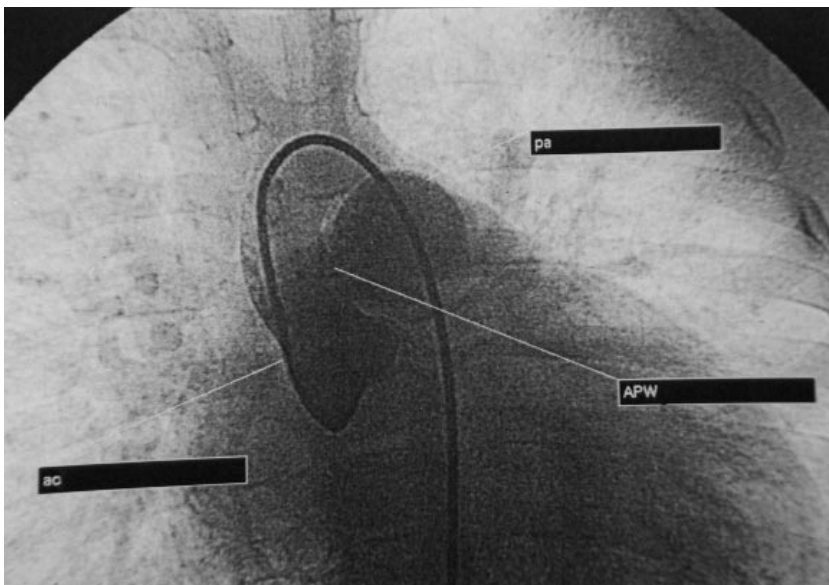


Figure 2. Cardiac catheterization showing a large APW between the ascending aorta (ao) and pulmonary artery (pa).

and the cardiothoracic ratio was 55% on chest roentgenography. Echocardiographic evaluation revealed the absence of residual shunt, LVEDD of 34.5 mm, EF of 63%, and FS of 28%.

Richardson and colleagues (3,8) described three types of APW depending on the abnormal communication between the ascending aorta and pulmonary trunk in the presence of semilunar valves. Aortopulmonary window is an uncommon anomaly that can easily be overlooked if not sought specifically. It is often associated with other cardiac anomalies (7). The most frequent association has

been with patent ductus arteriosus, followed by ventricular septal defect, tetralogy of Fallot, subaortic stenosis, coarctation of the aorta, interrupted aortic arch, anomalous origin of the right or left coronary artery from the pulmonary artery, anomalous origin of the right pulmonary artery from the aorta, bicuspid aortic valve and tricuspid atresia (7). In this patient, other cardiac anomalies were not detected.

Doty and colleagues (7) have reported elevations in the pulmonary vascular resistance in seven of nine patients before the age of 2. These data prompt the

recommendation that aortopulmonary septal defects have to be closed as soon as the diagnosis is established regardless of the age of the patient. This may require emergency surgical repair in the first week of life (7). Although in our patient APW was detected when he was four years old, he was operated on when he was eight years old. Wright and colleagues (9) first introduced the transaortic approach, which is the method of repair that is presently in common use for type I and type II defects. This case was type I APW according to Richardson and colleagues classification (3,8), and repair was performed by the transaortic approach. Reported operative mortality, including infants, varies from 15% to 25% (7). The major cause of mortality in older patients undergoing repair is pulmonary vascular disease (4-6).

Patients with large APWs are rarely seen in childhood or adult life, and those who do survive beyond early life have significant pulmonary vascular disease (7,9).

In general, patients with post-tricuspid shunts such as a ventricular septal defect, a large arterial duct, an atrioventricular septal defect, aortopulmonary window or common arterial trunk are more likely to develop pulmonary hypertension and severe pulmonary vascular

disease than those with a pre-tricuspid shunt, such as an atrial septal defect (10).

In congenital heart disease the variability of the structural response to an increase in pulmonary arterial pressure and flow is not understood. In patients surviving beyond infancy, gradual myocardial deterioration secondary to chronic volume overload of the left ventricle may occur and result in death during childhood, but some patients may survive to adolescence or the early adult years (10).

Therefore, this case is quite interesting because of the large APW without pulmonary vascular disease in childhood.

In conclusion, patients with large APW, admitted even in the late period, have to be evaluated thoroughly as they may still be operable.

Correspondence author:

Yahya ÜNLÜ

Atatürk Mah. Üniversite Loj.

38. Blok, No: 8,

25170, Erzurum, TURKEY

References

1. Elliotson J. Case of malformation of the pulmonary artery and aorta. *Lancet* 1: 247-251, 1830.
2. Gross RE. Surgical closure of an aortic septal defect. *Circulation* 5: 858-863, 1952.
3. Richardson JV, Doty DB, Rossi NP, Ehrenhaft JL. The spectrum of anomalies of aortopulmonary septation. *J Thorac Cardiovasc Surg* 78: 21-27, 1979.
4. Bertolini A, Dalmondo P, Bava GL, Moretti R, Cervo G, Marasini M. Aortopulmonary septal defects: a review of the literature and report of ten cases. *J Cardiovasc Surg* 35: 207-213, 1994.
5. Van Son JAM, Puga FJ, Danielson GK, Seward JB, Mair DD, Schaff HV, Ilstrup DM. Aortopulmonary window: factors associated with early and late success after surgical treatment. *Mayo Clin Proc* 68: 128-133, 1993.
6. McElhinney DB, Reddy VM, Tworetzky W, Silverman NH, and Hanley FL. Early and late results after repair of aortopulmonary septal defect and associated anomalies in infants < 6 months of age. *Am J Cardiol* 81: 195-201, 1998.
7. Doty DB, Richardson JV, Falkovsky GE, et al. Aortopulmonary septal defect: Hemodynamics, angiography and surgery. *Ann Thorac Surg* 32: 244, 1981.
8. Jacobs JP, Quintessenza JA, Gaynor JW, et al. Congenital heart surgery nomenclature and database project: Aortopulmonary window. *Ann Thorac Surg* 69: S44-49, 2000.
9. Wright JS, Freeman R, and Johnston JB: Aortopulmonary fenestration. A technique of surgical management. *J Thorac Cardiovasc Surg* 55: 280, 1968.
10. Mair DD, Edwards WD, Fuster V, et al. Truncus arteriosus and aortopulmonary window. *Pediatric Cardiology* (Eds. Anderson RH, Macartney FJ, Shinebourne EA and Tynan M) Churchill Livingstone, Edinburgh, London, New York 1987, pp: 913-929.