

Duygu DÜŞMEZ<sup>1</sup>  
Gülfiliz GÖNLÜŞEN<sup>2</sup>  
Emel AKOĞLU<sup>3</sup>  
Sevgi KÜLLÜ<sup>4</sup>  
İlhan TUNCER<sup>2</sup>

## Smooth Muscle Actin (SMA) Immunoreactivity in Primary Glomerulonephritis (GN)\*

Received: November 10, 1999

<sup>1</sup>Department of Pathology, Faculty of Medicine, Mersin University, Mersin.  
<sup>2</sup>Department of Pathology, Faculty of Medicine, Çukurova University, Adana.  
Departments of <sup>3</sup>Internal Medicine.  
<sup>4</sup>Pathology, Faculty of Medicine, Marmara University, İstanbul - TURKEY

**Abstract :** The aims of this study were to determine the role of interstitial and glomerular myofibroblasts in the progression of various glomerulonephritis, and to assess the value of myofibroblasts in determining long-term renal outcome.

The biopsy specimens of 42 primary glomerulonephritis cases were reviewed and stained immunohistochemically with alpha smooth muscle actin antibody. The serum creatine level was compared to the pathological changes. The interstitial alpha

smooth muscle actin staining correlated with the serum creatine level at the time of biopsy. The glomerular staining, conversely, did not show any relation with renal function. Interstitial myofibroblasts play a role in the development of progressive renal failure. Increased numbers of myofibroblasts in biopsy specimens may predict subsequent chronic renal failure.

**Key Words:** Glomerulonephritis, smooth muscle actin, interstitium, fibrosis

### Introduction

Glomerulonephritis is one of the major problems in nephrology. The different stages of glomerular disease and the percentage of sclerosed glomeruli are not predictive of outcome. The interstitial pathologies, such as interstitial fibrosis (IF), inflammatory cell reaction (ICR) and tubular atrophy (TA), seem to provide valuable information for the prognosis (1, 2).

The myofibroblast was first described in wound healing (3) and was proposed to play a retractile role in several conditions (4). Myofibroblasts express a variety of cytoskeletal markers, such as alpha smooth muscle actin (SMA) (4). Mesangial cells resemble smooth muscle cells in culture; they can modulate glomerular haemodynamics by controlling glomerular capillary surface area (5, 6). The proliferating cells express SMA in mesangial injury and that was thought to be a sign of activation (6, 7). The appearance of cells bearing a smooth muscle phenotype in mesangial locations may represent smooth muscle cells that migrate into the glomerulus, proliferate, eventually lose alpha smooth muscle actin and "differentiate" into true mesangial cells (6). The origin of the SMA (+) cells

in the interstitium is thought to be mesangial cells, myofibroblasts or myoepithelial cells (8).

Although the knowledge about renal scarring is growing, we need to develop new therapy strategies. The aims of this study were to determine the role of interstitial and glomerular myofibroblasts in the progression of various glomerulonephritis, and to assess the value of myofibroblasts in determining long-term renal outcome.

### Materials and Methods

Forty-two primary glomerulonephritis patients without any systematic disease were studied retrospectively. Serum creatinine value was the clinical prognostic marker. The patients were divided into two groups according to the serum creatinine value above and under 1.2 mg/dl. The intensity of interstitial pathologies (IF, ICR, TA) were noted semiquantitatively (9,10). The glomerular changes (mesangial proliferation, glomerulosclerosis and crescents) were also reviewed (9).

\* This study was published as a poster presentation in XXII International Congress of the International Academy of Pathology, October 18-23,1998- Nice, France.

Histomorphological findings in the interstitium were assessed with respect to the severity of the lesions (IF, ICR, TA). The severity of ICR was evaluated and graded on a scale of + for mild, ++ for moderate, and +++ for severe. The intensity of IF was examined in 20 randomly selected areas (x 250). The scores were among 0-4, as 0: Normal, 1: Less than 10%, 2: 10-30 %, 3: 30-50%, 4: Above 50% (11). TA was characterized by significant thinning of the epithelial cells. Ten consecutive microscopic areas were examined in the cortex of each specimen, with the aid of a x40 objective. The number of microscopic fields in which there was unequivocal tubular atrophy showed the extent of tubular damage. The score was presented as a percentage (12).

For a histological comparison of the degree of glomerular damage, all the glomeruli in each specimen were classified into four scores from 0 (normal) to 10 (sclerosed) in terms of mesangial proliferation and sclerotic change as follows: score 0: almost normal glomerulus; score 2: a glomerulus with segmental or global mesangial proliferation and/ or sclerosis involving about 20% of its area; score 5: a glomerulus with segmental or global mesangial proliferation and/or sclerosis involving about 50% of its area; score 10: total obsolescence, sclerosed glomerulus. The mean score for all the glomeruli was the glomerular index of that specimen (13). The number and the type (fibrous, fibrocellular, cellular) of the crescents were also recorded (11).

**Immunohistochemistry:**

Anti alpha smooth muscle actin antibody (SMA) (Biogenex) was used and evaluated using a semiquantitative method.

The glomerular actin immunoreactivity was noted as 0: negative; 1: Segmental staining in mesangial areas; 2: Staining outlines the mesangial stalk; 3: Staining of the mesangial stalk with focal areas of modularity; 4: Staining of the entire glomerulus with diffuse areas of modularity.

The sclerotic glomeruli were not scored (6). Interstitial staining was evaluated as (-), and (+), (++) , (+++) semiquantitatively. Comparisons were made with kidneys removed for renal cell carcinoma.

Kruskal-Wallis non-parametric ANOVA test, Tukey-Kramer multiple comparison test, linear correlation test, Dunn's multiple comparison test, chi-square test for independence, Mann-Whitney test, unpaired T test and one way analysis of variance (ANOVA) were used as statistical methods.

**Results**

Forty-two kidney needle biopsies proving primary glomerulonephritis were included in this study. The specific diagnosis of the cases were 16 mesangioproliferative glomerulonephritis (MZGN), 15 membranoproliferative glomerulonephritis (MPGN), two diffuse proliferative glomerulonephritis (DPGN), one minimal change (MC), four membranous glomerulonephritis (MGN), one crescentic glomerulonephritis, (CGN), one focal segmental glomerulosclerosis (FSGS), and two chronic sclerosing glomerulonephritis (CSGN). The parameters were not discussed according to the specific diagnosis because they did not form homogenized groups. The ages of the patients ranged from 15 to 70 years (mean 38.5); twenty of them were male and twenty-two were female. Serum creatinine values of patients were 0.6-8 mg/dl. Serum creatinine values of eight patients were not available. Serum creatinine values were above 1.2 mg/dl in 12 cases and under 1.2 mg/dl in 22 cases.

Serum creatinine values showed statistically significant difference for all of the interstitial histomorphological parameters (IF, ICR, TA) (p=0.0126, p=0.0020, p=0.0033). Glomerular changes were not associated with serum creatinine values. The scores of the glomerular index, IF, ICR and TA are presented in Table 1.

Table 1. The number of the cases according to the scores of glomerular index, interstitial fibrosis, interstitial inflammation and tubular atrophy.

Glomerular index				Interstitial fibrosis				Interstitial inflammation			Tubular atrophy	
0	0-2	2-5	5-10	1	2	3	4	(+)	(++)	(+++)	<50%	>50%
27	8	6	1	14	16	4	8	17	19	6	29	13

The results of immunohistochemistry: In the study group, the sclerotic area of the glomeruli was not stained. The immunoreactivity was dense around the tubules. Apart from the specific diagnosis, the interstitium was stained to different degrees. The staining results according to the specific diagnosis are summarized in Table 2. There could be a weak staining in the glomeruli, whereas a strong immunoreactivity was detected in the interstitial tissue, or just the opposite (Figures 1, 2). Some glomeruli showed focal, modest SMA expression of 1+ or 2+ intensity in mesangial areas of the control (normal) group. The myofibroblasts were localized in the periglomerular and peritubular spaces. A strong immunoreactivity was noticed on the vascular walls and perivascular tissue. There were seven crescents in two of the cases in the study group. A slight staining was noted in fibrous crescents and there was no staining in cellular crescents.

Table 2. The number of the cases according to the special diagnosis and glomerular-interstitial SMA expressions.

Diagnosis	N	Glomerular SMA		Interstitial SMA		
		<2	>2	(+)	(++)	(+++)
MPGN	15	10	5	5	3	7
MZGN	16	14	2	9	5	2
DPGN	2	1	1	1	1	0
MC	1	1	0	0	1	0
MGN	4	4	0	1	2	1
CSGN	2	1	1	0	1	1
FSGS	1	1	0	1	0	0
CGN	1	0	1	0	0	1

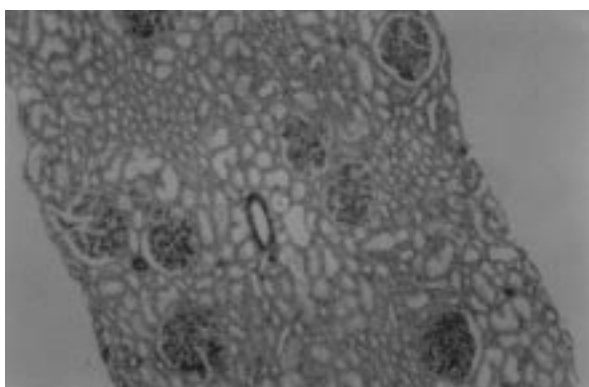


Figure 1. Heavy score (score 4) glomerular SMA immunoreactivity and weak (+) interstitial SMA staining (X 40).

### The correlation between SMA staining and the other parameters:

There was no statistically significant difference in glomerular staining in the two groups above and below 1.2 mg/dl serum creatinine value (unpaired t test,  $p=0.3240$ ,  $p>0.05$ ). A significant difference in the interstitial immunoreactivity was recorded (Kruskal-Wallis test,  $p=0.0036$ ,  $p<0.005$ ) (Table 3). The group which has (+++) interstitial SMA staining provided the difference (Dunn's test,  $p>0.05$ ,  $p<0.05$ ,  $p<0.01$ ).

Glomerular SMA values were not associated with any of the parameters. In contrast, there was a statistically significant correlation between the interstitial SMA staining and the other parameters (IF, ICR, TA) (Table 3), except glomerular changes. The glomerular SMA values were not related to the interstitial SMA immunoreactivity.

### Discussion

In long-term clinical studies, the serum creatinine value is proved to be the most important parameter related to the prognosis and the patient's clinical stage at the time (13-15). The limit value is 1.2 mg/dl (7) or 1.3 mg/dl (14) according to different reports.

ICR may determine the degree of renal functional impairment at biopsy, whereas glomerular changes do so poorly or not at all (1). The pathogenesis of the inflammation of the renal cortical interstitium that is sometimes present and leads to fibrosis does not provide a detailed answer. According to a working hypothesis, in chronic GN, interstitial inflammation (in which T lymphocytes, monocytes, macrophages, fibrocytes, and

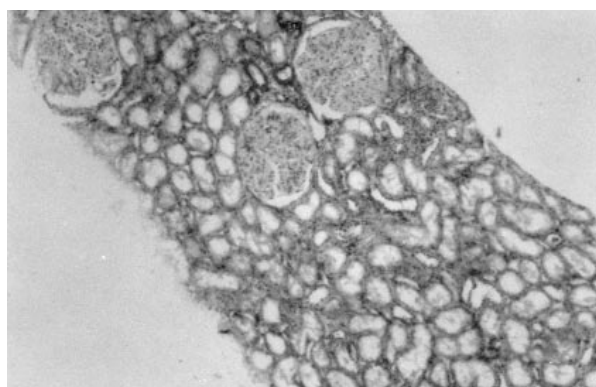


Figure 2. Heavy interstitial SMA staining and a weak (scores 1-2) glomerular SMA immunoreactivity (X40).

Interstitial SMA	Serum Creatinine*	Tubular Atrophy**	Interstitial Fibrosis***	Interstitial inflammation****		
				(+)	(++)	(+++)
(+) n=18	1.18±0.8 (n=15)	1.94±1	1.50±0.61	11	7	0
(++) n=12	0.96±0.16 (n=9)	3.4±1.2	2.08±1.08	6	6	0
(+++) n=12	3.30±3.62 (n=10)	7.6±2.2	3.16±0.93	2	3	7

Table 3. The average level of serum creatinine, number of the cases with variable intensity of interstitial inflammatory inflammation, fibrosis scores and atrophic tubule scores in groups divided according to the interstitial SMA expression.

\* Kruskal-Wallis test, p=0.0036, p<0.005) The group which has (+++) interstitial SMA staining provided the difference (Dunn's test, p>0.05, p<0.05. p<0.01).  
 \*\* ANOVA one way analysis test, p<0.0001; Tukey-Kramer multiple comparison test, p<0.05, p<0.001, p<0.001.  
 \*\*\* ANOVA one way analysis test, p<0.0001; Tukey-Kramer multiple comparison test, p>0.05, p<0.001, p<0.05.  
 \*\*\*\* Q square test, p=0.0002, p<0.0005.

fibroblasts play a major role) always develops when the tubular epithelial cells express autoantigens or foreign antigens on their surface and thereby provoke an immune response induced or augmented via newly expressed major histocompatibility complex (MHC) molecules. This hypothesis is supported by the finding that there are always markedly increased numbers of T lymphocytes in the tubular epithelium in GN if it is complicated by interstitial inflammation. These are T helper cells. It is believed that they recognize and respond to autoantigens or foreign antigens expressed by the tubules, with the result that further activated lymphocytes migrate into the renal cortical interstitium (2). At the same time, cytokines are produced that would activate fibroblasts and fibrocytes, with a consequent increase in the production of collagen I and resultant interstitial fibrosis (2). The fibroblasts derived from the glomerulopathies with interstitial fibrosis, divide faster and more frequently (16). There was a strong correlation between serum creatinine values and the interstitial inflammatory cell infiltration in the present study.

Interstitial fibrosis is the most important morphological parameter (13). The enlargement of the cortical interstitium by fibrosis may lead to a narrowing of the postglomerular vessels, an elevation of the postglomerular flow resistance and a slowing of the glomerular blood flow (17). In our study, there was a strong correlation between the interstitial pathologies and serum creatinine values. Tubulointerstitial changes frequently complicated cases with severe glomerular

lesions. Chronic injury is proposed to be the cause of the interstitial pathologies. As demonstrated in a study, a single injury, as in poststreptococcal glomerulonephritis, causes glomerular change, whereas long-lasting injury causes interstitial fibrosis (18).

There are several hypotheses about the etiopathogenesis of the glomerular and interstitial changes: two changes are distinct in nature (2), or interstitial changes occur after the glomerular pathology has been settled (19). In the present study, glomerulosclerosis accompanied heavy interstitial changes. Thus we think that these changes are probably terminal events and separate from each other. The point is, interstitial changes are important in the patient's survival whether or not glomerular changes are present.

Glomerular cellular crescents consist of epithelial cells, and macrophages undergo an irreversible process of fibrous organization. The origin of the fibroblast type cells that mediate this fibrous organization is unclear. A significant correlation is found between the presence of α SMA and glomerular crescent formation (20). In our study, cellular crescents contained small numbers of α SMA (+) myofibroblasts. They were dominant in fibrous crescents.

Investigations about myofibroblasts in nephrology have begun since the importance of interstitial fibrosis is now understood. The origin of SMA (+) cells is also a problem as the pathogenesis of fibrosis. The mesangial cell expresses SMA and also proliferates when there is an

injury. The clinical importance is not clear but it can be important as a sign of activation (2).

Glomerular SMA expression is thought to be the result of the changing physiological parameters (6, 7). There is no clear-cut knowledge about the interstitial reactions. Interstitial SMA immunoreactivity has been shown to be well correlated with interstitial volume, glomerular filtration rate, interstitial fibrosis, serum creatinine and creatinine clearance in several reports (21-24). A close correlation exists not only between interstitial SMA staining and serum creatinine values, but also between the other parameters according to our results. Some reports have suggested that periglomerular myofibroblasts surrounding the nonsclerotic hypertrophic glomerulus may lead finally to glomerulosclerosis (25, 26). We did not evaluate periglomerular SMA staining as

a separate parameter but as a component of interstitium. There was no correlation between the interstitial SMA staining and glomerulosclerosis. Our data allows limited conclusions, because most of our patients did not have severe glomerulosclerosis. On the other hand, the glomerular SMA staining, except severe lesions, was not associated with serum creatinine values or other histomorphological parameters.

Interstitial sclerosis is a significant prognostic factor, whether or not there is a concomitant glomerular change. The interstitial and glomerular SMA immunoreactivity may be different in origin, or induce one another. At present, we do not have enough knowledge to answer this question. The new therapy strategies to reduce or stop the expression of this protein may be a hope for the future.

## References

- Alexopoulos E, Seron D, Hartley RB, Nolasco F, Cameron JS. Immune mechanisms in idiopathic membranous nephropathy: The role of the interstitial infiltrates. *Am J Kidney Dis* XIII (5): 404-412, 1989.
- Bohle A, Wehrmann M, Bogenschütz O, Batz C, Vogl W, Schmitt H, Müller CA, Müller GA. The long-term prognosis of the primary glomerulonephritides. *Path Res Pract* 188: 908-924, 1992.
- Schürch W, Seemayer TA, Gabbiani G. Myofibroblast. *Histology for Pathologists*. (Ed. Sternberg SS) Raven Press, New York 1992. pp: 109-145.
- Gabbiani G. The biology of the myofibroblast. *Kidney Int* 41: 530-532, 1992.
- Ausiello DA, Kreisberg JI, Roy C, Karnovsky MJ. Contraction of cultured rat glomerular cells of apparent mesangial origin after stimulation with angiotensin II and arginine vasopressin. *J Clin Invest* 65: 754-760, 1980.
- Johnson RJ, Lida H, Alpers C E, Majesky MW, Schwartz SM, Pritzl P, Gordon K, Gown AM. Expression of smooth muscle cell phenotype by rat mesangial cells in immune complex nephritis. *J Clin Invest* 87: 847- 858, 1991.
- Alpers CE, Hudkins KL, Gown AM, Johnson JR. Enhanced expression of "muscle-specific" actin in glomerulonephritis. *Kidney Int* 41: 1134-1142, 1992.
- MacPherson BR, Leslie KO, Lizaso KV, Schwarz JE. Contractile cells of the kidney in primary glomerular disorders. *Hum Pathol* 24: 710-716, 1993.
- Jones C, Buch S, Post M, McCulloch L, Liu E, Eddy AA. Pathogenesis of interstitial fibrosis in chronic purine aminonucleoside nephrosis. *Kidney Int* 40: 1020-1031, 1991.
- Floege J, Eng E, Lindner V, Alpers CE, Young BA, Reidy MA, Johnson RJ. Rat glomerular mesangial cells synthesize basic fibroblast growth factor. *J Clin Invest* 90: 2362-2369, 1992.
- Yoshioka K, Takemura T, Akano N, Miyamoto H, Iseki T, Maki S. Cellular and non-cellular compositions of crescents in human glomerulonephritis. *Kidney Int* 32: 284-291, 1987.
- Risdon RA, Sloper JC, Wardener HD. Relationship between renal function and histological changes found in renal biopsy specimens from patients with persistent glomerular nephritis. *The Lancet* 17: 363-367, 1968.
- Bogenschütz O, Bohle A, Batz C, Wehrmann M, Pressler H, Kendziorra H, Gartner HV. IgA nephritis: On the importance of morphological and clinical parameters in the long-term prognosis of 239 patients. *Am J Nephrol* 10: 137-147, 1990.
- Schmitt H, Bohle A, Reineke T, Eichberger DM, Vogl W. Long-term prognosis of membranoproliferative glomerulonephritis type 1. *Nephron* 55: 242- 250, 1990.
- Wehrmann M, Bohle A, Bogenschütz O, Eissele R, Freislederer A, Öhlschlegel C, Schum G, Batz C, Gartner HV. Long-term prognosis of chronic idiopathic membranous glomerulonephritis. *Clin Nephrol* 31 (2): 67-76, 1989.
- Rodeman HP, Müller GA. Abnormal growth and clonal proliferation of fibroblasts derived from kidneys with interstitial fibrosis. *P.S.E.B.M.* 195: 57-63, 1990.
- Bohle A, Glomb D, Grund KE, Mackensen S. Correlation between relative interstitial volume of the renal cortex and serum creatinine concentration in minimal changes with nephrotic syndrome and in focal sclerosing glomerulonephritis. *Virchows Arch A Path Anath and Histol* 376: 221-232, 1977.

18. Yamamoto T, Noble NA, Miller DA, Border WA. Sustained expression of TGF- $\beta$ 1 underlies development of progressive kidney fibrosis. *Kidney Int* 45: 916-927, 1994.
19. Widstam-Attorps U, Berg U, Bohman SO, Lefvert AK. Proteinuria and renal function in relation to renal morphology. A clinicopathological study of IgA nephropathy at the time of kidney biopsy. *Clin Nephrol* 38 (5): 245-253, 1992.
20. Ng YY, Fan JM, Mu W, Nikolic-Paterson DJ, Yang WC, Huang TP, Atkins RC, Lan HY. Glomerular epithelial-myofibroblast transdifferentiation in the evolution of glomerular crescent formation. *Nephrol Dial Transplant* 14(12): 2860-72, 1999.
21. Goumenos D, Tsomi K, Iatrou C, Oldroyd S, Sungur A, Papaioannides D, Moustakas G, Ziroyannis P, Mountokalakis T, El Nahas AM. Myofibroblasts and the progression of crescentic glomerulonephritis. *Nephrol Dial Transplant* 13(7): 1652-61, 1998.
22. Danilewicz M, Antoszczyk L, Wagrowska-Danilewicz M. Quantitative analysis of the interstitial myofibroblasts in idiopathic mesangiocapillary glomerulonephritis type I. *Pathol Res Pract* 195(10): 663-8, 1999.
23. Badid C, Desmouliere A, McGregor B, Costa AM, Fouque D, Hadj Aissa A, Laville M. Interstitial alpha-smooth muscle actin: a prognostic marker in membranous nephropathy. *Clin Nephrol* 52(4): 210-7, 1999.
24. Roberts IS, Burrows C, Shanks JH, Venning M, McWilliam LJ. Interstitial myofibroblasts: predictors of progression in membranous nephropathy. *J Clin Pathol* 50(2): 123-7, 1997.
25. Oba S, Kimura K, Suzuki N, Mise N, Tojo A, Miyashita K, Konno Y, Hirata Y, Goto A, Omata M. Relevance of periglomerular myofibroblasts in progression of human glomerulonephritis. *Am J Kidney Dis* 32(3): 419-25, 1998.
26. Zhang G, Moorhead PJ, el Nahas AM. Myofibroblasts and the progression of experimental glomerulonephritis. *Exp Nephrol* 3(5): 308-18, 1995.