

Egemen İDİMAN¹
Göksemin DEMİR¹
Ümit Ali KAYIŞLI²
İhsan Şükrü ŞENGÜN¹
Necdet DEMİR²
Ramazan DEMİR²

Distribution of Some Extracellular Matrix Proteins and Ultrastructural Findings in Sural Nerve Biopsy in Demyelinating Disease

Received: February 03, 2000

Abstract: The involvement of both the peripheral nervous system (PNS) and central nervous system (CNS) in multiple sclerosis is a seldom encountered combination in neurology clinics. In this report, immunohistochemical and ultrastructural techniques were used to analyse the disease course of a patient exhibiting involvement of both systems.

In 1980, a 44-year-old man was admitted to our clinic with progressive weakness and decreased sensation of the right lower extremity, and sensory abnormality exhibiting stocking distribution. In electromyography (EMG), demyelinating sensory motor polyneuropathy was determined. Ten years later, he was admitted again due to progression of weakness in the four extremities. Pyramidal and cerebellar signs, and loss of deep sensation were included in the clinical picture. An EMG investigation revealed severe segmental demyelination. Hyperintense lesions were determined in the periventricular deep white matter and the corpus callosum using cranial magnetic resonance imaging (MRI). This patient was considered to be exhibiting a course of demyelinating disease in which PNS and CNS

were involved. In order to eliminate other reasons for peripheral neuropathy (PN), a sural nerve biopsy was carried out. The expression of several extracellular matrix (ECM) proteins (fibronectin, laminin, collagen type-IV), their respective receptors (integrin $\alpha 5$ and $\beta 4$ subunits), intermediate filaments (vimentin) and S-100 protein was investigated by means of immunohistochemical methods. In addition, peripheral nerve tissue samples were evaluated ultrastructurally.

Immunohistochemical stainings revealed an increase in the expression of ECM molecules, such as fibronectin, laminin and collagen type-IV, and their respective receptors, $\alpha 5$ and $\beta 4$. This alteration might be a result of a Schwann-axon relationship. Vimentin expression was found to have changed in the Schwann cells and S-100 immunoreactivity decreased in the region near the Schwann-axon interface. Our ultrastructural findings showed myelin fragmentation, axon vacuolisation and degeneration.

Key Words: multiple sclerosis, sural nerve, fibronectin, laminin, integrin $\alpha 5$ and $\beta 4$ subunits

Departments of ¹Neurology, Faculty of Medicine, Dokuz Eylül University, İzmir, ²Histology and Embryology, Faculty of Medicine, Akdeniz University, Antalya - TURKEY

Introduction

Multiple sclerosis (MS) is generally known to be a central nervous system (CNS) disease characterised by dissemination of demyelinating plaques (1-3). Abnormalities in peripheral nerves are rare observations in MS and are frequently attributed to factors associated with malnutrition, compression or cytotoxic drugs (4). In a previous study, large amounts of abnormal teased fibers and a reduction in myelin thickness were reported (3). The authors suggested a possible alteration in the peripheral myelin. Furthermore, extended demyelination, onion-bulb formations in nerve roots, and the presence of inflammatory cells have been found in some other studies (1, 5-7). All of these data support the involvement of

both the PNS and CNS in multiple sclerosis. It is known that myelin structures exhibit a similar macromolecular organisation in both systems, which leads to the formation of closely related epitopes (8). This might be the reason for some sort of a cross reactivity between the PNS and CNS in some individuals (9-11).

Matrix metalloproteinases (MMPs) are highly expressed during the course of the disease and are frequently emphasised in the pathogenesis of MS (12-14). Together with adhesion molecules, MMPs can be responsible for the destruction of the extracellular matrix (ECM) in the blood-brain barrier (12). As a result, inflammatory mononuclear cells will migrate into the CNS and damage the myelin structure (15-19). The same

destructive proteolytic process can also be considered for the involvement of the PNS in MS (20-22). In order to shed light on this, we performed immunohistochemical and ultrastructural analysis of a sural nerve biopsy from a patient who exhibited CNS demyelination accompanied with polyneuropathy in PNS. In the immunohistochemical analysis, we evaluated the distribution of some ECM proteins (laminin, collagen IV and fibronectin), their adhesive receptors (integrin α 5 subunit for fibronectin and integrin β 4 subunit for laminin and collagen), intermediate filaments (vimentin) and adhesive molecules (S100 protein). In the ultrastructural analysis, we studied the fine structure organisation.

Materials and methods

Patient

A 44-year-old man was admitted to hospital in 1980 because of progressive weakness and decreased sensation of the right lower extremity. In a routine neurologic examination, a mild weakness was found in the right lower extremity, accompanied by sensory abnormality in stocking distribution. In an EMG investigation demyelinating sensory motor polyneuropathy was determined. The patient was recovered within a month, but he was not aware of the nature of the treatment.

Ten years later, he was admitted again because of a progression in weakness in the four extremities. Pyramidal and cerebellar signs and loss of deep sensation were added to the clinical picture in neurologic examination. An EMG investigation revealed severe segmental demyelination. In cranial MRI, hyperintense lesions were determined in the periventricular deep white matter and the corpus callosum. He was treated with intravenous methylprednisolone and the patient suffered no more complaints.

During the previous 10 years the complaints of the patient slowly progressed. In his last visit to our clinic, prominent mild tetraparesis in the right half of the body, sensory abnormalities in stocking distribution, severely diminished vibration and position sense, bilateral cerebellar signs, and atrophy in the tenar, hypotenar, interosseus, pectoral and deltoid muscles were determined.

The last EMG revealed severe segmental demyelination with mild partial axonal degeneration,

where the sensory component was totally involved. In cranial MRI, a relatively diffuse increase in demyelinating plaques was observed bilaterally. These plaques were vertically localised to the septocallosal margin in the periventricular deep white matter.

Immunohistochemistry

A sural nerve biopsy was carried out and 5 μ m-sections from paraformaldehyde fixed and paraffin embedded material were prepared. These sections were used for immunohistochemical localisation.

The sections were deparaffinised and then immersed in methanol containing 3 % H₂O₂ so as to block endogenous peroxidase activity (37°C, 10 minutes). Then the sections were washed with phosphate-buffered saline (PBS, 10mM, pH, 7.2) at room temperature for 30 minutes. After the blocking of non-specific binding with normal multispecies serum at 37°C for 20 minutes, the sections were incubated with primary monoclonal antibodies against laminin (1/50 dilution), collagen type IV (1/50 dilution), fibronectin (1/1500 dilution), integrin β 4 (1/1000 dilution), integrin α 5 (1/1000 dilution), vimentin (1/100 dilution) and S 100 (1/100 dilution). After incubation at 37°C for 60 minutes, the sections were washed with PBS and incubated with biotin-bound goat anti-mouse IgG antibody (37°C, 30 minutes). Following several washing steps with PBS, the sections were incubated with horseradish peroxidase conjugated to streptavidine (37°C, 30 minutes). The immunostaining was developed with 3,3-diaminobenzidine chromogen at room temperature for 10 minutes. The sections were counterstained with hematoxyline, mounted with cover slips and examined under a light microscope.

Ultrastructural analysis

The sural nerve biopsy samples were fixed by immersion in 2.5% glutaraldehyde in 0.1 M cacodylate buffer (pH 7.4) at room temperature for 4 hours and postfixed in 1% phosphate-buffered osmium tetroxide for 2 hours. The samples were dehydrated in an ascending ethanol series and were embedded in araldyte-epoxy resin. Semithin and ultrathin sections were taken with an ultratome. After staining with uranyl acetate and lead citrate, the sections were examined with a Jeol 100 C electron microscope.

Results

Immunoreactivities for laminin and integrin $\beta 4$ subunit were observed in the basal lamina of both Schwann cells and vessel wall components. The cytoplasm of connective tissue cells, which were distributed around peripheral nerve bundles, were not immunoreactive for laminin or integrin receptor $\beta 4$. However, the perineurium and endoneurium were immunoreactive for these antibodies (Figures 1a, b). The staining for collagen type IV was similar to that for laminin (Figure 1c). The immunoreactivities obtained by antibodies against fibronectin and integrin $\alpha 5$ subunit were abundant in the Schwann cells, but the stroma was very weakly reactive (Figures 2a, b).

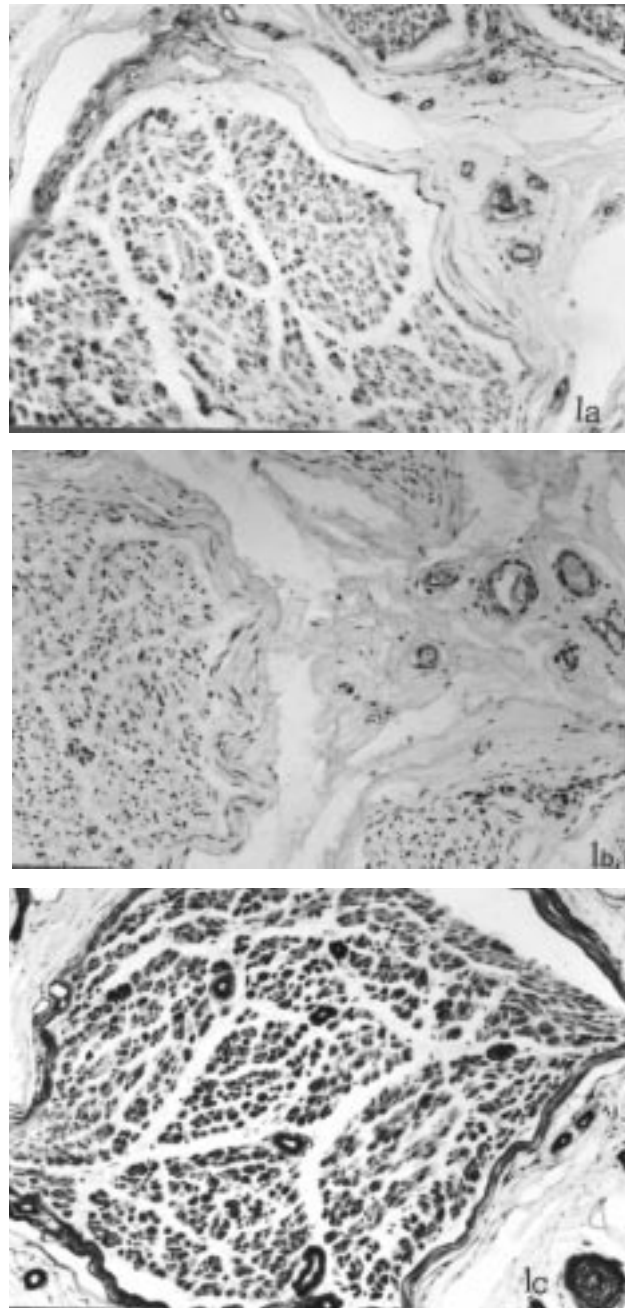
In some segments of the sural nerve, the Schwann cells exhibited an increase in vimentin expression, whereas in some segments preserving axon-Schwann contact, vimentin immunoreactivity was weak. The intensity of vimentin immunoreactivity decreased as long as the relationship between the Schwann cells and axons continued (Figure 7). The connective tissue cells in the epineurium were also strongly immunoreactive with vimentin antibody.

S100 immunoreactivity decreased in the contact areas between the Schwann cells and axons of the sural nerve. Both structures demonstrated heterogeneous immunoreactivity in different nerve segments (Figure 8).

Electron microscopic analysis of the sural nerve biopsy revealed myelin fragmentation, referred to as onion-bulb neuropathy, in different configurations and with different diameters. The presence of segmental demyelination and the proliferation of Schwann cells in a concentrated manner were determined. In addition, many onion bulbs, collateral myelin figures and numerous regenerative myelin clusters were observed. In contrast to active demyelination, the Schwann cells exhibited striking degeneration (Figures 3-6).

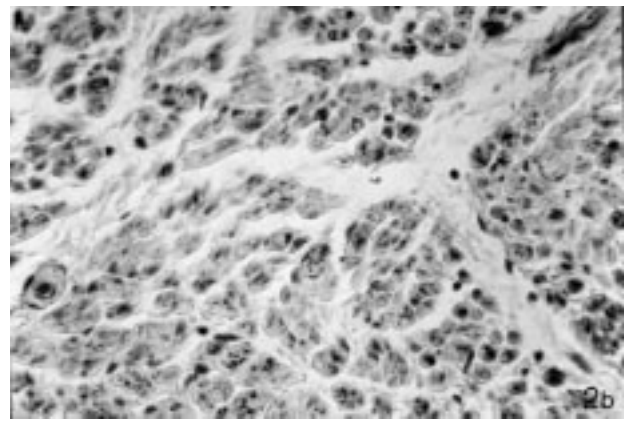
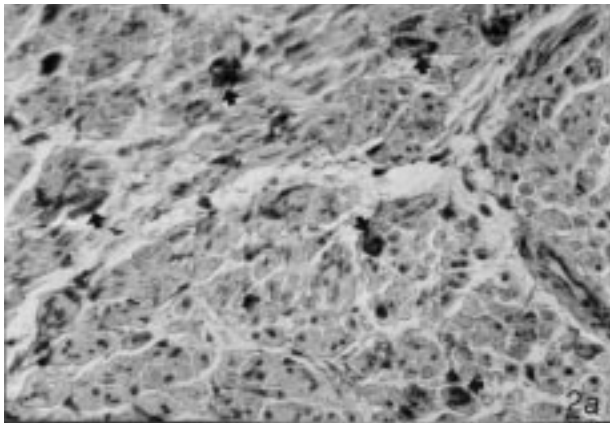
Discussion

MS is characterised by demyelinated areas spread throughout the central nervous system (CNS). Although it is very rare, PNS involvement can accompany classical CNS disease. In this study, we demonstrated the presence of a remarkable relationship between the peripheral neuropathy and CNS demyelination. In the literature,



Figures 1a-c. The normal intensity of immunoreactivity of laminin (a) and its receptor integrin $\beta 4$ subunit (b) can be seen in the sural nerve section when compared with the peripheral connective tissue components. The intensity of collagen type VI (c) immunoreactivity is weak as the laminin staining and its immunoreactivity is low compared to the perivascular tissue. Original magnification, X50.

the presence of peripheral neuropathy together with central demyelination has been reported in only a few



Figures 2a and 2b. Fibronectin (a) and its receptor integrin $\alpha 5$ subunit (b) can be seen in these micrographs. Strong staining may be detected in some Schwann cells (SC), dependent upon their affinity to the antibody (single arrows). Original magnifications, a: X50, b: X100.

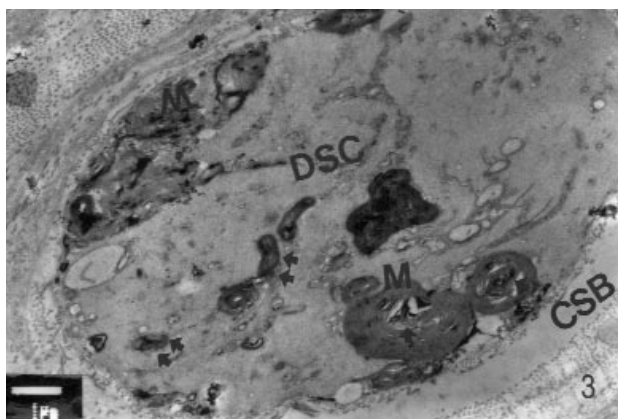


Figure 3. A topographic view of the sural nerve can be seen in this electronmicrograph. Severe structural degeneration, Schwann cell proliferation and also degeneration and onion-bulb formation (single arrows) are striking results. There is structural degeneration and fragmentation in the myelin sheaths (M), myelin remnants (double arrows) in degenerated Schwann cells (DSC), and increased colloidal substance (Col) between the Schwann cells and endoneurium. Original magnification, X5000.

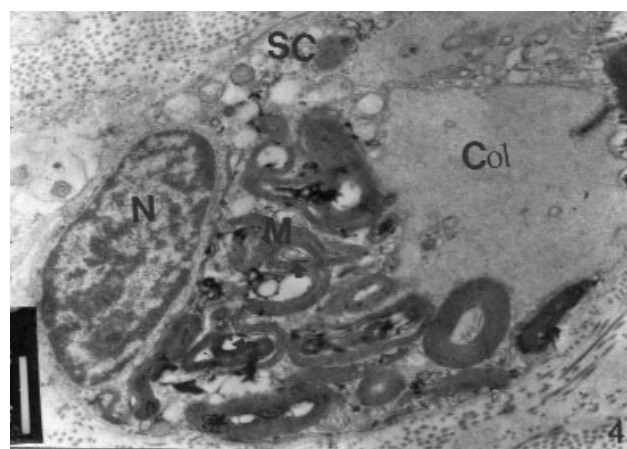


Figure 4. In this electronmicrograph, a Schwann cell (SC) with a heterochromatic nucleus (N), colloidal oedema (Col) and myelin fragments (M) in its cytoplasm can be observed. Original magnification, X8000.

cases (1, 5, 9, 10). Ro et al. (1) observed hypertrophic changes in a sural nerve biopsy from a patient having a clinical background for MS. In other research, in addition to hypertrophic degeneration, focal demyelination and mononuclear infiltration in the peripheral nerve tissue of MS patients reported (7, 23). However, Pollock et al. (6) suggested that neither demyelination nor remyelination is associated with PNS in MS patients.

In the present study, immunohistochemistry and electron microscopy revealed alterations in the expression of different sural nerve components. Increase in

immunoreactivities for fibronectin, integrin $\alpha 5$ subunit and vimentin suggest ongoing Schwann cell differentiation and migration in several segments of the peripheral nerve. It has been suggested that fibronectin and its receptor play a role in the pathophysiology of inflammation during tissue remodelling (24). In a previous study, the relationship between the ECM (fibronectin and laminin) and neurophilic reaction (astrocytes, macrophages and microglia) in the sural nerve biopsy of a patient with central demyelinating disease was discussed (25). Furthermore, a high number of macrophages and microglia have been observed in the CNS of MS patients, dependent upon the occurrence of lesions (25, 26). Blakemore and Crang (27) suggested

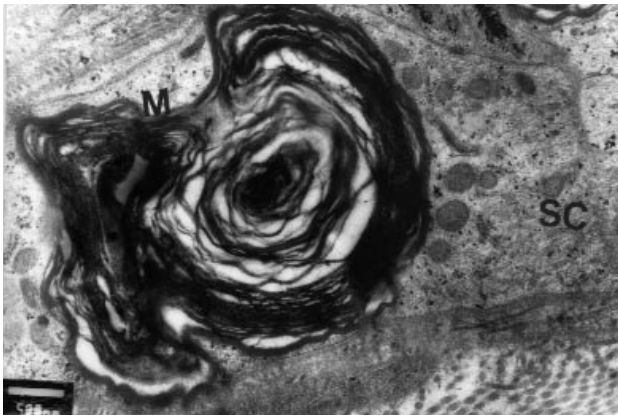


Figure 5. High magnification of onion-bulb formations in the sural nerve in the MS patient. Degenerated areas between the axon and Schwann cells (SC) at opposite faces including the myelin (M) sheath and axolemma can be seen. Original magnification, X12,000.

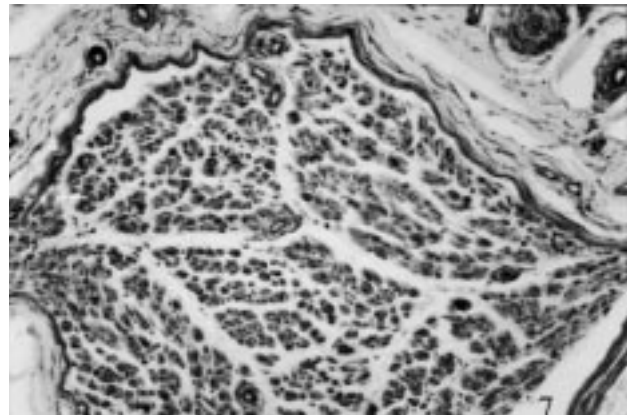


Figure 7. Vimentin immunoreactivity is very strong in the transverse section of the sural nerve in the MS patient. According to the Schwann cell (SC) proliferation and remyelination in the segmental area, the vimentin immunoreactivity is increased. In the perineurium and in the vascular wall, strong vimentin immunoreactivity is present. Original magnification, X50.

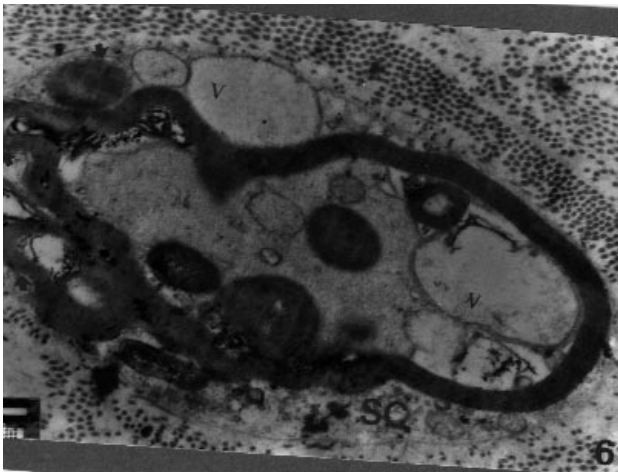


Figure 6. Degenerated segmental nerve bundle that is supported and limited by connective tissue of the endoneurium. The formation of collateral myelin infoldings (single arrows) on the Schwann cell (SC) and vacuolisation (V) in axoplasm and remyelination in the SC are interesting findings. Original magnification, X12,000.

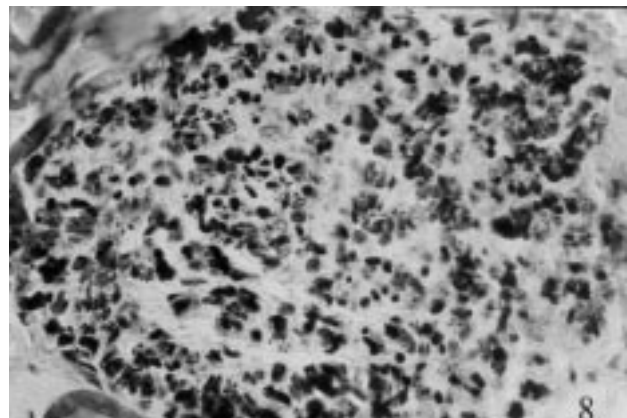


Figure 8. This micrograph shows S100 protein expression in a Schwann cell (SC). A heterogeneous immunoreaction for S100 protein can be observed. Original magnification, X50.

that the cells in the lesion site could influence the extent of Schwann cell remyelination. However, the presence of the ECM seems to be the main factor influencing Schwann cell remyelination (12, 25).

In our study, we observed heterogeneous stainings for S100 protein. Together with the alterations in the expression of several ECMs, this finding suggests loss of contact between Schwann cells and axons. Our ultrastructural observations also demonstrate that onion bulbs are formed, and that by means of collateral

segments, demyelination and remyelination take place. On the basis of these findings, it seems that there is a very active matrix reorganisation in the sural nerve. The family of matrix metalloproteinases (MMPs) might play an important role in this reorganisation. These enzymes are known to degrade the components of the ECM in many tissues (12). Their degradative effect was also described in vascular basement membrane, permitting leukocyte migration into inflammation sites (12, 17). Vitronectin and its integrin receptor in particular have multiple functions in demyelinating lesions, such as in

clotting and leukocyte extravasation (16, 21, 22). In CNS lesions in MS, the presence of inflammatory cells expressing MMPs has been reported (16, 22, 26, 28). Therefore, these molecules might contribute to the tissue destruction and matrix remodelling in PNS and CNS.

We can conclude from our results that alterations in the PNS accompany to the demyelination of the CNS. These alterations include altered expression of the ECM (fibronectin), ECM receptors (integrin $\alpha 5$ subunit), intermediate filaments (vimentin) and adhesion molecules (S100 protein). In addition to this matrix reorganisation, peripheral conduction is impaired due to myelin damage and fragmentation, axonal vacuolisation, degeneration of Schwann cells, accumulation of extracellular fluid and segmental edema. We believe that the progression in the complaints of the 44-year-old patient is closely related to these pathophysiological changes. The clinical course of this patient is dependent upon the severity of

immunological attack as well as the other causes in both the PNS and CNS. This will most probably result in an increase in MMP expression, turnover and reorganisation of the ECM, activation and proliferation of Schwann cells and degeneration of myelin sheaths. Future studies that make use of advanced immunological and molecular methods should answer the question of whether these two entities share common etiologic factors and pathophysiological pathways.

Correspondence author:

Ramazan Demir

Akdeniz Üniversitesi, Tıp Fakültesi,

Histoloji ve Embryoloji Anabilim Dalı

0707 Kampus Antalya - TURKEY

References

1. Ro YI, Alexander B., Oh SJ. Multiple sclerosis and hypertrophic demyelinating peripheral neuropathy. *Muscle and Nerve* 3: 312-316, 1983.
2. Rubin M, Karpati G, Carpenter S. Combined central and peripheral myelin damage. *Neurology* 37:1287-1290, 1987.
3. Sarova-Pinhas I, Achiron A, Gilad R, Lampi Y. Peripheral neuropathy in multiple sclerosis: a clinical and electrophysiologic study. *Acta Neurol. Scand.* 91: 234-238, 1995.
4. Miglietta O, Lowenthal M. A study of peripheral nerve abnormality. *Brain* 100:755-775, 1987.
5. Lassmann H, Bndhe H, Schnaberth G. Inflammatory demyelinating polyradiculitis in a patient with MS. *Arch. Neurol.* 38: 99-102, 1981.
6. Pollock M, Calder C, Allpress S. Peripheral nerve abnormality in multiple sclerosis. *Ann. Neurol.* 2: 41-48, 1977.
7. Schoene WC, Carpenter S, Behan BO, Geschwind N. Onion bulb formations in the central and peripheral nervous system in association with multiple sclerosis and hypertrophic polyneuropathy. *Brain* 100: 755-775, 1977.
8. Cannella B, Raine CS. The adhesion molecule and cytokine profile of multiple sclerosis lesions. *Ann Neurol* 37(4): 424-435, 1995.
9. Shefner JM, Carter JL, Krarup C. Peripheral sensory abnormalities in patients with multiple sclerosis. *Muscle and Nerve* 15:73-76, 1992.
10. Thomas PK, Walker WH, Rudge P. Chronic demyelinating peripheral neuropathy associated with multifocal central nervous system demyelination. *Brain* 110:53-76, 1987.
11. Waxman SG. Peripheral nerve abnormalities in multiple sclerosis. *Muscle and Nerve.* 1-5,1993.
12. Maeda A, Sobel RA. Matrix metalloproteinases in the normal human central nervous system microglial nodules and multiple sclerosis lesions. *J. Neuropathol. Exp. Neurol.* 55: 300-309, 1996.
13. Traugott U. On the immunopathology of multiple sclerosis lesions. *Ital. J.Neurol Sci.* 13: 37-45, 1992.
14. Yong VW, Krekoski CA., Forsyth PA. Matrix metalloproteinases and diseases of the CNS. *Trends Neurosci* 21:75-80, 1998.
15. Calabresi PA, Pelfrey CM, Tranquill LR. VLA-4 expression on peripheral blood lymphocytes is downregulated after treatment of multiple sclerosis with interferon beta. *Neurology* 49:1111-1116, 1997.
16. Ebadi M, Bashir RM, Heidrick ML. Neurotrophins and their receptors in nerve injury and repair. *Neurochem Int.*30: 347-374, 1997.
17. Lou J, Chofflon M, Juillard C. Brain microvascular endothelial cells and leukocytes derived from patients with multiple sclerosis exhibit increased adhesion. *Neuroreport* 8:629-633, 1997.
18. Milner R. Understanding the molecular basis of cell migration; implications for clinical therapy in multiple sclerosis. *Clin. Sci.* 92: 113-122, 1997.
19. Romanic AM, Madri JA. Extracellular matrix-degrading proteinases in the nervous system. *Brain Pathol* 4:145-156, 1994.
20. Sobel RA, Mitchell ME, Fondren G. Intercellular adhesion molecule-1 (ICAM-1) in cellular immune reactions in the human central nervous system. *Am. J. Pathol* 136:1309-1316, 1990.

21. Sobel RA, Chen M, Maeda A. Vitronectin and integrin vitronectin receptor localisation in MS lesions. *J.Exp.Neuropathol.*54: 202-213, 1995.
22. Wiemman B, Van GY, Danilenko M. Combined treatment of acute EAE in Lewis rats with TNF-binding protein and interleukin-1 receptor antagonist. *Exp. Neurol* 149:455-463, 1998.
23. Rosenberg NL, Bourdette D. Hypertrophic neuropathy and multiple sclerosis *Neurology* 33,1361-1364, 1983.
24. Sobel RA. The extracellular matrix in multiple sclerosis. *Neuropathol.Exp. Neurol.*57(3): 205-217, 1998.
25. Esiri MM, Morris CS. Immunocytochemical study of macrophage and microglial cells and extracellular matrix components in human CNS disease. *J. Neurology Science* 101:59-72, 1991.
26. Weber F, Meinl E, Aloisi F. Human astrocytes are only partially component antigen presenting cells. Possible implication for lesion development in multiple sclerosis. *Brain* 117: 59-69, 1994.
27. Blakemore WF, Crang AJ. The use of cultured autologous Schwann cells to remyelinate areas of persistent demyelination in the central nervous system. *J.Neurol Sci.* 70:207-223, 1985.
28. Chandler S, Miller KM, Clements JM. Matrix metalloproteinases, tumour necrosis factor and multiple sclerosis: an overview. *J. Neuroimmunol.* 72: 155-161, 1997.