

## Are Inflammatory Cytokines Potential Mediators of Phenytoin-induced Gingival Overgrowth?

Received: August 02, 2000

**Abstract :** The levels of interleukin-1beta, tumour necrosis factor-alpha, and interleukin 6 in gingival crevicular fluid of phenytoin-treated patients (from sites exhibiting overgrowth and sites not exhibiting overgrowth) and control subjects were investigated. Six epileptic patients exhibiting severe phenytoin-induced gingival overgrowth, 12 patients with chronic gingivitis and 11 subjects with clinically healthy periodontium were included in the study. The cytokine levels were analysed by enzyme-linked immunosorbent assay and expressed as ng/2 sites. Wilcoxon signed-rank test, Kruskal-Wallis, Mann-Whitney U test and Spearman rank correlation were used for statistical analysis of the data. Overgrown sites showed significantly higher levels of interleukin-1beta compared to the healthy and gingivitis sites ( $p=0.0009$ ,  $p=0.049$

respectively). However, the difference was not statistically significant between overgrown and non-overgrown sites in epileptic patients ( $p=0.1159$ ). Tumour necrosis factor-alpha values did not reveal any significant difference among the study groups. For interleukin 6, the highest value was found in the gingivitis sites, followed by overgrown, non-overgrown, and healthy sites, in descending order. No correlation was found between gingival crevicular fluid cytokine levels and papilla bleeding index values in phenytoin-treated patients. The results suggest that these cytokines play an indirect role in the complex mechanism of phenytoin-induced gingival overgrowth.

**Key Words:** phenytoin, interleukin-1beta, tumour necrosis factor-alpha, interleukin-6, gingival crevicular fluid

<sup>1</sup>Department of Periodontology, Faculty of Dentistry, <sup>2</sup>Department of Paediatrics, Faculty of Medicine, Ege University, İzmir - TURKEY

### Introduction

Phenytoin (PHT) is an anti-convulsant drug commonly used in the management of epilepsy. PHT treatment is likely to cause a broad spectrum of side effects, including skeletal, hepatic, immunological, and connective tissue disturbances (1). Each year up to 50 per cent of an estimated two million people taking PHT for prevention of seizures develop severe gingival overgrowth and require surgical intervention. The exact cellular/molecular mechanism of this side effect remains unclear (2). It was proposed that PHT could react with a phenotypically distinct subpopulation of gingival fibroblasts and cause an increase in protein synthesis and cell proliferation rate (3). Furthermore, Dill et al. (4) and Iacopino et al. (5) have suggested that PHT may promote drug-induced gingival overgrowth by altering macrophage phenotype, which results in an increased production of cytokines or growth factors.

Interleukin-1beta (IL-1 $\beta$ ) and tumour necrosis factor-alpha (TNF- $\alpha$ ) are inflammatory cytokines mainly secreted by activated monocyte/macrophages (6). IL-1 $\beta$

and TNF- $\alpha$  possess various biological effects, including induction of fibroblast growth and synthesis of matrix by fibroblasts (7), and also production of collagenase (8). Interleukin-6 (IL-6) is a major mediator of host response to tissue injury and infection (9). This cytokine plays a major role in B-cell differentiation and fibroblast growth inhibition. It has been suggested (10) that IL-6 interferes with functions of various cytokines, which stimulate fibroblast activity (11). Recently, it was reported that TNF- $\alpha$  induces IL-1 $\beta$  production (12) and prostaglandin E<sub>2</sub> formation in gingival fibroblasts that was upregulated by PHT (13). In another in vitro study it was found that both IL-1 $\beta$  and PHT reduce the expression of  $\alpha$  1 (I) procollagen mRNA in gingival fibroblasts (14). In light of these findings, it may be hypothesised that an interaction between PHT and cytokines plays a role in the mechanism of drug-induced gingival overgrowth. Therefore, the present study was planned in order to investigate the quantities of IL-1 $\beta$ , TNF- $\alpha$  and IL-6 in the gingival crevicular fluid (GCF) of patients with PHT-induced gingival overgrowth.

## Materials and Methods

### Patient selection

Six epileptic patients followed by the Department of Neurology, Faculty of Medicine, Ege University, exhibited severe gingival overgrowth requiring periodontal surgery together with gingivitis. All of these patients (4 female, 2 male) (mean age  $25.83 \pm 0.41$  years) had been taking PHT for  $\geq 6$  months without any recent change in the therapeutic dosage. Twelve patients (7 female, 5 male) (mean age  $30.4 \pm 11$  years) with gingivitis and 11 subjects (5 females, 6 males) (mean age  $30.8 \pm 9.5$  years) with clinically healthy periodontium were included in the study as controls. There was no history of any other systemic disease in the epileptic patients and no treatment with drugs known to induce gingival overgrowth in any of the subjects in the two control groups. Clinical recordings including plaque index (PI) (15), papilla bleeding index (PBI) (16) and hyperplastic index (HI) (17) were performed prior to any periodontal intervention. The degree of gingival overgrowth was classified in 4 categories based on the criteria of Angelopoulos and Goaz (18) as modified by Pernu et al. (17) Those PHT-treated patients who had moderate or severe gingival overgrowth were included in this study. Radiographically, there was no evidence of alveolar bone loss in any of the subjects participating in the study.

### GCF sampling and cytokine analysis

In total, 70 GCF samples from 29 people were collected from the following sites in four groups: Group 1, PHT GO+ sites (2 sites with PHT-induced gingival overgrowth in each PHT-treated patient); group 2, PHT GO- sites (2 sites without PHT-induced gingival overgrowth in each PHT-treated patient); group 3, gingivitis sites (2 inflamed sites in each gingivitis patient, with a PBI score of  $\geq 1$ ), group 4, healthy sites (2 clinically healthy sites from each periodontally healthy subject). Informed consent was obtained from all the subjects before they were included in the study protocol. Supragingival plaque was removed by sterile curettes and, after air-drying, the surfaces were isolated by cotton rolls. Mechanical irritation was avoided and strips contaminated with blood were discarded. GCF samples were obtained by inserting filter paper strips (Periopaper, ProFlow Inc., Amityville, NY) for 30 seconds into interproximal sites from the buccal aspects of the relevant teeth. Collected GCF volume was determined by Periotron 6000 (Harco Electronics Ltd., Winnipeg,

Manitoba, Canada) and the strips were placed in sterile polypropylene tubes before freezing at  $-40^{\circ}\text{C}$ . Cytokine levels in GCF samples were analysed by using enzyme-linked immunosorbent assay (ELISA) and the relevant ELISA kits; RPN2141, RPN2148, and RPN2145 (Amersham Int. Buckinghamshire, UK).

As previously described, (19), GCF samples were eluted from the strips by placing them in  $400 \mu\text{l}$  of PBS/0.1%BSA/0.05%thimerosal for 18 hours at  $4^{\circ}\text{C}$ . The results were expressed as ng/2 sites.

### Statistical analysis

Statistical analysis was performed by non-parametric techniques. Wilcoxon signed-rank test (confidence interval of  $p < 0.05$ ) was used to compare the clinical recordings and the cytokine levels between the PHT GO+ and PHT GO- sites. Kruskal-Wallis test was used to compare the PHT groups with gingivitis and clinically healthy control groups. In the presence of significant difference ( $p < 0.05$ ), Bonferroni-corrected Mann-Whitney U test was used for pair-wise comparisons. Additionally, the correlation between mean values of GCF IL-1 $\beta$ , TNF- $\alpha$ , and IL-6 levels in PHT-treated patients and PBI scores were assessed by Spearman rank correlation.

## Results

Mean values of clinical measurements are listed in Table 1. While the GCF volumes in PHT GO+ and gingivitis sites were much the same, those of healthy and PHT GO- sites were significantly lower. No statistically significant age difference was found between the groups. PI and PBI values at PHT GO- sites were significantly lower compared to the values of PHT GO+ and gingivitis sites. Both of the PHT groups (PHT GO+ sites and PHT GO- sites) showed significantly higher scores of PBI and PI when compared with those of clinically healthy sites (all the p values were 0.0000). PBI scores at the PHT GO+ sites were also significantly higher than those of the PHT GO- sites ( $p = 0.03$ ).

The mean IL-1 $\beta$  value at the PHT GO+ sites was higher than those of the other groups (Fig. 1). PHT GO+ sites showed significantly higher levels of IL-1 $\beta$  compared to the healthy and gingivitis sites ( $p = 0.0009$ ,  $p = 0.049$  respectively). However, the difference was not statistically significant between the PHT GO+ and PHT GO- sites ( $p = 0.1159$ ). Moreover, IL-1 $\beta$  levels at the PHT GO- sites were significantly higher than those of the healthy sites

Table 1. Clinical values of the study groups.

Group	Age	GCF volume µl (2 samples)	PI	HI	PBI
Gingivitis	30.4±11	0.93±0.24	1.79±0.6	0.83±0.6	2.08±0.9
Healthy	30.8±9.5	0.26±0.17	0.2±0.4	0	0.1±0.05
PHT GO+	25.8±16.4	0.91±0.21***	1.73±0.5	2.06±0.1**	2.27±0.72*
PHT GO-	25.8±16.4	0.68±0.19	1 ±0.63	0.2±0.1	1.15±0.54

\* p=0.03 between PHT GO+ and PHT GO-, p=0.0000 between PHT GO+ and clinically healthy sites  
 \*\* p=0.000 between PHT GO+ and clinically healthy sites  
 \*\*\* For GCF volume all the differences were significant except that between PHT GO+ and gingivitis sites. p=0.0464 between PHT GO+ and PHT GO- sites.

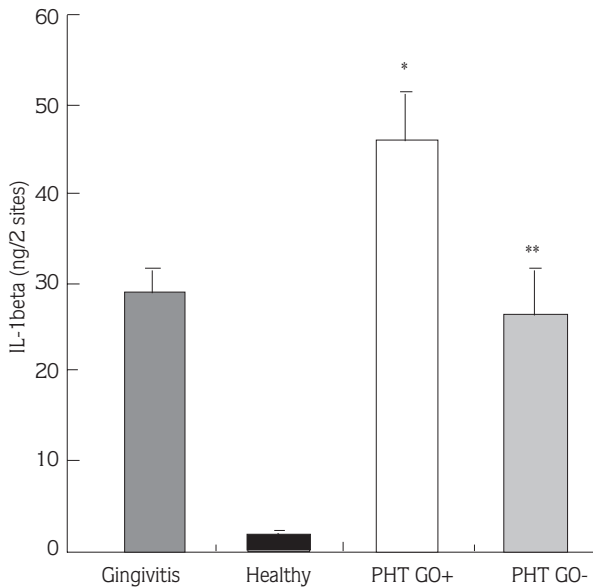


Figure 1. The amounts of IL-1β in the study groups (mean±standard deviation).

\* Significant differences between the PHT GO+ group and the gingivitis and healthy control groups (p=0.049, and p=0.0009 respectively).  
 \*\* Significant difference between the PHT GO- group and the healthy group (p=0.0009).

(p=0.0009), while they were similar to those of the gingivitis sites (p=0.8514). TNF-α values did not reveal any statistically significant difference between the four study groups (Fig. 2). The highest IL-6 levels were found at the gingivitis sites, followed by PHT GO+, PHT GO-, and healthy sites respectively (Fig. 3). Mean IL-6 levels were statistically different between the gingivitis and PHT GO- sites (p=0.0099), and between the PHT GO+ and healthy sites (p=0.0074). However, the differences

between the PHT GO+ and gingivitis sites (p=0.1740) and between the PHT GO+ and PHT GO- sites (p=0.0747) were not statistically significant. No correlation was found between PBI values and GCF cytokine levels in PHT-treated patients (p>0.05) (Table 2).

### Discussion

Drug-induced gingival overgrowth starts at interproximal sites. GCF, which is fundamentally a serum exudate, reflects the biochemical events in the interproximal tissues. Thus, in the present study, cytokine levels were analysed in GCF samples obtained from interproximal sites. The increase in GCF volume might result in a false decrease in cytokine concentration of GCF samples (20). Therefore, total GCF cytokine amounts per standard sampling time might be a better indicator of relative GCF constituent activity than GCF concentration (21). For this reason, the total amounts rather than the concentrations of cytokines were evaluated in this study. Considering the possible individual variability, the epileptic patients under PHT treatment who did not exhibit any PHT-induced gingival overgrowth were not included. Instead, GCF samples were obtained from sites not exhibiting gingival overgrowth in patients who had severe PHT-induced gingival overgrowth and made up one control group. The present preliminary study is to our knowledge the first report of an investigation of cytokine levels in the GCF of PHT-treated patients. Hence, we were unable to compare our data with similar studies.

In PHT-induced gingival overgrowth, a relative increase in the amount of proteoglycans along with a

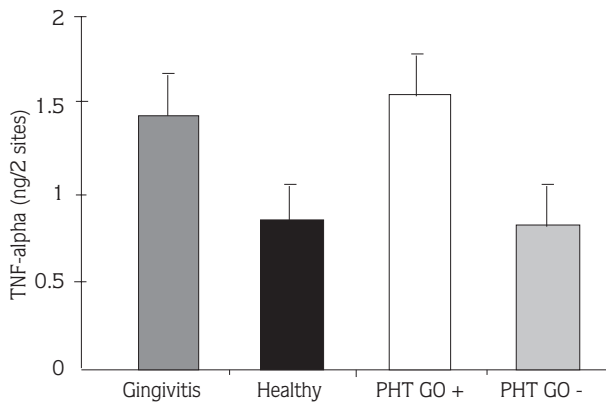


Figure 2. The amounts of TNF- $\alpha$  in the study groups (mean $\pm$ standard deviation). No significant difference was found between the study groups ( $p>0.05$ ).

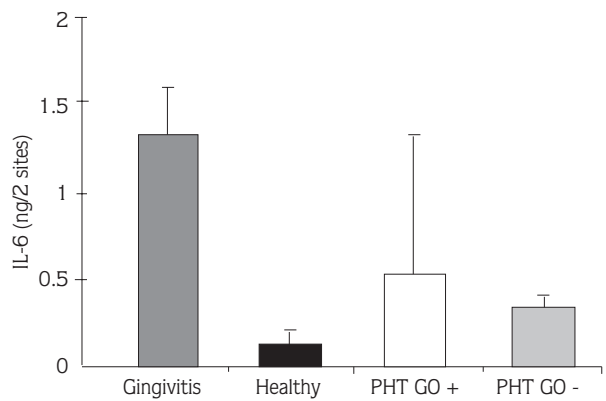


Figure 3. The amounts of IL-6 in the study groups (mean $\pm$ standard deviation). There were statistically significant differences between the PHT GO+ group and the healthy group ( $p=0.0074$ ), and between the PHT GO- group and gingivitis group ( $p=0.0099$ ). The differences between the PHT GO+ and the gingivitis group, and between the PHT GO+ and the PHT GO- group were not significant ( $p>0.05$ ).

Table 2. Correlations between the cytokine levels in GCF and PBI scores in PHT-treated patients.

	IL-1 $\beta$		TNF- $\alpha$		IL-6	
	r	p	r	p	r	p
PBI	0.273	0.389	0.298	0.346	0.427	0.165

No correlation was found between GCF cytokine levels and PBI scores in PHT-treated patients ( $p>0.05$ ).

relative decrease in collagen content is a characteristic finding (22). It is known that IL-1 inhibits procollagen I synthesis by fibroblasts and this inhibitory effect is potentiated by PHT (14). On the other hand, IL-1 induces non-collagenous matrix synthesis in gingival connective tissue (22). These interactions support the postulate that IL-1 $\beta$  may be an important component of PHT-induced gingival overgrowth. TNF- $\alpha$  has immunological and inflammatory effects similar to those of IL-1. Moreover, TNF- $\alpha$  induces IL-1 (12) and PGE<sub>2</sub> (13) synthesis by gingival fibroblasts and this effect is also potentiated by PHT. IL-6 is secreted in higher amounts in sites of inflammation and has biological influences on periodontal tissue destruction (2). Brunius et al. (23) have suggested that PHT-potentiated upregulation of IL-1 $\beta$  production in the presence of TNF- $\alpha$  may be important in the pathogenesis of drug-induced gingival overgrowth. In the present study, the GCF IL-1 $\beta$  and IL-6 levels at PHT GO+ sites were higher than those at the PHT GO- sites; hence our findings are in line with their report. This finding may contribute to an alteration in the composition of connective tissue. Iacopino et al. (5) did not find any increase in the level of IL-1 $\beta$  mRNA in the gingival tissues of PHT-treated patients exhibiting gingival overgrowth. They attributed this to the variability of macrophage phenotypes in various clinical conditions. In spite of the rather small number of patients in the PHT-induced gingival overgrowth group, the quantitative analysis of the present study implies a possible role of inflammatory cytokines in drug-fibroblast interactions. This has been suggested before by Seymour et al. (2) and our findings are consistent with their report.

In the present study, GCF cytokine levels were high at both PHT GO+ and PHT GO- sites, which exhibited varying degrees of clinical inflammation. However, we found higher level of IL-1 $\beta$  in PHT GO+ sites compared to the gingivitis sites, although they were similar in clinical inflammation. Furthermore, IL-6 levels were lower at the PHT GO+ sites than in the gingivitis sites. The high level of IL-1 $\beta$  in the PHT GO+ group may well be related also to the present inflammation. Nevertheless, since there was no correlation between PBI scores and GCF cytokine levels in PHT-treated patients, this increase cannot be solely explained by the gingival inflammation. It has been postulated that IL-6 functions as an inhibitor of cytokines, which stimulate fibroblastic activity (11). A recent study of ours revealed statistically low GCF IL-6 levels at

inflamed cyclosporine A GO+ sites compared to the gingivitis sites (24). It may be suggested that, similar to cyclosporine A, PHT causes a reduction in GCF IL-6 levels and thereby removes its inhibitory effect, and this reduction in GCF IL-6 level may be effective in the occurrence of PHT-induced gingival overgrowth.

The lack of a statistically significant difference between the PHT GO+ and PHT GO- groups with regard to the IL-1 $\beta$  and IL-6 levels may stem from the small number of cases present in these groups. Due to the limited number of PHT-induced gingival overgrowth cases, it was not possible to make a distinction with regard to the degree of gingival inflammation. Marked inter-individual variation in PHT pharmacokinetics (25) and fibroblast heterogeneity (26,27) may play a role in the pathogenesis of this side effect.

In conclusion, together with some other factors, the alteration of GCF IL-1 $\beta$  and IL-6 levels might act as cofactors for inducing gingival overgrowth in PHT-treated patients. The pathogenic mechanisms in the background of PHT-induced gingival overgrowth seem to

be complex and multifactorial. Comprehensive studies including more cases of PHT-induced gingival overgrowth may provide more information about the mechanism of drug-induced gingival overgrowth. A better understanding of the mechanism of this side effect may eventually lead to modification of drugs in this category and/or development of new alternatives which do not act in the same way. This side effect is extremely important for those patients who have to take PHT all their lives. If and when this side effect can be avoided, the patients will be able to achieve improved oral hygiene, better aesthetics, and more comfortable mastication.

*Correspondence author:*

*Nurcan BUDUNELİ*

*Department of Periodontology*

*Faculty of Dentistry*

*Ege University*

*35100 - Bornova, İzmir - TURKEY*

## References

- Hassell TM. Phenytoin: gingival overgrowth. In: Hassell TM ed Epilepsy and the oral manifestations of phenytoin therapy. S Karger, Basel, Switzerland, 1981: 116-137.
- Seymour RA, Thomason JM, Ellis JS. The pathogenesis of drug-induced gingival overgrowth. J Clin Periodont 1996; 23: 165-175.
- Foster R, Hassell TM. Response of single cell clones of human gingival fibroblasts to phenytoin in vitro. J Dent Res 1985; 64: 289.
- Dill RE, Miller EK, Weil T, Lesley S, Farmer GR, Iacopino AM. Phenytoin increases gene expression for platelet-derived growth factor B chain in macrophages and monocytes. J Periodontol 1993; 64: 169-173.
- Iacopino AM, Doxey D, Christopher WC, et al. Phenytoin and cyclosporine A specifically regulate macrophage phenotype and expression of platelet-derived growth factor and interleukin-1 in vitro and in vivo: possible molecular mechanism of drug-induced gingival hyperplasia. J Periodontol 1997; 68: 73-83.
- Dinarelli CA. Biology of interleukin-1. The FASEB Journal 1988; 2: 108-115.
- Smith JA, Mizel SB, Cohen D, Gree IRA. Interleukin 1, a potential regulator of fibroblast proliferation. J Immunol 1982; 128: 2177-2182
- Bartold PM. The effect of interleukin-1 $\beta$  on proteoglycans synthesised by human gingival fibroblasts in vitro. Connect Tissue Res 1988; 23: 287-304.
- Hirano T, Akira S, Taga T, Kishimoto T. Biological and clinical aspects of interleukin-6. Immunol Today 1990; 11: 443-449.
- Le J, Vilcek J. Interleukin-6: A multifactorial cytokine regulating immune reactions and the acute phase response. Lab Invest 1989; 61: 588-602.
- Vilcek J, Kohase M, Henriksen-DeStefano D. Mitogenic effect of double-stranded RNA in human fibroblasts: role of autogenous interferon. J Cell Phys 1987; 130: 37-43.
- Yücel-Lindberg T, Lerner UH, Modeer T. Effects and interactions of tumour necrosis factor  $\alpha$  and bradykinin on interleukin-1 production in gingival fibroblasts. J Periodont Res 1995; 30: 186-191.
- Modeer T, Brunius G, Iinuma M, Lerner UH. Phenytoin potentiates interleukin-1 induced prostaglandin biosynthesis in human gingival fibroblasts. Bri J Pharma 1992; 106: 574-578.

Are inflammatory cytokines potential mediators of phenytoin-induced gingival overgrowth?

14. Modeer T, Anduren I, Bengtsson A, Andersson G. Interleukin-1 $\beta$  and phenytoin reduce  $\alpha$ 1(I) procollagen mRNA expression in human gingival fibroblasts. *J Periodont Res* 1996; 3: 563-568.
15. Silness J, L e H. Periodontal disease in pregnancy II. Correlation between oral hygiene and periodontal condition. *Acta Odont Scand* 1964; 22: 121-135.
16. Saxer UP, M hleman HR. Motivation und aufklarung. *Sch MZZ* 1975; 85: 905-919.
17. Pernu HE, Pernu LM, Huttunen KR, Nieminen PA, Knuutila MLE. Gingival overgrowth among renal transplant recipients related to immunosuppressive medication and possible local background factors. *J Periodontol* 1992; 63: 548-553.
18. Angelopoulos AP, Goaz BS. Incidence of diphenyl-hydantoin gingival hyperplasia. *J Oral Surg* 1972; 34: 898-906.
19. Reinhardt RA, Masada MP, Johnson GK, DuBois LM, Seymour GJ, Allison AC. IL-1 in gingival crevicular fluid following closed root planing and papillary flap debridement. *J Clin Periodont* 1993; 20: 514-519.
20. Tsai CC, Ho YP, Chen CC. Levels of interleukin-1 beta and interleukin-8 in gingival crevicular fluids in adult periodontitis. *J Periodontol* 1995; 66: 852-859.
21. Lamster IB, Celenti RS, Jans HH, Fine JB, Grbic JT. Current status of tests for periodontal disease. *Adv Dent Res* 1993; 7: 182-190
22. Dahll f G, Modeer T, Reinholt FB, Wikstr m B, Hjerpe A. Proteoglycans and glycosaminoglycans in phenytoin-induced gingival overgrowth. *J Periodont Res* 1986; 21: 13-21.
23. Brunius G, Y cel-Lindberg T, Shinoda K, Modeer T. Effect of phenytoin on interleukin-1 $\beta$  production in human gingival fibroblasts challenged to tumour necrosis factor  $\alpha$  in vitro. *Eur J Oral Sci* 1996; 104: 27-33.
24. Atilla G, K t k ler N. Crevicular fluid interleukin-1 $\beta$ , tumour necrosis factor- $\alpha$ , and interleukin-6 levels in renal transplant patients receiving cyclosporine A. *J Periodontol* 1998; 69: 784-790.
25. McLaughlin WS, Ball DE, Seymour RA, Kamali F, White K. The pharmacokinetics of phenytoin in gingival crevicular fluid and plasma in relation to gingival overgrowth. *J Clin Periodont* 1995; 22: 942-945.
26. Ball DE, McLaughlin WS, Seymour RA, Kamali F. Plasma and saliva concentrations of phenytoin and 5-(4-hydroxyphenyl)-5-phenylhydantoin in relation to the incidence and severity of phenytoin-induced gingival overgrowth in epileptic patients. *J Periodontol* 1996; 67: 597-602.
27. Marshall RI, Bartold PM. Medication induced gingival overgrowth. *Oral Dis* 1998; 4: 130-151