

Zeliha KURTOĞLU
Haluk ULUUTKU

Bilateral Accessory Soleus Muscle

Department of Anatomy, Faculty of Medicine,
Black Sea Technical University, Trabzon-TURKEY

Received: June 15, 1999

A bilateral occurrence of the accessory soleus muscle (ASM) was encountered during lower extremity dissection of 20 newborn cadavers.

In the right leg, the muscle arose from the distal part of the anterior aponeurosis of the soleus muscle (SM).

Then it ran obliquely in a medial and inferior direction. ASM fibers did not contribute to SM fibers, and formed an independent tendon above the medial malleolus (Fig 1A). The smaller part of the tendon of the ASM attached to the calcaneus just anteromedial to the calcaneal tendon. While the greater part contributed to the flexor retinaculum, a branch from the tibial nerve and a branch from the posterior tibial artery entered the ASM at the upper third of this muscle (Figure 1B).

In the left leg, the ASM fibers also arose from the anterior aponeurosis of the SM, but at a higher level than in the other leg. As in the right leg, the fibers of the ASM did not contribute to the fibers of the SM. The ASM fibers formed a tendon just below the medial malleolus. The size of this muscle was greater than the right ASM. Its tendon was formed a lower level than that of the right one (Fig 2A). The greater posterior part of the tendon attached to the medial aspect of the calcaneus just antero medial to the attachment of the tendo calcaneus, while the smaller anterior part contributed to the flexor retinaculum (Fig 2B).

The nerve supply to this muscle came from a branch of the tibial nerve. The branch derived from the tibial nerve just below the origin of the SM perforated anterior

aponeurosis of this muscle and divided into two branches. While one branch entered the SM, the other branch ran downward and entered the ASM. The arterial branch to the ASM was derived from the posterior tibial artery, and reached the muscle at the upper third.

In addition to the ASM, the plantaris muscle was normally present in each leg.

The ASM is a rare variation in the human SM. Frohse and Frankel identified this anomalous muscle as a special plantaris muscle, the origin of which has migrated to the anterior surface of the SM or to the tibia (1). In the other studies, however, the plantaris muscle coexisted with the ASM (2,3). This muscle arises from the anterior surface of the SM instead of the femur. Therefore, this muscle has been regarded as a detached portion of the normal SM (2,4,5).

Del Sol et al. found 2 cases of ASM in 254 legs. In one of them, the ASM originated from the anterior aponeurosis of the SM and attached to the medial aspect of the calcaneus, as in the present case. The other was reported as originating from the SM and being inserted into the superior aspect of the calcaneus. The origin of the second one is different from that of the first and that of our case, being from the SM instead of the anterior aponeurosis. That case has been thought to lend support to the hypothesis of Le Double, Flower and Faller (2,4,5).

The ASM has also been reported by many clinicians. The muscle causes a soft swelling along the medial aspect of the calcaneal tendon. Yu and Resnick examined seven

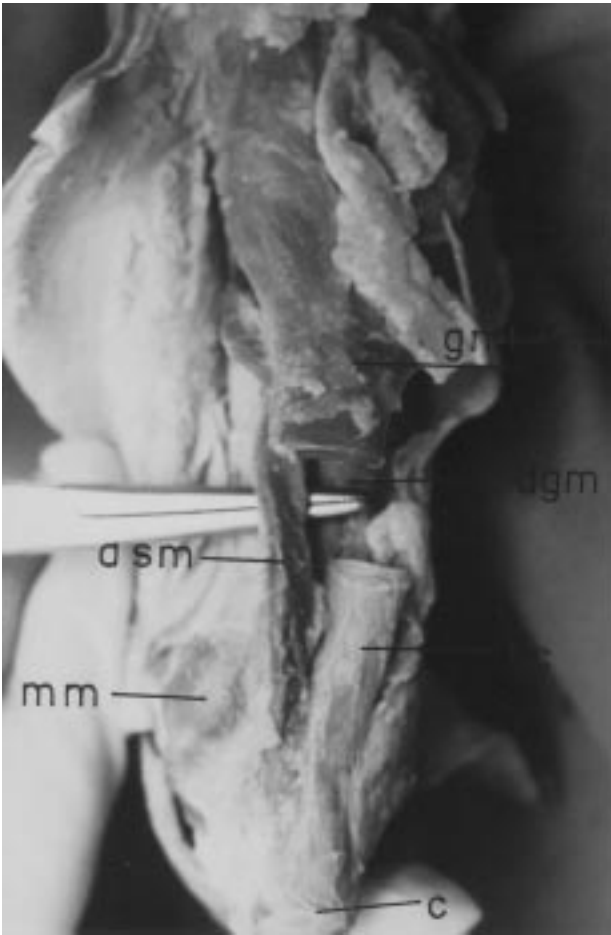


Figure 1A. Posterior view of the right leg with ASM. Gastrocnemius muscle and soleus muscle (gm+sm), deep group muscle (dgm), tendo calcaneus (tc), calcaneus (c), medial malleolus (mm), accessory soleus muscle (asm).

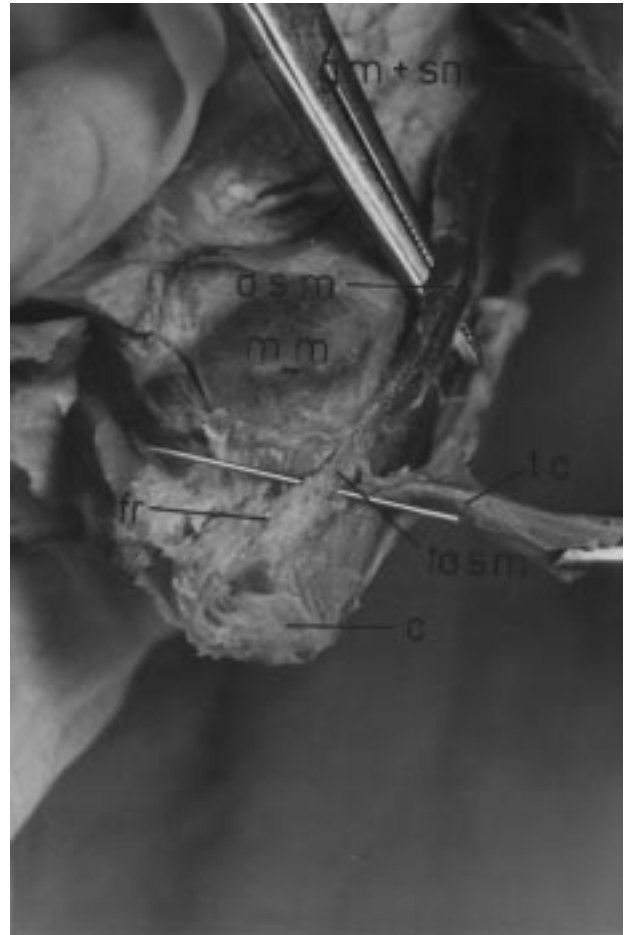

Figure 1B. Relationship between the calcaneal tendon and tendon of the right accessory soleus muscle. Gastrocnemius muscle and soleus muscle (gm+sm), tendo calcaneus (tc), calcaneus (c), tendon of the right accessory soleus muscle (tasm), medial malleolus (mm), accessory soleus muscle (asm), flexor retinaculum (fr).

ankles with an ASM by Magnetic Resonance Imaging. They suggested that this imaging method should be utilised for the non-invasive diagnosis of this muscle in patients suspected of having a mass or with persistent swelling in the region of the ankle.

The anomalous muscle sometimes presents with pain following exercise. The real cause of the pain is still obscure. The symptoms occur at puberty with a greater frequency in the male. It is considered that the sexual difference in the frequency of symptoms is based on the difference in muscular activity between the two sexes at adolescence (7).

Of 34 cases of ASM, Sekiya reported only 3 cases to be bilateral. It is clear that this variant muscle rarely

occurs bilaterally. Additionally, the right-left difference has been found to be negligible (3).

Consequently, the ASM should be kept in mind in cases of swelling located at the medial aspect of the ankle. Tarsal tunnel syndrome may also be caused by compression of terminal branches of the tibial nerve by ACM or its tendon attached to the flexor retinaculum. Leg pain, especially in the male adolescent, may be a result of ASM. The probability of a common nerve supply of the ASM and the SM should also be kept in mind in surgical approaches to the muscle, in case of paralysis of the bipenniform part of the SM.

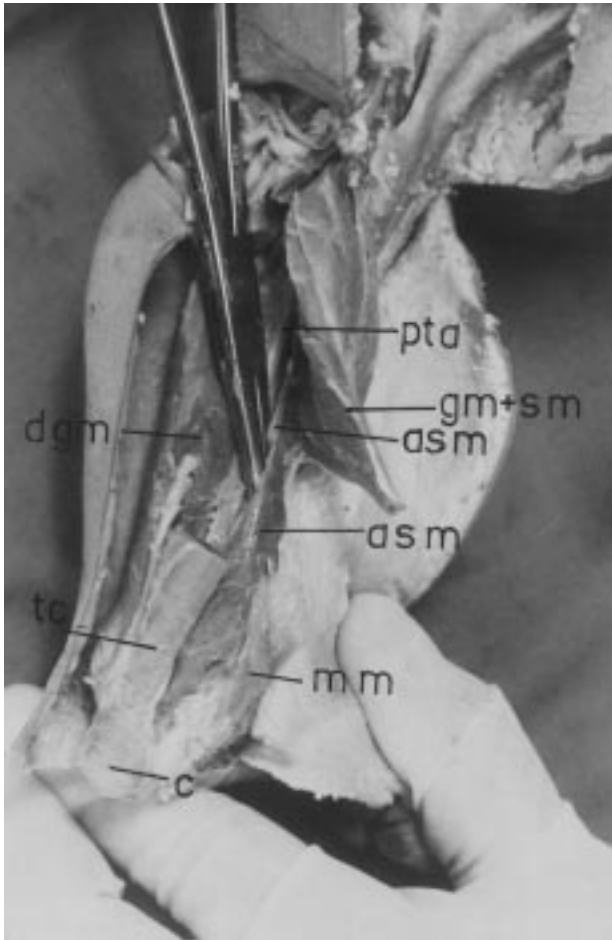


Figure 2A. Posterior view of the left leg with ASM. Gastrocnemius muscle and soleus muscle (gm+sm), posterior tibial artery (pta), accessory soleus muscle (asm), tendo calcaneus (tc), medial malleolus (mm), calcaneus (c), deep group muscle (dgm).

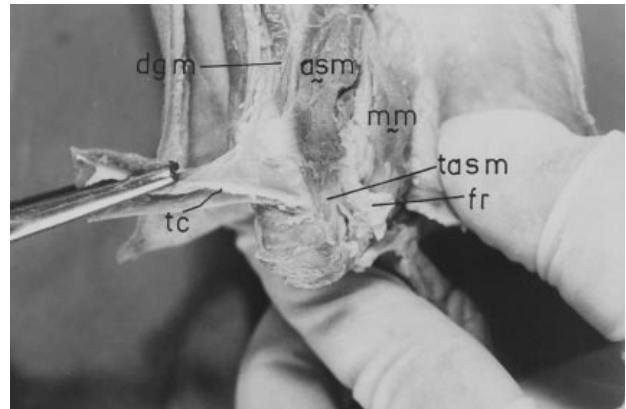


Figure 2B. Insertion of the right accessory soleus muscle. Accessory soleus muscle (asm), tendon of the right accessory soleus muscle (tasm), flexor retinaculum (fr), medial malleolus (mm), tendo calcaneus (tc), deep group muscle (dgm).

References

1. Frohse FM, Fränkel Die Muskeln des menschlichen Beines; in von Bardeleben, k. (Hrsg): Handbuch der Anatomie des Menschen. Jena, Gustav Fischer, II band, II Apt. Teil. Pp 415-693. 1913.
2. Le Double AF. Traité des variations du système musculaire de l'homme. Paris, Schleicher Frères, tome 2, pp 310-4. 1897.
3. Sekiya S, Kumaki K, Yamada TK, Horiguchi M. Nerve supply to the accessory soleus muscle. Acta Anat Nippon 149:121-7, 1994.
4. Faller A. Zur deutung der akzessorischen Köpfe des Schollenmuskels. Anat Anz 93:161-79, 1942.
5. Flower JM. Note on an accessory soleus muscle. J Anat 65:548-9, 1931.
6. Del Sol M, Junge C, Binignat O, Prates J, Ambrosito J. The accessory soleus muscle. Med. Chil. 117(6): 677-81, 1989.
7. Yu JS, Resnick D. MR imaging of the accessory soleus muscle appearance in six patients and a review of the literature. Skeletal Radiology. 23(7): 525-8, 1994.