

Yüksel GOKEL
Salim SATAR
Mehmet DURU
Zikret KOSEOGLU
Güven KUVANDIK

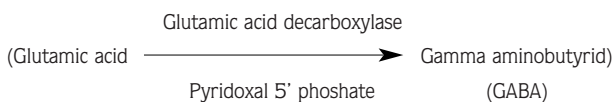
Isoniazid Poisoning with Seizures, Shoulder Dislocation, and Fracture of the Greater Tuberosity

Department of Emergency, Çukurova
University, Faculty of Medicine, Adana-Turkey

Received: January 4, 1999

Key Words: Isoniazid Poisoning, Seizure,
Shoulder Dislocation, Fracture

Isoniazid (INH) is now among the most common cause of drug induced seizures in the United States (1). In Turkey, where tuberculosis is seen in alarming proportions, patients who present to the Emergency Department (ED) with altered consciousness, agitation, seizures or coma, INH overdose should be scrutinized for. INH inhibits pyridoxal 5' phosphate, a cofactor for glutamic acid decarboxylase enzyme (2,3,4).



We here presented a 25 - year - old woman who took 6 grs of INH, with tonic-clonic seizures associated with shoulder swelling.

A 25-year - old woman was admitted to the ED with a history of drug overdose of unknown origin (twenty pills). On the way to the hospital, the patient had tonic-clonic seizures and became cyanotic. On arrival to the ED, the patient had a blood pressure of 130/80 mmHg., a pulse rate of 128/min., respiration rate of 30/min., and body temperature of 37.8 C°

Her skin was warm, and cyanotic; there were no head injuries but her right shoulder was swollen; the pupils were 3 mm bilaterally and reacted to light; the fundi were benign; her neck was supple and she responded to deep pain; oculocephalic reflexes were present. Reflexes were diffusely hyperactive, and bilaterally plantar extension was present. An intravenous line was inserted and a hundred ml of 30% Dextrose in water with 100 mg of thi-

amine were administered but there was no response. Because her gag reflex was absent, a cuffed endotracheal tube was inserted before gastric lavage was attempted. A 40 French orogastric tube was passed and the stomach was lavaged with 0.9% sodium chloride solution. Multiple doses of activated charcoal were given enterally. Shortly after this initial treatment, the patient had another generalized seizure, which lasted for 5 minutes till the administration of 10 mg diazepam intravenously (IV). Without regaining consciousness she had several more seizures.

A total of 500 mg phenobarbital was given intravenously but seizures persisted. Complete Blood Count and urinalysis were all within normal limits. She had a glucose level of 81 mg/dL, potassium of 4.2 mEq/L; sodium of 145 mEq/L; chloride of 105 mEq/L; SGOT of 48 IU/L and SGPT of 24 IU/L. Arterial blood gas showed: PH, 6.90; PCO₂, 32.2 mmHg; PO₂, 100 mmHg and HCO₃, 5.4 mEq/L. Sixty mEq HCO₃ was given by IV infusion. Later, her relatives found an empty bottle of INH at her home (it contains totally 6 grs of INH). Six grs of pyridoxine hydrochloride was given intravenously and seizures terminated abruptly. After this treatment she became conscious and she acknowledged taking pills for suicide. She had no further seizures. A right shoulder x-ray confirmed a shoulder dislocation with a fracture of the greater tuberosity. Closed reduction and sling and swathe immobilization was performed for her shoulder. We believe that the resulting dislocation and fracture were due to the seizures.

Since INH is absorbed rapidly, gastrointestinal evacuation and activated charcoal administration must not be delayed (5). Patients with seizures should immediately be given 1 grs of pyridoxine IV for each gram of INH ingested, at a rate of 1 grs every 2-3 minutes. If ingested INH dosage is unknown, a dose of 70 mg/kg pyridoxine should be administered. This dose could be repeated if seizures persist (6).

The administration of pyridoxine to a patient poisoned with INH, restores the deficiency of Gamma aminobutyric acid (GABA), and diazepam serves to sensitize the postsynaptic receptor to the action of GABA.

In conclusion, in patients who present to the ED with seizures, coma, and metabolic acidosis INH overdose should be considered. In this case, the empiric pyridoxin administration is justified and safe.

References

1. Bloch AB, Rieder HL, Kelly GD, Cauthen GM, Hayden CH, Snider DE. The epidemiology of TB in the U.S. : Implications for diagnosis and treatment. *Clin Chest Med* 10: 297 - 313, 1989.
2. Brent J, Vo N, Kulig K, Rumack BH. Reversal of prolonged isoniazid - induced coma by pridoxine. *Arch Intern Med.* 150: 1751 - 1753, 1990.
3. Saad SF, el Masry AM, Scott PM. Influence of certain anticonvulsants on the concentration of GABA in the cerebral hemispheres of mice. *Eur J Pharmacol* 17: 386 - 392, 1972.
4. Ehsan T, Malkoff MD. Acute çsoniasid poisoning simulating meningoencephalitis. *Neurology* 45(8): 1627-8, 1995.
5. Siefkin AD, Albertson TE, Corbett MG: Isoniazid overdose: Pharmacokinetics and effects of oral charcoal in treatment. *Hum Toxicol* 6: 497 - 501, 1987.
6. Bredeman JA; Krechel SW, Eggers GW. Treatment of refractory seizures in massive çsoniazid overdose. *Anesth - Analg* 71(5): 554-7, 1990.