

Zeliha KURTOĞLU
M. Haluk ULUUTKU

A Combined Variation of the Arteries and The Nerve in a Leg

Received: September 28, 1998

Department of Anatomy, Faculty of Medicine
Karadeniz Technical University, 61080,
Trabzon-Turkey

Abstract: During the dissection of an amputated leg, we discovered a combined variation involving the branching of the popliteal artery and tibial nerve. The popliteal artery showed a trifurcation pattern, and one of its branches, the posterior tibial artery, was hypoplastic. In addition, a small branch arising from the tibial nerve in the upper part of the leg distally crossed the peroneal artery and contributed to the medial plantar nerve.

In this article, such a case of embryonic origin is discussed, along with the clinical significance of these variations. The variant nerve and its relationship with the variant artery have not previously been described in the literature.

Key Words: 1. popliteal artery, 2. variation, 3. trifurcation pattern, 4. tibial nerve, 5. medial plantar nerve.

The popliteal artery is located in the popliteal fossa together with the tibial nerve and popliteal vein. All of these pass through the arcus tendinosus musculus soleus. The popliteal artery, firstly, gives rise to a branch, the anterior tibial artery, perforating the interosseous membrane and reaching the anterior compartment of the leg. Then, the popliteal artery is divided into two branches. One of these, the peroneal artery, courses laterally-downward, enters the flexor hallucis longus muscle and terminates into small branches that communicate with the anterior and posterior tibial artery at the level of the ankle joint. The other branch, the posterior tibial artery, descends along with the tibial nerve deep into the triceps surae muscle and passes deep into the flexor retinaculum (1-3). Sometimes this arrangement may be different because of developmental diversity (4-9).

In a 10 mm embryo, the primary artery of the lower extremity is the axial artery arising from the dorsal part of the embryonic umbilical artery. This artery passes through the greater sciatic foramen, elongates in the posterior part of the thigh, reaches the popliteal fossa and ends in a capillary plexus in the leg. (Because of its course, the axial artery is also called the sciatic artery). In a 14 mm embryo, the femoral artery, arising from the external iliac artery, reaches the popliteal fossa and makes an anastomosis with the sciatic artery in order to supply the distal part of the leg. After that, the middle part of

sciatic artery disappears, while the proximal part remains as the inferior gluteal artery, and the distal part constitutes the popliteal and peroneal arteries. The anterior tibial artery arises from the popliteal artery. The posterior tibial artery is formed by the distal part of the primitive femoral artery. Each of the embryonic arteries may either disappear or remain and unite abnormally (2, 10). Thus, many kinds of arterial variations occur in the leg. Trotter demonstrated a slight racial but no sexual difference in the arterial variations of the leg (11). In Keen's study, there was no right-left predominance of variants. He also found 27.5% of variants to be bilateral (6).

We also found out variations in the popliteal artery and tibial nerve. Amputation was performed on a 38-year-old female patient at the level of the hip joint because of malign B cell carcinoma in the distal ending of the left femur. The amputated leg was dissected in the laboratory. The popliteal artery was left the popliteal fossa and passed through the arcus tendinosus musculus soleus together with tibial nerve, as is normal. The gastrocnemius and soleus muscles were removed. Two variations were observed in the arterial arrangement. The first variation was that the popliteal artery had a trifurcation pattern. At a 65 mm distance from the tibial plateau the first branch, the anterior tibial artery, and at a 2 mm distance from that (at a 67 mm distance from the tibial plateau) the second branch, the posterior tibial

artery, arose from the popliteal artery (Figure 1). The branching of the popliteal artery into three arteries within 5 mm is called a trifurcation pattern. This description is similar to the present case, and is reported to have an incidence of 4% by Lippert and 2% by Kim (4, 5).

The second arterial variation was that posterior tibial artery was hypoplastic and ended in the distal part of the leg without reaching the flexor retinaculum. After arising from the truncus, the peroneal artery coursed the in lateral-distal direction and then entered among the flexor hallucis longus muscle's fibers. 50 mm proximal to the

lateral malleolus, this artery gave off a small branch, which went along lateral to the calcaneous, and its course changed to the medial side. Then this artery passed deep to the flexor retinaculum and divided into two branches, the medial and lateral plantar arteries (Figure 2). This type has been reported as 0.9-5% in different studies (12-15).

The peroneal artery normally terminates into small branches that communicate with the anterior and posterior tibial artery at the level of the ankle joint. In cases in which the proximal segments of the anterior

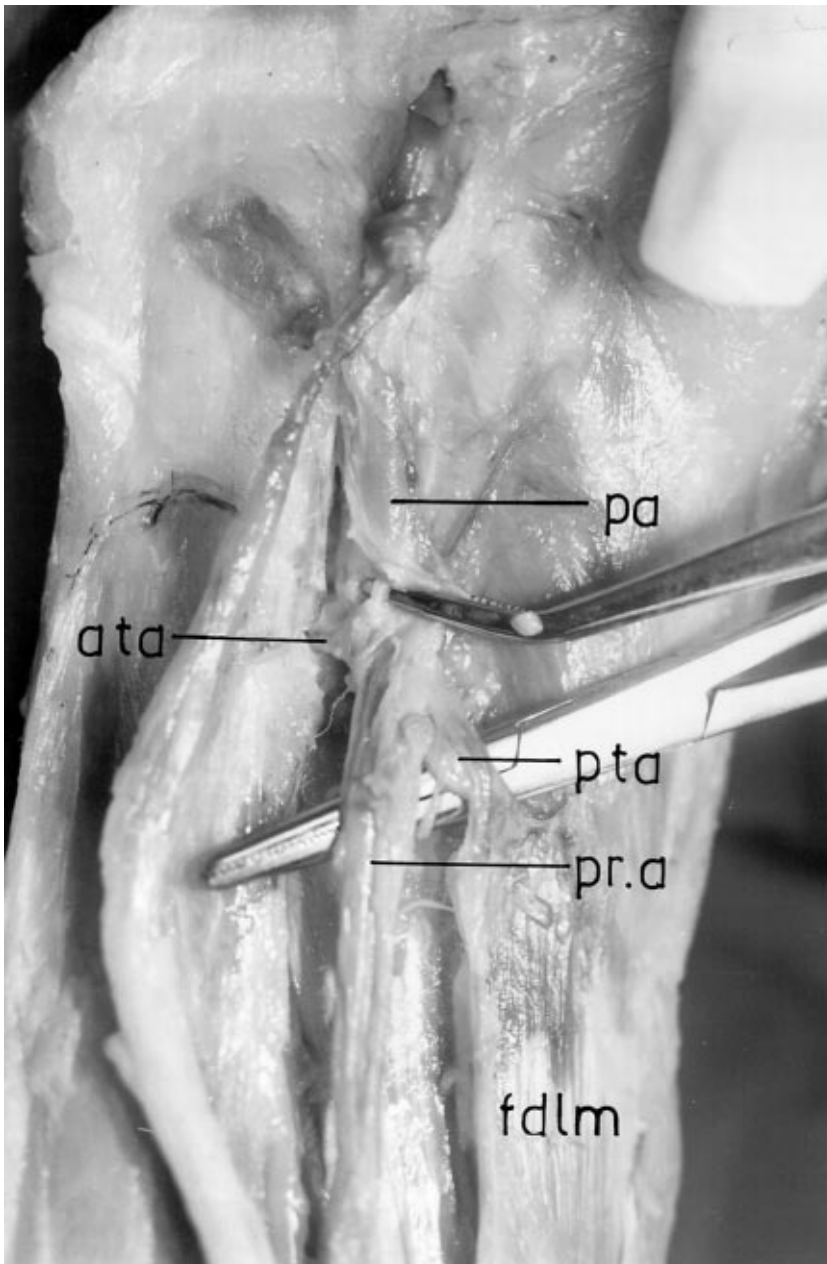


Figure 1. Showing trifurcation pattern.
pa: popliteal artery
pta: posterior tibial artery
pra: peroneal artery
fdlm: flexor digitorum longus muscle
ata: anterior tibial artery

and/or posterior tibial artery are congenitally absent or hypoplastic, the respective branch of the peroneal artery directly supplies their distal distribution areas (12-15). Thus it has been reported that the arterial variations mentioned above might influence the success of femoro-distal popliteal and tibial arterial reconstructions (5).

In addition, to acquire free vascularized fibular graft material, the arterial pattern of the leg was taken into consideration. When the posterior tibial artery is hypoplastic or aplastic and nutrition of the foot is supplied by perforating branches of the peroneal artery,

harvesting the fibula together with peroneal artery may endanger the nutrition of the foot. Rarely, a hypoplastic anterior tibial artery might be added to this picture. In this situation, surgeons carefully evaluate the surgical approach (4, 5). In the present case, the anterior tibial artery was of normal size and reached the dorsal aspect of the foot.

In our case, there was also an interesting variation concerning the tibial nerve. At about a 95-mm distance from the tibial plateau, anterior to the soleus muscle, a small branch derived from the tibial nerve and coursed

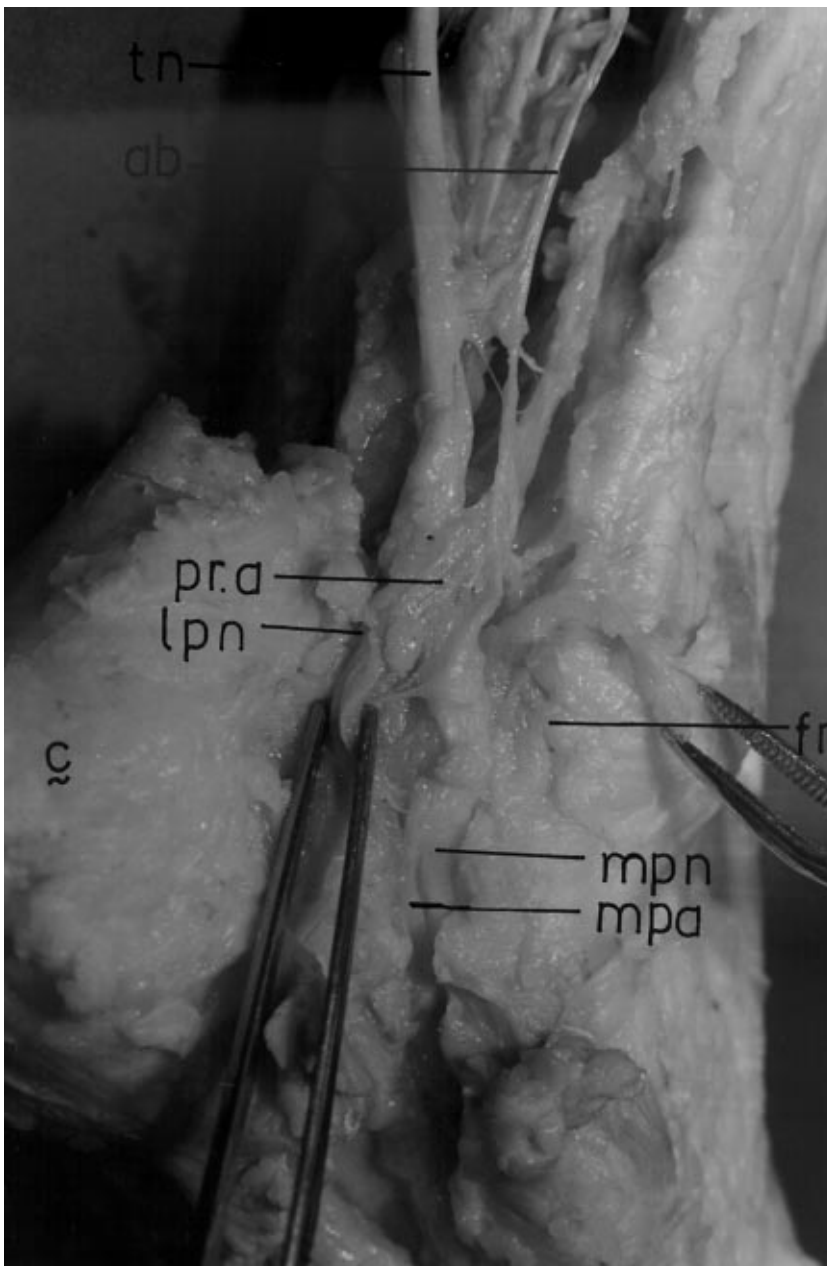


Figure 2. Showing relationship between the artery and the nerve in the distal part of the leg.
 fr: dissected flexor retinaculum
 mpn: medial plantar nerve
 mpa: medial plantar artery
 tn: tibial nerve
 ab: accessory branch of the tibial nerve
 pr.a: replaced peroneal artery
 lpn: lateral plantar nerve
 c: calcaneus

parallel to it. The peroneal artery, which changed its direction to the medial side in the distal part of the leg, passed between the tibial nerve and branch of the tibial nerve deep into the flexor retinaculum. The tibial nerve divided into two branches, medial plantar and lateral plantar nerve, as is normal. The branch of the tibial nerve contributed to the medial plantar nerve (Figs 2, 3). Horwitz reported the tibial nerve splitting off a highly medial and lateral plantar nerve by a small branch of the posterior tibial artery in 4 out of 100 cases (16). This

arrangement may be explained by a relationship relation between the capillary plexus and the developing nerves during embryonic development (2). The frequency of combined variations of arteries and nerves in the distal part of the leg does not appear in the literature. We suggest that if surrounding structures during development are taken into consideration, encountering similar variations is natural. This should be remembered in surgical approaches.

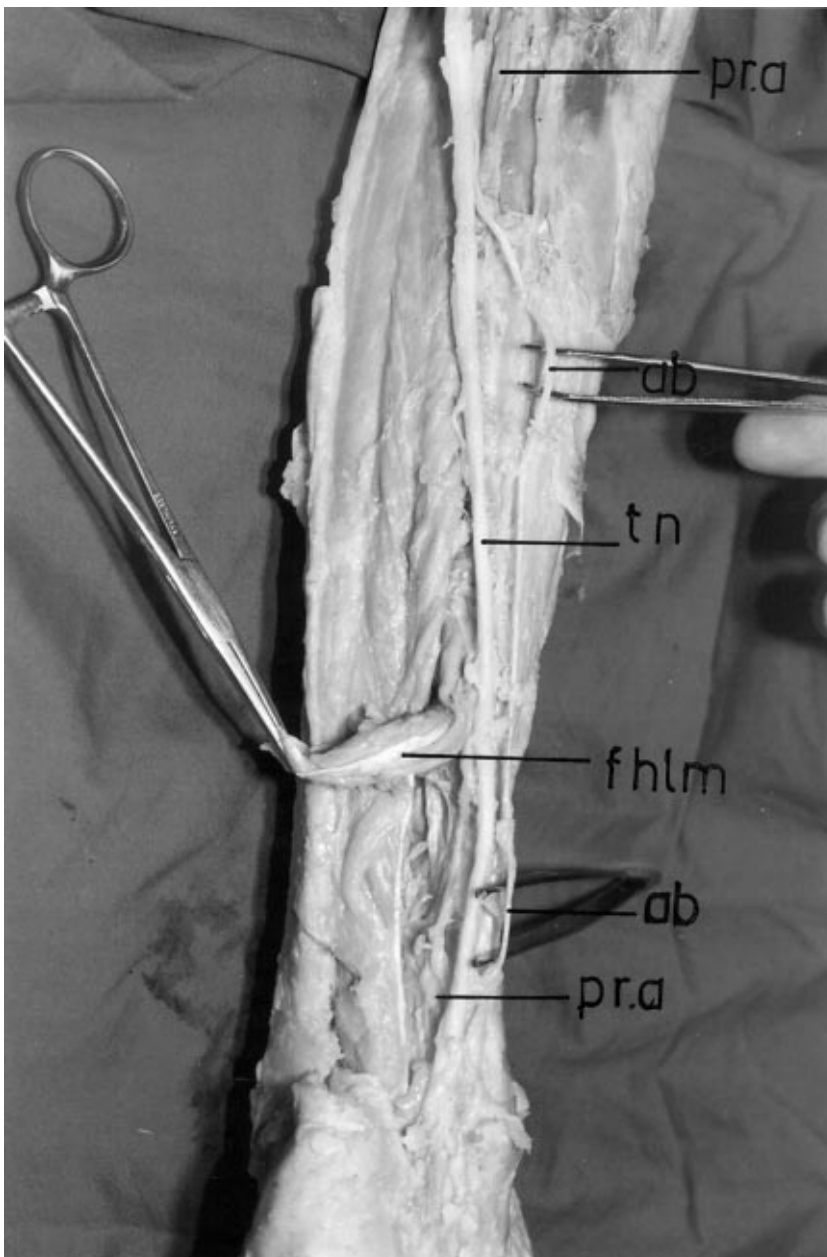


Figure 3. Showing localization of the accessory branch of the tibial nerve.
pr.a: peroneal artery
ab: accessory branch of the tibial nerve
tn: tibial nerve
fhlm: flexor hallucis longus muscle.

References

1. Moore KL. Clinically Oriented Anatomy, 3rd edition. Williams & Wilkins, Baltimore, U.S.A. pp: 412-20,1992.
2. Williams PL, Warwick R, Dyson M, Bannister LH. Gray's Anatomy, 38th edition. Churchill Livingstone, Edinburgh, pp. 785-790, 1284-87, 1995.
3. Brash JC. Cunningham's textbook of anatomy. 9th ed. London. Oxford Medical Publications, pp. 1375-76, 1953.
4. Lippert H, Papst R, Arteriel variations in man: classification and frequency. München: J.F. Bergmann Verlag, 1985.
5. Kym D, Orron DE, Skyllman JJ. Surgical significance of popliteal arteriel variants: a unified angiographic classification. Ann. Surgery, 210:776-81, 1989.
6. Keen JA. A study of the arterial variations in the limbs with special reference to symmetry of vascular patterns. Am J Anat, 108:245-61, 1961.
7. Bartsley JL, Stable TW. Variations in branching of the popliteal artery. Radiology, 94:581-87, 1970.
8. Adachi B. Das arterien system der Japaner, vol. II Kyoto: Maruzen 1928.
9. Senior HD. The development of the arteries of the human lower extremity. Am J Anat 25:55-94, 1919.
10. Mauro MA Jacques PF, Moore M. The popliteal artery and its branches: Embriological basis of normal and variant anatomy. AJR, 150:435-37, 1988.
11. Trotter M. The level of termination of the popliteal artery in the white and the negro. Am J Phys Anthropol, 27:109-18, 1940.
12. Haimovici H. Vascular Surgery Principles and Techniques. In: Callow AD DePalma RG, Ernst CB, Hollier LH. Arteriographic patterns of atherosclerotic occlusive disease of the lower extremity. Third ed. California: Appleton & Lange, 409-30, 1989.
13. Manaster BJ, Coleman DA, Bell DA. Magnetic resonance imaging of vascular anatomy before vascularized fibular grafting. The Journal of Bone and Joint Surgery, 72/3:409-14, 1990.
14. Yamada T, Gloviczki P, Bower T, Naessens JM, Carmichael SW. Variations of the arterial anatomy of the foot. The American Journal of Surgery, 166:130-5, 1993.
15. Morris GC, Beall AC, Berry WB, et al. Anatomical studies of the distal popliteal artery and its branches. Surg Forum, 10: 498-502, 1961.
16. Horwitz MT. Normal anatomy and variations of the peripheral nerves of the leg and foot. Archives of Surgery, 1938; 36: 626-36.