

Sülen SARIOĞLU
Alp KILIÇALP
Aydanur KARGI

Hodgkin's Disease and Epstein-Barr Virus Infection: Phenotypical Features

Received: May 28, 1997

Abstract: The purpose of this study is to investigate the presence of Epstein-Barr Virus (EBV) infection, phenotypical features and proliferative activity in Hodgkin's Disease (HD) for both the reactive and neoplastic cell populations.

Sections from 4 lymphocyte predominance (LP), 13 nodular sclerosis (NS), 10 mixed cellularity (MC), total 27 HD tissue blocks were stained by avidin biotin complex method using primary antibodies against latent membrane protein-1 (LMP-1), epithelial membran antigen (EMA), leukocyte common antigen (LCA), CD20, CD43, UCHL-1, S100, proliferating cell nuclear antigen (PCNA) and diaminobenzidine (DAB) was used as chromogen. Also double immunostaining was performed in 5 cases using avidin-biotin complex method and DAB chromogen for LMP-1 and amino ethyl carbazole (AEC) chromogen for S 100 protein for identifying LMP-1 expression by dendritic reticular cells. Number of PCNA positive HRS cells among

100 neoplastic cells and percentage of LCA, CD20, CD43, UCHL-1 positive reactive cells were compared for LP, NS, MC cases by Mann Whitney U Test. Also by the same method and for the described groups, LMP-1 positive and negative cases were compared.

Of 27 HD cases 21 (77.77%) were positive by LMP-1, in the cytoplasm of Hodgkin-Reed Sternberg (HRS) cells. HRS cells were CD20 positive in one LPHD, while all HRS cells in this and other cases were negative for EMA, LCA, CD20, CD43, UCHL-1 and S 100. PCNA was positive in 79-100% of HRS cells, without significant difference for HD subtypes. Number of PCNA positive cells were more for LMP-1 positive cases. LMP-1 expression was not identified in dendritic-reticular cells. These findings provides additional data but phenotypical features of the disease are still controversial.

Key Words: Hodgkin's Disease, EBV, LMP-1, phenotype.

Department of Pathology, Faculty of Medicine,
Dokuz Eylül University, Inciralti, Izmir-Turkey

Introduction

Hodgkin's disease (HD) is among the Epstein-Barr virus (EBV) associated neoplasia. There are several methods for identifying EBV infection, one of which is detecting EBV antibodies in the sera of patients (1). But this method provides only indirect evidence, because many other diseases may be associated with EBV infection as nasopharyngeal carcinomas, Burkitt's lymphomas, peripheral T cell lymphomas, gastric carcinomas, smooth muscle tumors in pediatric patients with immunodeficiency states and an increasing number of diseases (1-9).

Immunohistochemistry (IHC) is the other choice, with a number of primary antibodies for detection of EBV antigens in tissue sections (10). EBV infection can be demonstrated by DNA extraction and polymerase chain reaction (PCR) amplification, DNA in situ hybridization

(ISH) or RNA ISH from tumor tissue which provides direct evidence (10, 11). The aim of the present study is to characterize the phenotype of HD and document the EBV infection by IHC using an antibody against latent membrane protein-1 (LMP-1) and search for the correlation between EBV related antigen expression and phenotypical characteristics of Hodgkin-Reed Sternberg (HRS) cells including expression of B and T lymphocyte markers (CD43, UCHL-1, CD20), epithelial membrane antigen (EMA), leukocyte common antigen (LCA), proliferating cell nuclear antigen (PCNA) and S 100 protein. In a group of patients, double immunostaining was performed for detection of EBV antigens in S 100 stained interdigitating reticulum cells (IRCS) and follicular dendritic cells (FDCs). Proliferative activity of the tumors were also evaluated by IHC.

Materials and Methods:

Patient Population:

27 patients with HD were chosen from the files of the Department of Pathology at Dokuz Eylül University School of Medicine from 1990 to 1997. Patients were subtyped according to the Rye classification. Of those, 13 were nodular sclerosis (NSHD), 10 were mixed cellularity (MCHD) and 4 were lymphocytic predominant (LPHD) variant (Table 1).

Histopathologic and IHC studies:

Five micron sections from formalin fixed paraffin embedded tissue blocks were placed on 3-aminopropyltriethoxylene (APES) coated slides. Primary monoclonal antibodies against CD43 (dil: 1/100), UCHL-1 (CD45RO, dil: 1/100), CD20 (L26, dil: 1/100), EMA (dil: 1/100), LCA (CD45RB, dil: 1/100), S100 protein (dil: 1/300), PCNA (clone 10, dil: 1/100), LMP-1 (dil: 1/75, with citric acid predigestion) was applied to 26 cases along with positive control sections. All primary antibodies were purchased from Dakopatts (Glostrup, Denmark) Streptavidin biotin method was applied (Histostain Broad Spectrum Kit, Zymed Laboratories, San Fransisco, USA). After deparaffinization and blocking serum for 30 minutes along with positive controls for each antibody. Then they were incubated in primary antibody for 30 minutes without a prior stirring in phosphate-buferred saline solution and incubated in secondary biotinylated antibody for 30 minutes. DAB was used as chromagen and counterstaining was performed with Mayer's hematoxylin. For CD43, UCHL-1, CD20, EMA, LCA, S100 and LMP-1 cytoplasmic staining and for PCNA nuclear staining with brown color was accepted as positive result. For LMP-1 immunostaining, after deparaffinization and blocking endogenous peroxidase with 3% H2O2, slides were immersed in citric acid solution (pH: 6.0) in a plastic war. The jar was placed in a household microwave oven for 10 minutes at full power. Streptavidin-biotin method as described above was applied afterwards.

IHC study for LMP-1 and S100 dual staining:

For 5 selected cases dual immunostaining with LMP-1 and S100 was performed. Slides were incubated in blocking serum for 10 minutes, in primary antibody (LMP-1, dil: 1/75) for 60 minutes and in secondary biotinylated antibody for 10 minutes and streptavidin biotin method was applied (Histostain Broad Spectrum Kit, Zymed Laboratories, San Francisco, USA). DAB was used as chromogen and counterstaining was performed.

A second procedure with S100 antibody using streptavidin biotin method was applied (Multi-Species Ultra Streptavidin Detection System, Zymed Laboratories, Massachusetts, USA). Slides were incubated in blocking serum for 30 minutes, in primary antibody for 30 minutes and in secondary biotinylated antibody for 30 minutes. AEC (Amino ethyl carbazole) was used as chromogen in this step. LMP-1 positive cells stained brown and S100 positive cells stained red.

Evaluation:

All sections were observed by light microscopy. Cases with LMP-1 positive HRS cells were identified (Figure 1). Double immunostained sections for S100 and LMP-1 proteins were evaluated for finding cells with both brown and red staining, but it couldn't be demonstrated (Figure 2). For determining the proliferative activity in HD cases, 100 HRS cells were counted in each case and positive ones were noted. For LP subtype cases serial sections were used, because of the paucity of the HRS cells. Reactive cell population was also observed for expression of all the described primary antibodies. Percentage of LCA, CD20, CD43, UCHL-1 positive reactive cell population were assessed subjectively.

Statistical Analysis:

In order to compare the reactive cell population in HD subtypes, for the percentage of LCA, CD20, CD43 and UCHL-1 positive cases Mann-Whitney U Test was performed. LMP-1 positive and negative cases were compared for the expression of LCA, CD20, CD43 and UCHL-1 by the reactive cell population and for PCNA expression by HRS cells by Mann Whitney U Test.

Hodgkin's disease subtypes	Number of cases	percentages
lymphocyte predominant	4	14.81
nodular sclerosis	13	48.15
kixed cellularity	10	37.03
total	27	100.00

Table 1. The distribution of the cases according to the Hodgkin's disease subtypes.

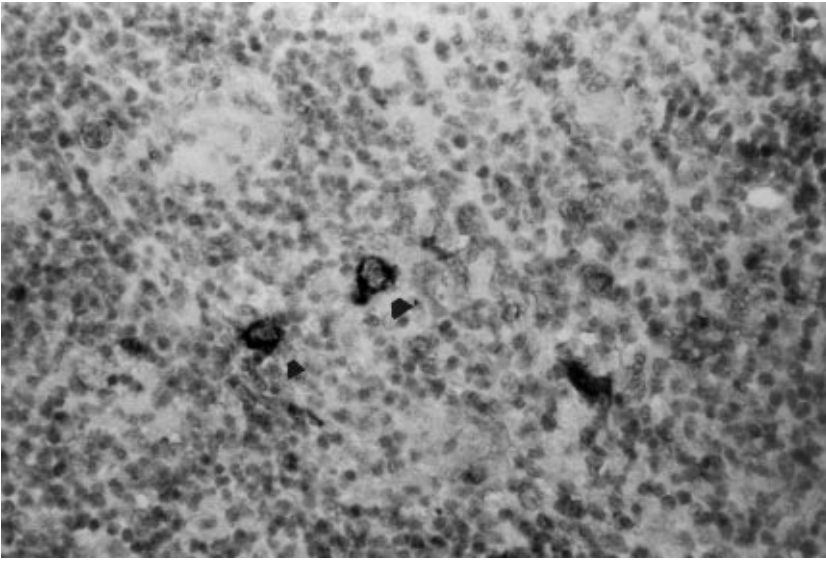


Figure 1. LMP-1 positive HRS cells in HD (ABC method, DAB chromogen X20).

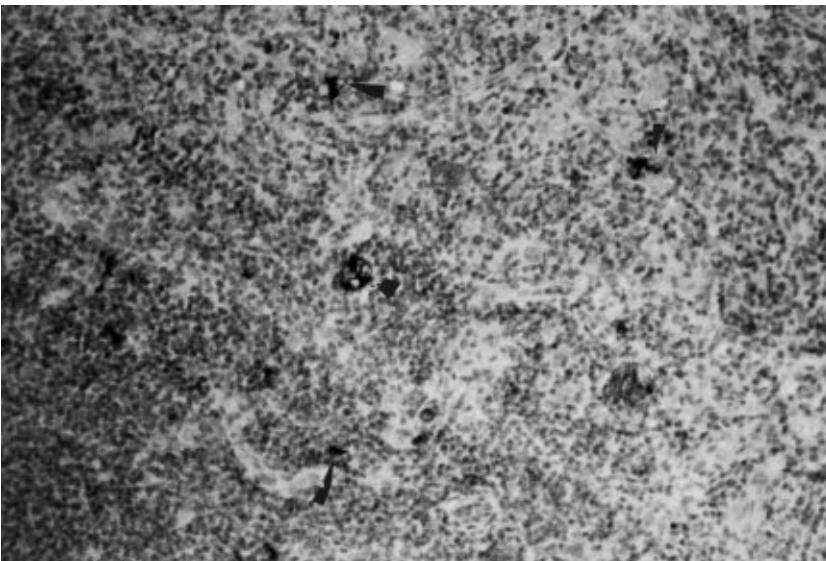


Figure 2. Dual immunostaining with LMP-1 and S 100. LMP-1 positive HRS cells are brown and S 100 positive follicular dendritic cells are red (ABC method with chromogens DAB and AEC, X20).

Results

HRS cells were negative with CD43, UCHL-1, EMA, LCA in 27 cases. CD20 was positive in the HRS cells of only one case which was of LP subtype. UCHL-1 and CD43 were positive in 40% to 90% of the reactive cell population, while CD20 was positive in 15% to 50% of the reactive cell population. CD43 and UCHL-1 expression were not different for HD subtypes, while LCA expression was more for NSHD compared to LPHD (0.01) and CD20 expression was more for NSHD compared to LPHD cases

($p=0.04$). IRCs/FDCs were S100 positive and in some areas they formed small clusters. An increased concentration of S100 positive IRCs/FDCs were noted adjacent to HRS cells. Nuclear PCNA positivity was noted in 79% to 100% of HRS cells. Percentage of PCNA positive cells for LP, NS and MCHD cases were 63 to 98 (mean 82.5), 79 to 100 (mean 93.9) and 79 to 100 (mean 92, 77) respectively. Number of PCNA positive cells for LPHD and NSHD ($p=0.13$), NSHD and MCHD ($p=0.81$) or MCHD and LPHD ($p=0.18$) were not different statistically.

Hodgkin's disease subtypes	number of LMP-1 positive cases/total cases	percentages
lymphocyte predominant	3/4	75
nodular sclerosis	9/10	90
mixed cellularity	9/13	69.2
total	21/27	77.78

Table 2. LMP-1 positivity rates of the cases.

LMP-1 expression was found in 21 (77.78%) of the 26 cases. Of those, 9 were NSHD (69.2%), 9 were MCHD (90%) and 3 were LPHD (75%) and staining was exclusively cytoplasmic (Table 2).

PCNA expression was significantly different for LMP-1 positive and negative cases ($p=0.26$) concordant with increased PCNA positivity for LMP-1 positive cases.

As an increased number of IRCs/FDCs were observed surrounding HRS cells, a search for EBV expression in these cells, which may be a major source of EBV particles, in addition to B lymphocytes was performed. For detection of LMP-1 expression in IRCs/FDCs 2 NSHD, 2 LPHD and 1 MCHD were chosen. For none of the cases, S100 positive IRCs/FDCs were positive by LMP-1, supporting the notion that LMP-1 is not expressed by DR cells.

Discussion

EBV is a member of human Herpes virus family and causes a persistent infection in the host. For the infection of oropharyngeal epithelium, the cells should have CD21 or CR2 specific receptor. EBV, then infects B lymphocytes through the same receptor on B lymphocytes and the virus disseminates to the other tissues (12, 15).

CD4+helper T lymphocytes and natural killer cells form a primary immune response to the infected B lymphocytes by targeting EBV nuclear antigens (EBNAs) and LMPs (12). Later a secondary immune response occurs, mediated by HLA-restricted CD8+cytotoxic T lymphocytes for the life of host until a deficiency in the immune system occurs (12).

EBV genome encodes more than 100 genes, but only 9 of them are expressed as proteins in B lymphocytes. Six of them encode EBNAs and 3 of them encode LMPs. LMP-1 is a potent oncogene in rodent fibroblasts and epithelial cells (4-7). In vitro, LMP-1 delays apoptosis in B lymphocytes by inducing the bcl -2 gene (8).

Demonstration of EBV infection may be achieved by DNA extraction PCR amplification (11), DNA or RNA ISH from tumor tissue (10), IHC or by serology (16). While demonstration of EBV infection by IHC alone does not

give reliable results compared with molecular methods considering nasopharyngeal carcinomas (16), better results have been achieved for Hodgkin's disease (13). Delsot et al. (14) reported a correlation of 91% between ISH and IHC results while Tomita et al. (10) reported a correlation of 93% considering HD cases. Therefore, IHC may be accepted as a method for screening EBV infection for HD.

The association of EBV with HD in different populations is highly variable being 30% to 50% in western countries and nearly 100% in developing countries (13). In Japan, Malaysia, Hong Kong and South Korea ISH studies demonstrated a positivity for EBV in 56%, 61%, 66% and 69% of the HD patients, respectively (10-13, 17). Our IHC results show a positivity of 77.78% for LMP-1, an incidence intermediate between eastern and western countries.

Interdigitating reticulum cells (IRCs) and follicular dendritic cells (FDCs) are the main antigen presenting cells in the lymph nodes (18). Demonstration of the S 100 protein by IHC method is a highly sensitive marker for IRCs and FDCs (19). In this study, S 100 IHC stain revealed numerous IRCs/FDCs around the HRS cells. This observation made us to wonder whether LMP-1 protein is expressed on IRCs/FDCs or not. Our results only indicate that LMP-1 is not expressed by IRCs/FDCs. But is not enough to reach to a conclusion about the manner EBV affects IRCs/FDCs as it is known that LMP-1 expression is different for cell types even if they are infected by EBV (10, 14, 16). Van Gorp et al (20) reported LMP-1 expression in FDCs in residual germinal centers in 2 HD cases, but these results does not provide direct evidence as the cells were restricted to the residual germinal centers.

PCNA is an acidic nuclear protein with a molecular weight of 36 Kd and preferentially synthesized during the S phase of the cell cycle. Studies correlating Ki 67 proliferation index with PCNA positivity suggests that PCNA positivity is a reliable marker of cell proliferation (21). Two different studies about the staining pattern of HRS cells with PCNA reported a high percentage of staining (22, 23). In this study, 79% to 100% of the

HRS are stained positively with PCNA, suggesting that HRS cells have a high proliferative activity. But there was no correlation between the subtype of HD. In this study statistically significant results were obtained for LMP-1 positive and negative cases considering PCNA expression, concordant with increased proliferative activity for LMP-1 positive cases. As the number of the LMP-1 negative cases is small, this finding should be investigated in larger series with different proliferation associated protein expressions.

Immunophenotypic studies identified intracytoplasmic and surface localized B and T lymphocyte markers in HRS cells (24). Also data from the molecular analysis of HD derived cell lines showing clonal rearrangements of immunoglobulin and T lymphocyte antigen receptor (TcR) support the hypothesis of a lymphocytic origin of the HRS cells (5, 24). Zukerberg et al (25) showed that at least

some cases of HD except LDHD expressed CD15 or CD20 and in some cases both of the two.

In our study HRS cells did not stain by any of the markers CD43, UCHL-1 or LCA. Only in one case of LPHD, HRS cells were stained with CD20. Reactive cell population in Hodgkin's disease has always been interesting. It is suggested that the reactive cell population is influenced by the cytokine expression by the HRS cells (26). Our results suggest differences in reactive cell population considering LCA and CD20 expression considering HD subtypes, but as the series is small and method of evaluation is subjective it is hard to reach strict conclusions. Although LMP-1 expression could not be demonstrated in IRCs/FDCs, we believe that observation of increased number of IRCs/FDCs surrounding HRS cells merits further investigation in larger series as to their relation to pathogenesis in HD.

References

1. Henle G, Henle W. Epstein-Barr virus-specific Ig A serum antibodies as an outstanding feature of nasopharyngeal carcinoma. *Int Jb Cancer* 17: 1-7, 1976.
2. Tamada A, Matimoto K, Yamabe H, Imai J, Hinuma Y, Oyagi A. Titers of Epstein-Barr virus related antibodies in nasopharyngeal carcinoma in Japan. *Cancer* 53: 430-40, 1984.
3. Pearson GR, Weiland LH, Nell B. Application of Epstein-Barr virus (EBV) serology to the diagnosis of North American nasopharyngeal carcinoma. *Cancer* 51: 260-68, 1983.
4. Ringborg U, Henle W, Ingimasson S, Ingimarsson S, Klein G, Silverword C. Epstein-Barr virus-specific serodiagnostic tests in carcinomas of the head and neck. *Cancer* 52: 1237-43, 1983.
5. Chen WG, Chen YY, Bachi MM. Genotyping of Epstein-Barr virus in Brazilian Burkitt's lymphoma and reactive tissue. *Am J Pathol* 148: 17-23, 1996.
6. Su JJ, Hsieh NE, Lin KH, et al. Aggressive Peripheral T-cell lymphomas containing Epstein Barr viral DNA: a clinicopathologic and molecular analysis study. *Blood* 77: 799-808, 1991.
7. Shin WS, Kang JH, Uen WC, Koa CL, Chen CJ. Epstein Barr virus associated gastric adenocarcinomas among Koreans. *Am J Pathol* 105: 174-81, 1996.
8. Mc Clain KL, Leach CT, Jenson BH, Joshi VV, Pollock HB, Panmley RT. Association of Epstein-Barr virus with leiomyosarcoma, sections as in children with AIDS. *N Engl J Med* 332: 12-18, 1995.
9. Lee ES, Locker J, Nalensnik M, Reyes J, Jaffe R, Alashari M. The association of Epstein-Barr virus with smooth muscle tumors occurring after organ transplantation. *N Eng J Med* 332: 19-25, 1995.
10. Tomita Y, Ohsawa M, Kanno H. Epstein-Barr virus in Hodgkin's disease patients in Japan. *Cancer* 77: 186-92, 1996.
11. Huh J, Park C, Juhng S. A pathologic study of Hodgkin's disease in Korea and its association with Epstein-Barr virus infection. *Cancer* 77: 949-55, 1996.
12. Liebowitz D. Epstein-Barr virus: an old dog with new tricks. *N Eng J Med* 332: 55-57, 1995.
13. Chan JKC, Yip TTC, Tsangw Y, Lou WH, Wong CS. Detection of Epstein-Barr virus in Hodgkin's disease occurring in an oriental population. *Hum Pathol* 26: 314-18, 1995.
14. Delsol G, Brousset P, Chittal S, Rigal-Huguet F. Correlation of the expression of Epstein-Barr virus latent membrane protein and in situ hybridization with biotinylated BamHI-W probes in Hodgkin's disease. *Am J Pathol* 140: 247-53, 1992.
15. Fingerroth JD, Weiss JJ, Tedder TF, Strominger JL, Biro DA, Feoran DT. Epstein-Barr virus receptor of human B lymphocytes is the C3d receptor CR2. *Proc Natl Acad Sci USA* 81: 4510-16, 1984.

16. Stewart JP, Arrand JR. Expression of the Epstein-Barr virus latent membrane protein in nasopharyngeal carcinoma. *Cancer* 51: 260-68, 1983.
17. Looi LM, Peh SC, Pallesen G. Epstein-Barr virus (EBV) and Hodgkin's disease in a multi-ethnic population in Malaysia. *Histopathology* 30: 227-233, 1997.
18. Foucar K, Foucar E. The mononuclear phagocyte and immunoregulatory effector (M-PIRE) system: evolving concepts. *Semin Diagn Pathol* 7: 4-18, 1990.
19. Carbone A, Manconi R, Volpe R, Santi L. Demonstration of S 100 protein distribution in human lymphoid tissues by the Avidin Biotin complex immunostaining method. *Hum Pathol* 16: 1157-64, 1985.
20. Van Grop J, Jacobse KC, Broekhuizen R, Alers J, van de Tweel JG, de Wager RA. Encoded LMP-1 of EBV on follicular dendritic cells in residual germinal centers in Hodgkin disease. *J Clin Pathol* 47: 29-32, 1994.
21. Schmid C, Sweeney E, Isaacson PG. Proliferating cell nuclear antigen (PCNA) expression in Hodgkin's disease. *J Pathol* 168: 1-6, 1992.
22. Hell K, Lorenzen J, Hansman ML, Fellbaum C, Busch R, Fisher R. Expression of the proliferating cell nuclear antigen in different types of Hodgkin's disease. *Am J Clin Pathol* 99: 598-603, 1993.
23. Freeman J, Kellock DB, Yu CC, Crocker J, Levison DA, Hall PA. Proliferating cell nuclear antigen (PCNA) and nuclear organising regions in Hodgkin's disease. *J Clin Pathol* 46: 446-9, 1995.
24. Knecht H, Odermatt FO, Bachmann E, Teixeira S, Sahli R, Hayaz D. Frequent detection of Epstein-Barr virus DNA by polymerase chain reaction in lymph node biopsies from patients with Hodgkin's disease without genomic evidence of B or T cell clonality. *Blood* 78: 760-67, 1991.
25. Zukerberg LR, Collins AB, Ferry JA, Harris NL. Coexpression of CD 15 and CD 20 by Reed-Sternberg cells in Hodgkin's disease. *Am J Pathol* 139: 475-83, 1991.
26. Hsu S-M, Waldron JW Jr, Hus P-L, Hough AJ Jr. Cytokines in malignant lymphomas: review and prospective evaluation. *Hum Pathol* 24: 1040-1057, 1993.