

A. Füsün KALPAKLIOĞLU¹
Beyhan DEMİRHAN²
Mehmet COŞKUN³

Primary Malignant Hemangiopericytoma Presenting As a Pancoast Tumor

Başkent University Hospital, Departments of
¹Pulmonary Diseases, ²Pathology and
³Radiology, Ankara-Turkey

Received: April 16, 1997

Key Words: *Pancoast tumor; mesenchymal tumor; malignant hemangiopericytoma*

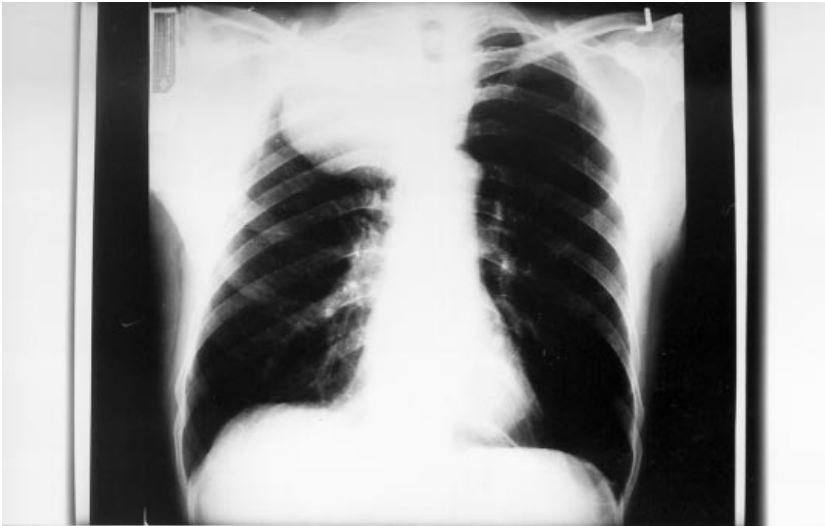

Figure 1. Chest x-ray of the patient showing a well circumscribed mass at the extreme apex of the right lung.

A 61-year-old male was admitted to Başkent University Hospital with right shoulder pain, weight loss, and dyspeptic symptoms. His chest roentgenogram showed a mass-like shadow of about 7 cm in diameter in the right upper lung area (Fig. 1). Subsequent computed tomograph (CT) revealed a large tumor with multiple metastases spread in the lung paranchimal tissue but no metastases in the mediastinal lymphatic glands. Our patient clinically presented ptosis of the right eye. All other examinations yielded normal results.

In order to establish a diagnosis, he underwent ultrasonography (USG) guided biopsy which revealed a malignant mesenchymal tumor. Histological examination of the tru-cut biopsy specimen showed branching vessels, lined by a single layer of endothelium, surrounded by haphazardly arranged tumor cells with oval nuclei and indistinct cytoplasm. There were necrosis and significant

mitotic figures in tumor cells (Fig. 2). Immunoperoxidase staining with monoclonal antibodies against vimentin, cytokeratin and van Willebrand factor (DAKO) was carried out. Tumor cells reacted positively only to the anti-vimentin antibody, and the endothelial cells in the tumor tissue were positive for the anti-factor VIII antibody. The observed feature was consistent with the characteristics of malignant hemangiopericytoma. As the literature points to primary resection with a wide safety margin being the therapy of choice, our patient underwent surgery. Intraoperatively, an 8 cm sized mass was found to be localized in the apex. The bulk of the tumor was excised, and after a normal postoperative recovery period the patient was referred to the Onchology Department. He underwent endoscopy as the data suggested that the origin may possibly be from some extrapulmonary structures. As postoperative

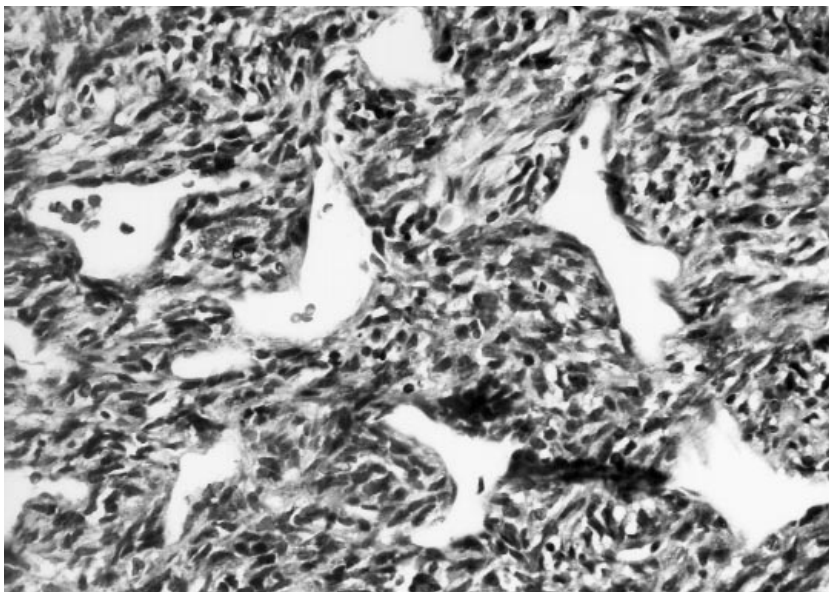


Figure 2. Spindle cell proliferation with atypical cellularity around branching vessels.

chemotherapy and/or radiotherapy were significantly associated with increased patient survival time, the patient received chemotherapy and is alive and well without signs of the tumor to date, six months after the operation.

Postoperative pathological examination confirmed the diagnosis of pulmonary hemangiopericytoma with pleural and chest wall invasion.

Primary mesenchymal intrathoracic tumors are unusual. Therefore, we discussed this rare clinical presentation of hemangiopericytoma.

The microscopic, immunohistochemical features of this patient's tumor are typical of malignant hemangiopericytoma. Primary pulmonary hemangiopericytoma is an extremely rare type of tumor of vascular origin derived from Zimmermann's pericytes (1-3). They can originate in the lung, the pleura or the mediastinal structures (1, 4). It generally occurs in adults of both sexes and its major risk, despite satisfactory surgery and complementary chemotherapy, is late occurrence in up to 50% of cases. Its spread is principally hematogenous.

During the preoperative diagnosis, tomographic examination and lung biopsy, are of significant assistance. Hemangiopericytoma is generally diagnosed by its histological characteristics. Recently however, electron microscopy and immunohistochemical methods have been used in its diagnosis (5). The biological behavior of hemangiopericytomas cannot be predicted on the basis of the clinical and morphological signs. The disease is

considered quite serious because of its malignant form and its late diagnosis. This is due to its non-distinctive, small number of symptoms which have a negative influence upon the disease prognosis and evaluation. Its outcome is difficult to predict as the usual criteria for malignancy are unreliable in this neoplasm. The management of the disease is similar to that of other sarcomas. Surgical treatment alone controls the disease in less than 30% of case and the association of surgery and radiation therapy decrease the risk of recurrence (6, 7).

The first study about primary thoracic hemangiopericytomas was published by Feldman et al. (8). Since then, few cases have been reported. Although unusual, this interesting clinical presentation of hemangiopericytoma follows the criteria of a superior pulmonary sulcus tumor (Pancoast tumor) (9). Of the cases reported, only one was described as outside the lung within the thorax (10). However, the tumor presenting a Pancoast tumor in our patient originated in the lung.

Pancoast tumor originates at the apex of the lung and may grow upward into the thoracic inlet invading the adjoining thoracic wall tissues (9). This may result in destructive rib lesions, damage to the stellate ganglion, and symptoms caused by irritation or damage to the brachial plexus. Clinical features include severe pain and muscle atrophy in the affected arm and shoulder, Horner's syndrome, and local invasion of bone and soft tissue by the tumor.

Pain in the shoulder, often associated with

paresthesias, pain, or weakness in the arm, should arouse suspicion of the presence of *Pancoast syndrome*, in which a malignant neoplasm in the apex of the lung spreads directly to the neck and involves the brachial plexus. Most tumors described as causing Pancoast's syndrome have been primary carcinomas of the lung, but others have included mesothelioma, Hodgkin's lymphoma, multiple myeloma, thyroid carcinoma, metastatic tumors and rare nonneoplastic causes (2, 9).

As Pancoast has suggested that these tumors may possibly not originate in the lung, pleura, ribs or mediastinum, our patient was examined thoroughly. However, no definite results were found. Since the

histological appearance of the tumor showed some findings of malignant potential and because recurrence and metastases can occur after many years, a lifelong regular follow-up is necessary with this neoplasm.

Correspondence Author:

A. Füsün KALPAKLIOĞLU

Başkent Üniversitesi Tıp Fakültesi

Göğüs Hastalıkları ve TBC ABD

Fevzi Çakmak Bulvarı 10. Sok. No:45

Bahçelievler, Ankara-Turkey

References

1. Stark P, Eber Cd, Jacobson F: Primary intrathoracic malignant mesenchymal tumors. Pictorial assay. *J Thorac Imaging* 9: 148-55, 1994.
2. Miller DL, Allen MS: Rare pulmonary neoplasms. *Mayo Clin Proc* 68: 492-8, 1993.
3. Hansen CP, Francis D, Bertelsen S: Primary hemangiopericytoma of the lung. *Scand J Thorac Cardiovasc Surg* 24: 89-92, 1990.
4. Zorning C, Langwieler TE, Weh HJ, Schroder S: Malignant haemangiopericytoma of the chest wall. *Eur J Surg Oncol* 19: 87-91, 1993.
5. Sugisaki K, Tsuda T, Miyazaki E, Matsumoto, T, Mizuki M: A case of malignant hemangiopericytoma: an immunohistochemical and ultrastructural study. *Respiration* 61: 172-5, 1994.
6. Kuroya M, Yokomise H, Inui K, Ike O, Mizuno H, Wada H, Hitomi S: Resection of primary pulmonary hemangiopericytoma. *Surg Today* 26: 208-12, 1996.
7. Van Damme H, Dekoster G, Creemers E, Hermans G, Limet R: Primary pulmonary hemangiopericytoma. *Surgery* 108: 105-9, 1990.
8. Feldman F, Seaman WB: Primary thoracic haemangiopericytoma. *Radiology* 82: 998-1009, 1964.
9. Pancoast HK: Superior pulmonary sulcus tumour. Tumour characterised by pain, Horner's syndrome, destruction of bone and atrophy of hand muscles. *JAMA* 99: 1391-6, 1932.
10. Chong KM, Lennox SC, Sheppard MN: Primary hemangiopericytoma presenting as a pancoast tumor. *Ann Thorac Surg* 55: 518-9, 1993.