

Şükrü PALANDUZ
Cemil TAŞÇIOĞLU
Nilgün ERTEN
Mehmet Akif KARAN
Kıvanç ÇEFLE
Kerim GÜLER
Oğuz ÖZTÜRK
Şükrü ÖZTÜRK

A Probable Case of Men1 Syndrome Presenting With Intractable Peptic Ulcer Disease and Episodic Confusion

Department of Internal Medicine,
Istanbul Faculty of Medicine,
Istanbul University, Çapa, Istanbul-Turkey

Received: February 21, 1997

Key Words: MEN1 (Multiple Endocrine Neoplasia Type 1), gastrinoma, insulinoma.

There are a number of polyglandular disorders characterized by autonomous hyperfunction of more than one endocrine gland. The majority of these disorders are of genetic origin. In this context there are three syndromes worth of mentioning:

1. Multiple Endocrine Neoplasia, Type 1 (MEN1; or Wermer's Syndrome) where there are multiple tumors of the anterior pituitary, parathyroid glands, and pancreatic islet cells (especially insulinoma and gastrinoma).

2. Multiple Endocrine Neoplasia, Type 2a (MEN2a; or Sipple's Syndrome) which is an entirely different syndrome characterized by medullary carcinoma of the thyroid, pheochromocytoma, and parathyroid hyperplasia.

3. Multiple Endocrine Neoplasia, Type 2b (MEN2b; Mucosal Neuroma Syndrome) which resembles MEN2a but consists of additional clinical features such as disfiguring neuromas of the lips, tongue, ganglioneuromas of the gastrointestinal tract and a marfanoid body habitus (1).

Although the clinical features of these syndromes are well defined, the mechanism of the pathophysiological process (from the gene to the clinical symptoms) still remains a mystery.

Herein we describe a patient whose initial clinical presentation was intractable peptic ulcer disease but during the follow up turned out to be a case of insulinoma in addition to gastrinoma. The patient, a 35 year old policeman, was admitted to our hospital because of episodic confusion and recurrent syncope. He had been well until 1986 when he developed peptic ulcer disease

which was refractory to medical therapy. He underwent gastric surgery twice in 1986 and 1988 without relief. Shortly afterwards the second operation he developed weight loss and persistent diarrhea which was thought to be due to dumping syndrome. Meanwhile he began to have episodic dizziness and confusion. Plasma glucose concentrations determined at the time of symptoms varied between 45-65 mg/100ml.

The physical examination revealed a mass (approximately 5x5cm) in the left hypocondrium.

Laboratory studies revealed mild normocytic normochromic anemia (Hct%36.7, MCV 82.6 μ 3), and hypoglycemia (45 mg/dL). Other parameters of total blood count and blood chemistry (BUN, creatinin, uric acid, sodium, potassium, chloride, calcium, phosphorus, alkaline phosphatase, SGOT, SGPT, LDH, CPK, total and direct bilirubin, cholesterol, triglyceride, total protein and albumin) were normal. Blood glucose concentration determinations performed on several occasions (when the patient displayed symptoms such as syncope, confusion) varied between 29-45 mg/dL, necessitating a continuous perfusion of %20 glucose solution. Blood insulin and C peptide levels measured during a hypoglycemic attack (blood glucose level was 30 mg/dL) were %74 μ iu/ml (normal values:0-30) and 4.2 ng/ml (normal values:0.8-4) respectively, supporting a diagnosis of insulinoma. The gastrin level was 2600 pg/ml (Normal:<90 pg/ml). An abdominal ultrasonography revealed a hypoechoic area (73x37 mm) in the corpus and tail of the pancreas as well as multiple hypoechoic nodules in the liver (Figures 1 and 2). A computed tomographic scan also showed multiple masses in the liver in addition to a mass

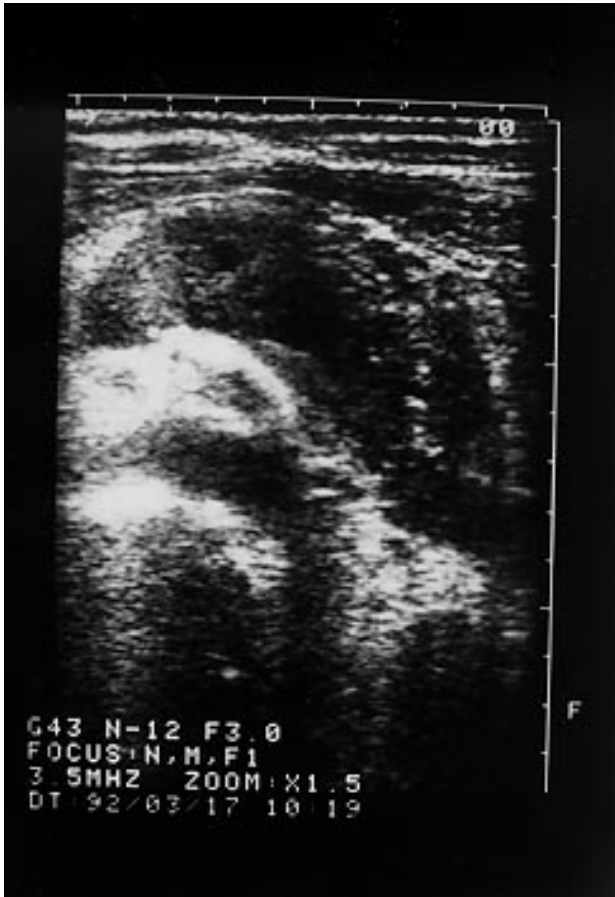

Figure 1. Abdominal ultrasonography revealed a hypoechoic area in the tail and corpus of the pancreas.

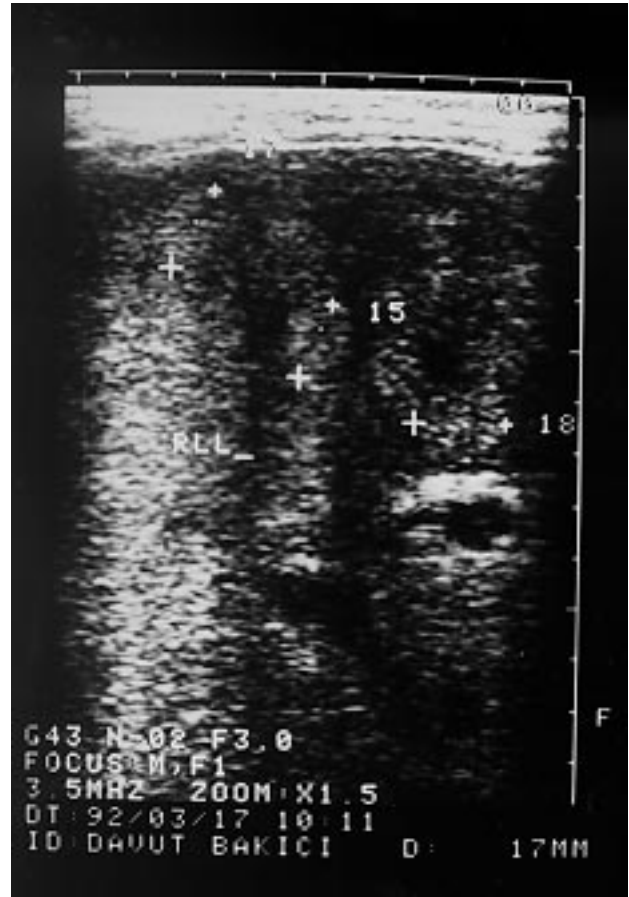


Figure 2. Abdominal ultrasonography shows multiple metastatic nodules in the liver.

filling the left upper quadrant of the abdominal cavity which obscured the corpus and tail of the pancreas (Figure 3). A gastroscopic examination showed diffuse thickening of the mucosa in the corpus and petechial bleeding, which raised a suspicion of granulomatous gastritis or lymphoma. However, the pathologic examination of the biopsy specimens revealed chronic gastritis and metaplastic changes of pyloric type.

Our original clinical impression was that the patient was a case of Zollinger-Ellison Syndrome because all the clinical and laboratory findings (intractable peptic ulcer disease necessitating gastric surgery twice; persistent diarrhea and hypergastrinemia) implied the presence of a gastrinoma. The other clinical features such as dizziness and recurrent confusional episodes were thought to be due to postprandial hypoglycemia, a component of dumping syndrome. However, low fasting blood glucose concentrations accompanying increased levels of insulin and C-peptide excluded this possibility and lead to a

diagnosis of insulinoma in addition to gastrinoma. We performed further laboratory studies in regard of other autonomous functioning endocrine tumors, which were all negative: Scintigraphic examination of the parathyroid glands, plasma concentrations of parathormon, thyroid hormones T3 and T4, TSH, LH, PRL, FSH, and 24 hour urinary excretion of vanil mandylic acid and 5-OH indol acetic acid. Computed tomographic scanning of the pituitary gland was normal. The patient was considered ineligible for curative surgery and a biopsy specimen obtained from the liver under computerized axial tomographic assistance revealed non-specific changes in the liver, while examination of another specimen obtained at the same session from the mass behind the stomach showed tumoral cells originating from the islet cells of the pancreas (islet cell type small cell tumor). These cells had a weak affinity for gastrin stain but were stained well with grameius stain (Figure 4).

Since the hypoglycemic attacks were unresponsive to

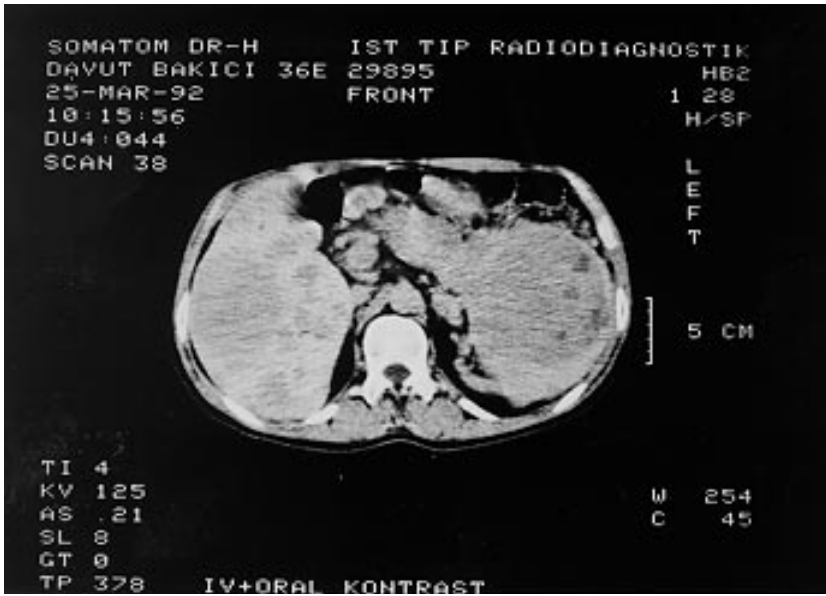


Figure 3. Abdominal computed tomography. Multiple masses in the liver and another mass filling the left upper quadrant of the abdominal cavity and obscuring the corpus and tail of the pancreas. There is also splenic hilar invasion with posterior displacement of the splenic vein.

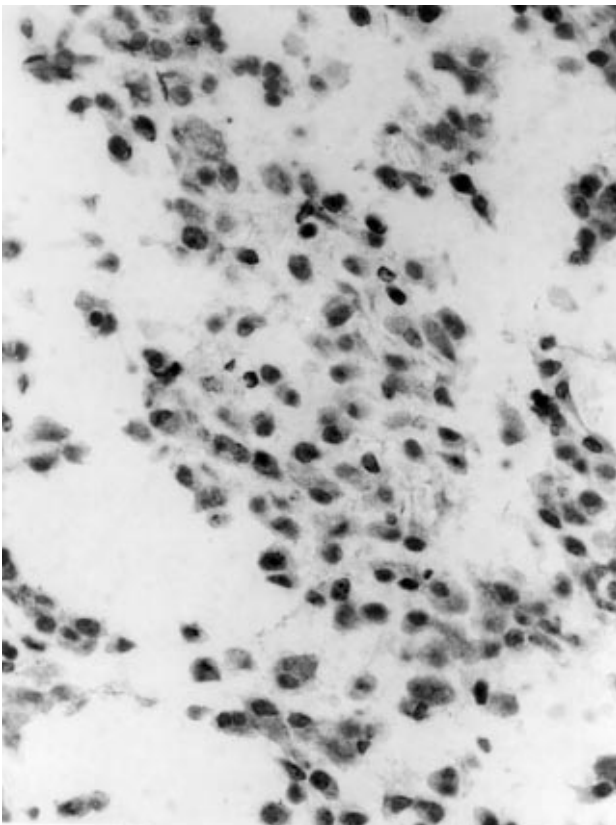


Figure 4: Histopathologic specimen. Islet cell type small tumoral cells with weak affinity for gastrin stain but painting well with grameius stain.

20% glucose infusion, the patient was given octreotide (2x100u sc.) after which the blood glucose concentration increased while the C-peptide level decreased. Shortly

after the beginning of a chemotherapeutic regimen involving adriamycin and vepesid (in accordance with oncologic consultation) the patient died of massive gastrointestinal bleeding.

Insulinomas and gastrinomas are rare tumors and the coexistence of them in the same patient is even rarer. In clinical practice one can encounter them in sporadic form or as a part of MEN1 syndrome. It is reported that %15-20 of patients with Zollinger-Ellison Syndrome and %3 of patients with insulinoma have other endocrine neoplasms (2). On the other hand, islet cell tumors of the pancreas are present in 65-80% of patients with MEN1 Syndrome. These tumors are typically multifocal and secrete multiple peptides either concurrently or at different times during the course of the disease (3). Although it is difficult to establish a diagnosis of MEN1 in the absence of other endocrine tumors other than insulinoma and gastrinoma, (especially adenomas of the parathyroid glands), it is known that affected individuals may demonstrate multiple endocrine involvement simultaneously or years may elapse between the discovery of one tumor and the next (4). Moreover, many gastrin and insulin secreting islet cell tumors contain other hormones including ACTH, glucagon, parathyroid hormone, etc., which are usually clinically silent (5, 6), and it is also reported that solitary sporadic tumors secreting multiple peptides may mimic MEN1 syndrome (7). It is recommended that all patients with pancreatic endocrine tumors, regardless of their initial clinical picture should undergo continuous monitoring for new elevations of hormones (8).

All these facts are compatible with the clinical

progress of our case who developed symptomatic hypoglycemia years after intractable peptic ulcer. Although we did not detect laboratory findings of hyperparathyroidism during the follow up, it remains as a possibility, albeit weak, that our patient would have developed hypercalcemia had he lived long enough. So, we think that this patient should be regarded as a potential case of MEN1 syndrome.

There are some interesting clinical observations which can be explained by the interactions of multiple hormones produced by pancreatic tumors: In a patient streptozocin therapy for metastatic gastrinoma unveiled the presence of an insulinoma (9), and surgical removal of pancreatic tumors secreting somatostatin in addition to insulin can cause postoperative hypergastrinemia and gross peptic ulceration (10).

It is reported that 50% of insulinomas and gastrinomas are not evident on preoperative imaging studies. Calcium angiography, endoscopic ultrasonography, isotope labeled octreotide scanning are new promising imaging techniques. Intraoperative angiography and ultrasound are considered as the best methods for intraoperative detection of insulinomas. On the other hand, for gastrinomas, intraoperative endoscopic transillumination and duodenotomy are

important due to the fact that 30-40% of gastrinomas are found in the duodenal wall (11).

The results of surgical intervention are different in the two types of pancreatic tumors. Insulinomas are reported to be resectable in over 90% of cases (12), and surgery is indicated in patients with MEN1 syndrome even if a lesion is not visualized radiologically (13). This is in contrast to gastrinomas, where only 15-20% of tumors are resectable, and those associated with MEN1 syndrome are considered ineligible for surgery due to multifocal involvement (14). It is reported that surgical removal of islet cell tumors did not cure hypergastrinemia and Zollinger-Ellison syndrome in patients with MEN1 (13, 15, 16). Nevertheless, some advocate debulking surgery whenever possible in hormone active pancreatic tumors in regard of the success of subsequent medical therapy (17).

The invention of histamine receptor blockers and more recently proton-pump inhibitors have changed the grave outlook of unresectable gastrinomas dramatically. Octreotide, a long acting somatostatin analogue, is also a potent drug in alleviating symptoms due to hypergastrinemia. On the other hand, neither octreotide nor diazoxide are effective in controlling hypoglycemia in patients with insulinoma (18, 19). Fortunately, as

References

1. Loeb JN. Polyglandular Disorders. Cecil Textbook of Medicine (Eds. Wyngaarden JB, Smith LH, and Bennet JC) W. B. Saunders Company Philadelphia, London, Toronto, Montreal, Sydney, Tokyo 1992, pp: 1386-1990.
2. Sardi A, Singer JA. Insulinoma and gastrinoma in Wermer's disease (MEN I). Arch Surg 127(7): 835-36, 1987.
3. Vassilopoulou Sellin R, Ajani J. Islet tumors of the pancreas. Endocrinol Metab Clin North Am 23(1): 53-65, 1994.
4. Schimke RN. Disorders Affecting Multiple Endocrine Systems. Harrison's Principles of Internal Medicine (Eds. Wilson JD, Braunwald E, Isselbacher KJ et al) McGraw-Hill Inc., New York 1991, pp: 1811-14.
5. McGuigan JE. Zollinger-Ellison Syndrome (Gastrinoma). Harrison's Principles of Internal Medicine (Eds. Wilson JD, Braunwald E, Isselbacher KJ et al) McGraw-Hill Inc., New York 1991, pp: 1241-43.
6. K Yamaguchi, M Enjoji. Endocrine neoplasms of the pancreas: a clinicopathologic study of 24 cases and immunohistochemical remarks. Surg Today 22(4): 305-12, 1992.
7. Debas HT, Mulvihill SJ. Neuroendocrine gut neoplasms. Important lessons from uncommon tumors. Arch Surg 129(9): 965-71, 1994.
8. Wynick D, Williams B, Bloom BR. Symptomatic secondary hormone syndromes in patients with multiple endocrine neoplasia: a prospective study. N Engl J Med 319(10): 605-7.
9. Bar M, Burke M, Isakov A, Almog C. Insulinoma after streptozotocin therapy for metastatic gastrinoma: natural history or iatrogenic complication. J Clin Gastroenterol 12(5):579-80, 1990.
10. Price DE, Absalom BR, Davidson K, Bolia A, Howlett TA. A case of multiple endocrine neoplasia: hyperparathyroidism, insulinoma, GRF-oma, hypercalcitoninaemia and intractable peptic ulceration. Clin Endocrinol Oxf 37(2): 187-8 (Abst), 1992.
11. Meko JB, Norton JA. Endocrine tumors of the pancreas. Curr Opin Gen Surg 186-94, 1994.
12. Dopmann JL, Shawker TH, Miller DL. Localization of islet cell tumors. Gastroenterol Clin North Am 18(4): 793-804, 1989.

13. Grama D, Skogseid B, Wilander E, Eriksson B, et al. Pancreatic tumors in multiple endocrine neoplasia type 1: clinical presentation and surgical treatment. *World J Surg* 16(4): 611-8, 1992.
14. Kaplan LM. Pancreatic Islet Cell Tumors. *Harrison's Principles of Internal Medicine* (Eds. Wilson J, Braunwald E, Isselbacher KJ, et al) McGraw-Hill Inc., New York 1991, pp: 1390-1393.
15. Mignon M, Rusnewski P, Podevin P, Sabbagh L, et al. Current approach to the management of gastrinoma and insulinoma in adults with multiple endocrine neoplasia type I. *World J Surg* 17(4): 489-97, 1993.
16. Sheppard BC, Norton JA, Doppman JL, Maton PN, et al. Management of islet cell tumors in patients with multiple endocrine neoplasia: a prospective study. *Surgery* 106(6): 1108-17, 1989.
17. Bothmund M, Stinner B, Arnold R. Endocrine pancreatic carcinoma. *Eur J Surg Oncol* 17(2): 191-9 (Abst), 1991.
18. Modlin IM, Lewis JJ, Ahlman H, Bilchik AJ. Management of unresectable malignant endocrine tumors of the pancreas. *Sur Gynecol Obstet* 176(5):