

Leyla CANPOLAT¹
Aysel KÜKNER¹
İbrahim CANPOLAT²
Enver OZAN¹

Ultrastructural and Morphometric Analysis of Peripheral Nerve Regeneration Within Silicone Tubes

Received: July 15, 1997

Abstract: Semi-thin and thin sections were used to observe the morphogenesis of peripheral nerves regenerating in silicone tubes. The progress of peripheral nerve regeneration across a 10 mm gap within the silicone tubes was examined after 3, 6 and 9 months. The left sciatic nerves of rats were transected. The proximal and distal nerve stumps were inserted into a silicone tube, in which they were separated by a 10 mm gap. A tissue cable formed inside the silicone tube with regenerated axons. In the 3rd month, the 10 mm gap was bridged by a structure composed of regenerating axons, blood vessels and Schwann cells of a newly formed nerve trunk. After 3, 6 and 9 months the sciatic nerves regenerated. The endoneurial tissue continuity in the tubes was completely

disrupted and the growth environment was completely reconstituted for regenerating fibers. In none of the experimental groups was degeneration observed in the myelinated, unmyelinated or the endoneurial tissue. In the 9-month group, all myelinated and unmyelinated nerve fibers were normal, but the myelinated fiber diameter, myelin sheath thickness, axon diameter and myelinated axon number did not reach their normal values. Myelinated nerve fibers were normal in all of the groups, while the distal nerve part of only one animal was degenerated in the 3-month group.

Key Words: Regeneration, peripheral nerve, ultrastructure.

¹Department of Histology and Embryology, Faculty of Medicine, ²Department of Surgery, Faculty of Veterinary Medicine, Firat University, Elazığ-Turkey

Introduction

Various methods of treatment have been used to improve the regeneration of peripheral nerve lacerations: locally applied corticoids, B vitamin complex, NGF, FGF, laminin, nerve allograft, microwave irradiation, laser assisted surgery, microepineurial anastomoses with CO₂ laser and suture techniques (1-9). Recent experiments using silicone tubes (10-16) indicate that this method seems to have minor complications. This material is inert and does not induce extensive scarring or degeneration after implantation. A few morphometric studies of axons comprising nerves regenerated across a gap have been carried out (11, 12, 13, 16). In the present study, morphometric counts were obtained from the proximal and distal stumps of the regenerated nerve segment. The morphogenesis and the myelinated fiber number, fiber diameter, myelin sheath thickness and axon diameter of the regenerated segment within the silicone tube were determined. In crushed nerve injuries, regeneration is remarkably successful because of the continuity of the endoneurial tubes (11, 14). This is shown to contrast

with nerve growth across a gap induced by the separation of severed nerve stumps. In this situation, endoneurial continuity is completely disrupted and the growth environment must be entirely reconstituted for regenerating fibers. In reports of nerve regeneration across a 10 mm gap in the absence of endoneurial tubes, normal regeneration of the nerve fibers has occurred (12, 15).

Materials and Methods

Adult Wistar male rats weighing 200-250 g were used. They were randomly allocated into four groups, each consisting of three rats. The animals were anaesthetised with halothane. Under deep general anesthesia, the sciatic nerve was mobilized, and transected at a mid-tight level just proximal to the tibial and peroneal bifurcation. The proximal and distal stumps were sutured into the openings of a 12 mm long silicone tube. The resulting gap between the two severed stumps was 10 mm. The sciatic compartment was closed with a

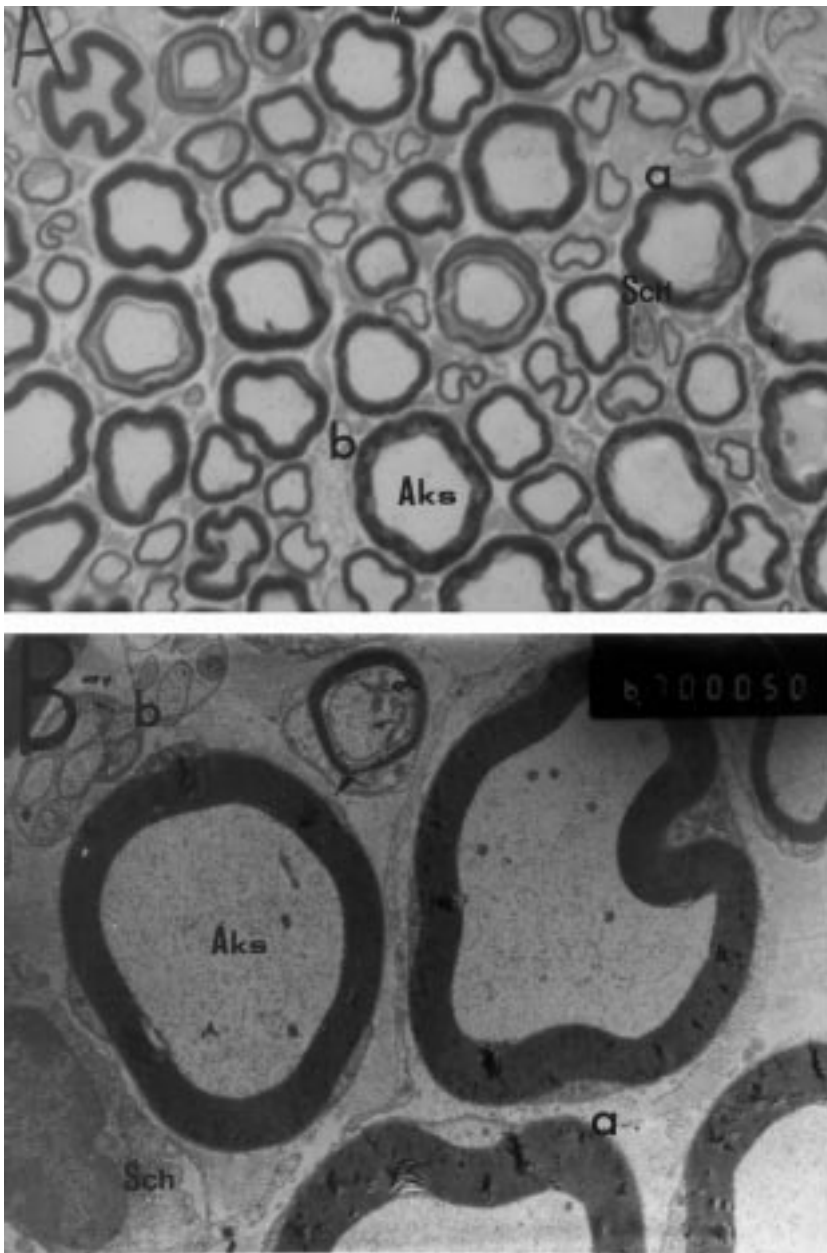


Figure 1. In the control group; myelinated (a) and unmyelinated (b) nerve fibers, axon (Aks), Schwann cell (Sch) are shown in the n. ischiadicus (A, Toluidin Blue X330) by electron (B, Lead citrate-Uranyl acetate X9600) microscopy.

9.0 silk suture and the skin was closed with wound clips. A total of 12 rats were implanted in silicone tubes. After recovery from anesthesia, the rats were housed in sawdust-covered flat-bottom plastic cages and carefully observed for complications related to hind limb denervation. The animals implanted in the silicone tubes were sacrificed after 3, 6 and 9 months. The same procedure was followed for unoperated controlateral nerves; these nerves served as the control groups. Nerve specimens were obtained after the nerves were immediately fixed by 0.15 M phosphate buffered 2.5%

glutaraldehyde (pH 7.3). The sciatic nerve was quickly dissected free from the silicone tubes and postfixed in 1% osmium tetroxide in 0.15 M phosphate buffer for 1 h, dehydrated in serial concentrations of alcohol and embedded in Araldite. Semithin transverse sections (1 μ m) were stained with Toluidin blue. The total number of myelinated fibers was determined. The sections were viewed under a light microscope and the fibers counted with the aid of an eye-piece graticule. In light of the area measurements, the following parameters were calculated: fibre diameter, axonal diameter and average myelin

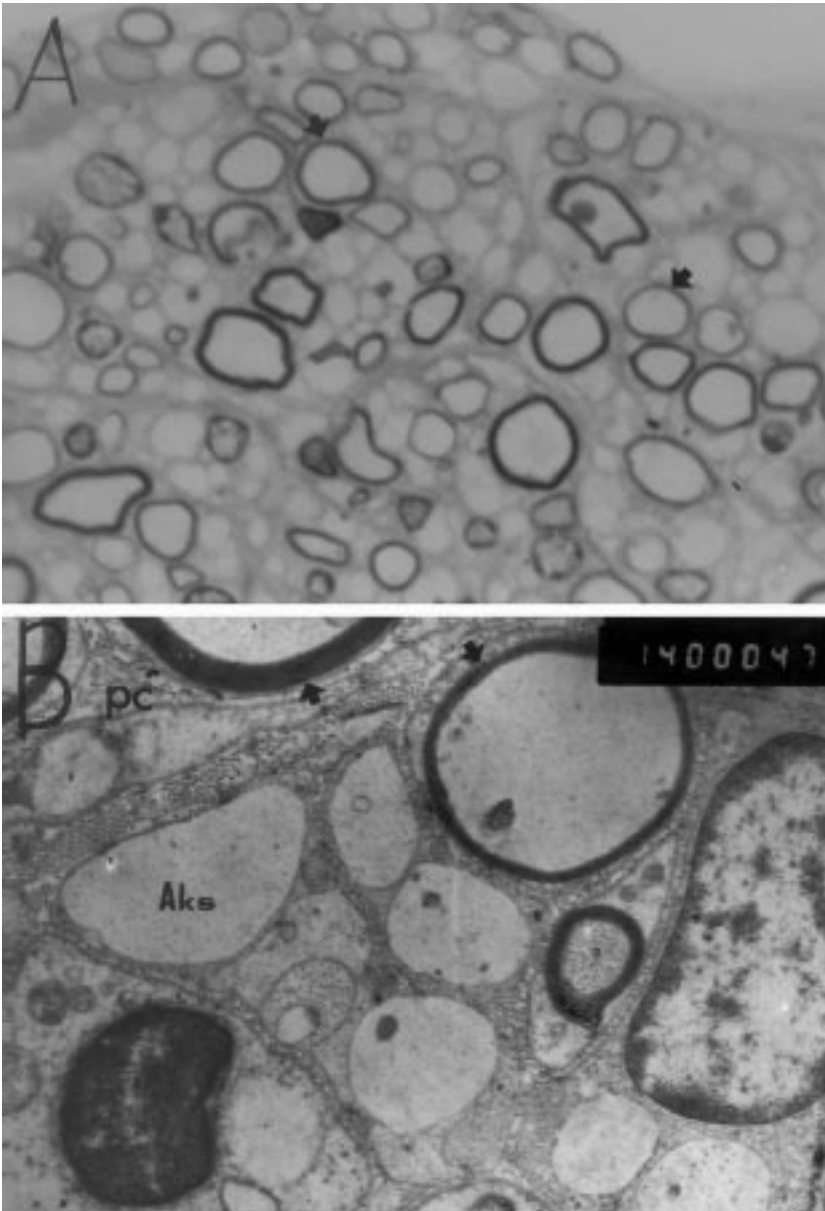


Figure 2. Three months following nerve transection. Thinly myelinated fibers (arrow) in the tube by light (A, Toluidin Blue X330) and electron (B, Lead citrate-Uranyl acetate X14000) microscopy. B: some of the large calibre axons (Aks) are lack myelin sheaths. The profiles of the thin myelin sheath contain axoplasm. Note that several layers of perineurial cell processes (pc) from the wall of the fascicle and that the walls of the fascicle are lined with prominent external lamina. Axons are separated by a process of perineurial cells (pc). Lead citrate-Uranyl acetate. X14000.

sheath thickness, under an oil-immersion objective. Ultrathin transverse sections were stained with uranyl acetate lead citrate before examination with a JEOL CX II electron microscope.

Results

In the control groups, the normal tissue of the sciatic nerve is shown in Figure 1.

After one month, within the silicone tube, a very thin tissue cable reached the distal of the nerve. Because of the fact that this cable was very thin and fragile, the

application of histologic procedures was unsuccessfull.

Three months after nerve transection, axons reached the distal stump and myelination of some fibers progressed to the 10 mm segment of the regenerated nerve. The most myelinated fibers were thinly ensheathed in the distal and proximal stumps (Figure 2). Some large caliber axons lacked myelin sheaths (Figure 2B). Schwann cells and most myelinated and unmyelinated fibers were of normal appearance. Perineurium reoccurred. The endoneurial matrix contained a great number of collagen fibers. The nerve was divided into distinct compartments by a newly formed perineurial sheath. In the structure

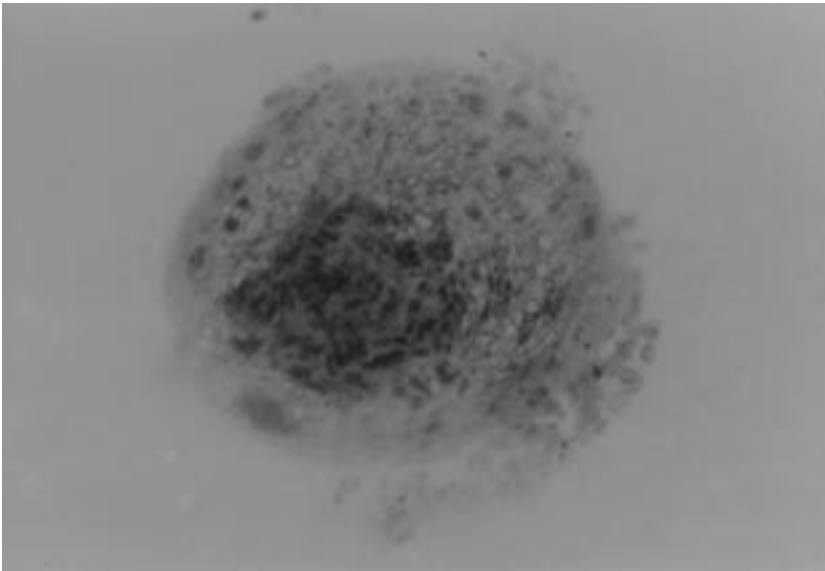


Figure 3. Nerve regeneration in the tube 3 months after nerve transection. Pathological changes can be observed in the middle section of the nerve tissue. Toliuidin Blue. X10.

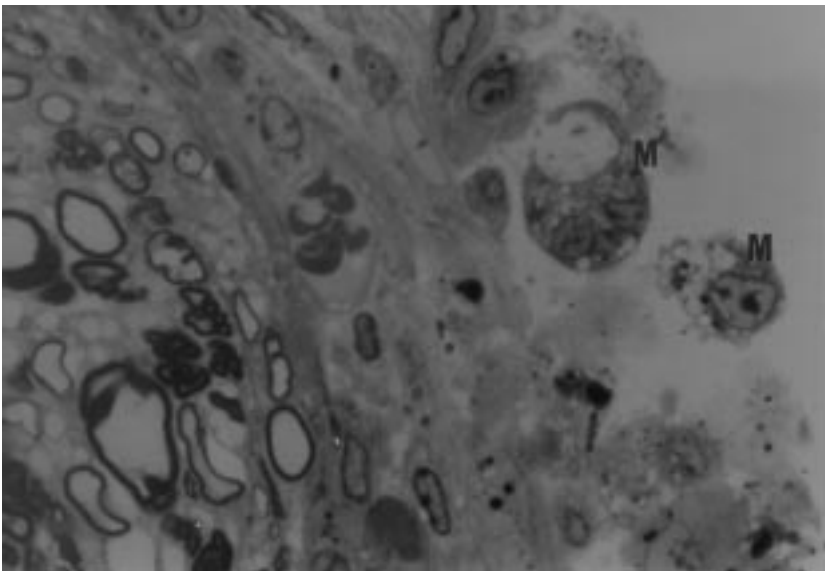


Figure 4. Nerve regeneration in the 3 month in the tube 3 months after nerve transection. Macrophages (M) surrounding the outer surface of the nerve tissue. Toluidin Blue. X100.

there were no macrophages, as shown in Figure 2B. Pathological changes occurred in only one animal in this group and focused centrally on the distal nerve (Figure 3). Macrophages were observed at the periphery of the distal nerve piece (Figure 5, 6, 7) and the nerve was enclosed in a basal lamina, but the axons were not surrounded by myelin sheaths. Macrophages were not observed between infolds of the irregularly formed myelin sheaths. Myelin reduplication was present (Figure 7).

Six and nine months after nerve transection, both the diameters of the axons and their myelin sheaths increased compared to 3 months following nerve transection. But no further changes were observed in the structure of the

nerve or in the relationship between its various components. Myelinated and unmyelinated nerve fibers were found to display normal structure. Myelin lamellas were found to be normal. The axoplasm had a normal appearance. The most prominent feature of the nerves was a massive accumulation of neurofilaments in both myelinated and unmyelinated axons after 9 months (Res 8). Blood vessels were found to be more numerous than normal in the nerve tissue.

Morphometric counts consisted of the numbers of myelinated fibers in the proximal and distal stumps of the regenerated segment 3, 6 and 9 months after insertion of the silicone tube. In all groups there were more fibers in the proximal stump than in the distal stump. The

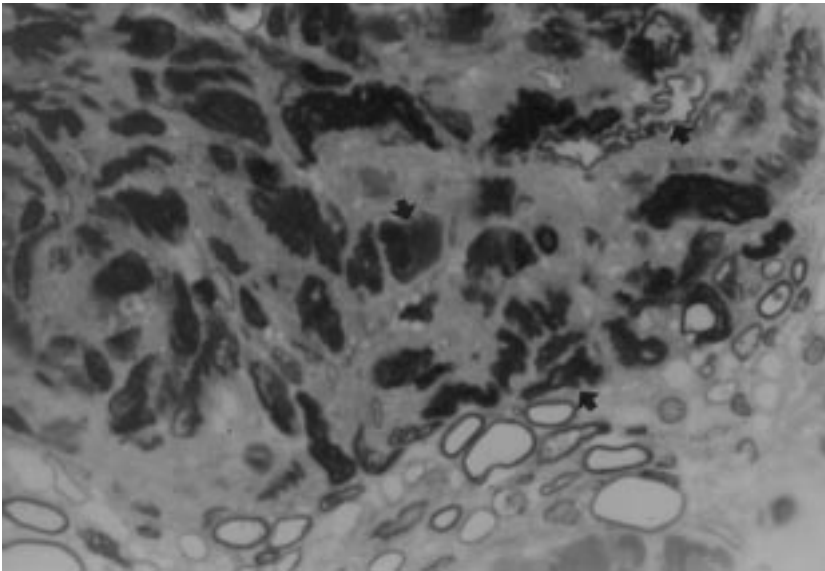


Figure 5. Nerve regeneration three months after nerve transection. Irregularly shaped myelin sheath infolds (arrow). Toluidin blue. X100.

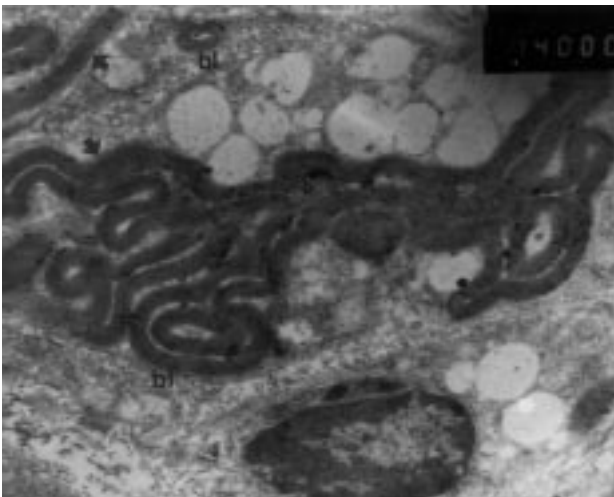


Figure 6. In the third month, irregular shaped myelin sheaths (arrow) enclosed with a basal lamina (b1). Lead citrate-Uranyl acetate. X14000.

number of fibers within the tube increased significantly compared to the control group ($p < 0.001$). In the 9 months groups, there were more fibers than in the other groups but less fibers than in the control group. The axon diameter, myelin sheath thickness and fiber diameter were smaller than in normal tissue (Table 1).

Discussion

In this study, the severed ends of the sciatic nerve were sutured to a 12 mm long silicone tube. In the 3rd month following injury, the gap had been bridged by fibers which penetrated deeply into the distal stump. The

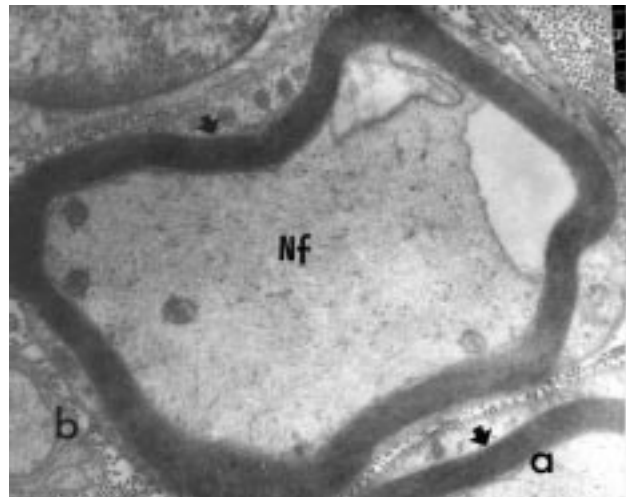


Figure 7. 9 months following nerve transection, myelinated (a) and unmyelinated (b) fibers of the sciatic nerve are observed in the normal structure. Myelin lamellas are normal (arrow). In the axoplasm massive neurofilament (Nf) accumulation can be seen in the myelinated and unmyelinated fiber. Lead citrate-Uranyl acetate. X9500.

regenerated piece rapidly formed a new perineurium. Nerve regeneration between the proximal and distal stumps. The number decreased at the distal stumps rather than at the proximal stumps.

Nerve cable morphogenesis within a silicone tube has previously been described (1, 13, 14, 15, 16). The tube functions as a conduit for the regenerating nerve. Previous studies have shown that fibers from the proximal stump of the transected peripheral nerve are able to regenerate across a gap into the distal nerve stump (11, 12, 17, 18, 19, 20, 21). In recent years,

Parameters	Fibre diameter (mean+S.D)	Axon diameter (mean+S.D.)	Myelin thickness (mean+S.D.)	Fiber number (mean+S.D.)
Normal	11.33+3.67	8.33+2.81	1.55+0.60	7800+1.45
3 Mohths				
proximal	8.48+2.82	6.70+21.38	0.67+0.37	4800+1.53
distal	5.36+2.00	4.75+1.44	0.42+0.34	2770+1.72
6 Mohths				
proximal	9.60+2.91	7.63+2.37	1.06+0.45	5200+1.15
distal	9.40+2.77	7.33+2.30	1.01+0.45	3400+1.93
9 Months				
proximal	9.80+2.86	7.85+2.35	1.36+0.58	6000+2.71
distal	9.56+3.03	7.44+1.97	1.31+0.58	5700+3.45

Table 1. Myelinated fiber diameter (μ), axon diameter (μ), myelin sheath thickness (μ) and myelinated fiber number in normal and regenerated rat sciatic nerve.

nerve repair using tubes made of permeable material has yielded satisfactory results: collagen tube, collagen polymer tube, poly (organo) phosphazene tubular prosthesis (22, 23, 245). These tubes are used to prevent fibrin clot in nerve repair . Silicone tubing is impermeable, where as these tubes are permeable and unducel a slow foreign body response with infiltration by macrophages (23). In silicone tubes and permeable tubes there is no difference in the growth of a tissue bridge. However, permeable tubes seem to have potential effects (24). Chen HH et al. reported that they used collagen polymer tubes for nerve repair. In their studies, the number of myelinated axons in the impermeable silicone tube was greater (9117+/-282) than that in the permeable collagen tube (8589+/-137) (23). In our study, in the experimental groups, no fibrin clots were found in the silicone tubes. Furthermore, our results showed that fiber size increased with time. They observed that there was no difference between silicone tubes and permeable tubes in the growth of a tissue bridge (23, 24).

After 3 months, some of the large axons were still unmyelinated, as observed by Le Beau et al. (1988). Regeneration occurred in the 10 mm gap and degenerative tissue was absent inside the tube. The nerve growth and myelination were asily analysed. Macrophages were not observed in this structure because there was no degenerative tissue. Only 1 animal in the 3 months groups showed pathological changes to the distal

stump of the nerve in the tube. On this side there were also macrophages. The myelin sheaths within the Schwann cells were irregular in shape. Myelin reduplication and infolds occurred. Knox et al. (1989) also described this type of pathological change in nerve tissues (25). The occurrence of these events may reflect spontaneous axonal degeneration which occurs in developing peripheral nerves, as decribed by Reier et al. (1972) (26).

In the third months, Schwann cell numbers increased. Similar findings were reported by William et al., 1983 (27). Schwann cells did not appear to be important in guiding axons across the gap, but they may be an important source of trophic and tropic factors during peripheral nerve regeneration. A neurite-promoting factor released from the distal segment of a transected sciatic nerve coincides with an increase in the Schwann cell number and metabolic activity of this area (13).

By 9 months the axons were all well myelinated. The present study showed that regeneration occurred across a gap in the absence of endoneurial tubes. This is because silicone tubes probably function to guide axons to their distal target. This model provides a useful system for applied research concerning the clinical repair of human peripheral nerve injuries. Nine months' regeneration was effective in producing morphologically normal regenerated fibers. However, complete maturation of these fiber by an increase in axonal diameter and myeilm sheath thickness did not reach normal tissue level.

References

1. Becker KW, Kienecker EW, Andrea I. Effect of locally applied corticoids on the morphology of peripheral nerves following neurotmesis and microsurgical suture. *Neurochirurgia*. 30(6): 161-7, 1987.
2. Becker KW, Kienecker EW, Dick P. A contribution to the scientific assessment of degenerative and regenerative processes peripheral nerve fibers following axonotmesis under the systemic administration of vitamins B1, B6 and B12 light light and electron microscopy findings in the sephenous nerve of the rabbit. *Neurochirurgia*. 33(4): 113-121, 1990.
3. Otto D, Unsicker K, Grothe C. Pharmacological effects of NGF and EGE applied to the transected sciatic nerve on neuron death in adult rat dorsal root ganglia. *Neurosci. Lett.* 83: 156-160, 1987.
4. Madison R, Da Silva CF, Dikkes P, Chiu T, Sidman RL. Increased rate of peripheral nerve regeneration using bioresorbable nerve guides and a Laminin-Containing Gel. *Exp. Neurol.* 88: 767-772, 1985.
5. Tajima K, Tohyama K, Ide C, Abe M. Regeneration through nerve allografts in the Cynomolgus Monkey (*Macaca fascicularis*). *The Journal of Bone and Joint Surgery*. 73(2): 172-184, 1991.
6. Glasby MA, Gschmeissner SG, Hitchcock RJ, Huang CL-H. The dependence of nerve regeneration through muscle grafts in the rat on the availability and orientation of basement membrane. *J. Neurocytol.* 15: 497-510, 1986.
7. Kerns JM, Weinrib HP. Microwave irradiation of peripheral nerve following injury: a structural analysis of degeneration and regeneration. *Exp. Neurol.* 92(3): 651-64, 1986.
8. Bailes JE, Cozzens JW, Hudson AR, Kline DG, et al. Laser-assisted nerve repair in primates. *J. Neurosurg.* 71(2): 266-72, 1989.
9. Fischer DW, Beggs JL, Kenshalo DL, Shetter AG. Comparative study of microepineurial anastomoses with the use of CO2 laser and suture techniques in rat sciatic nerves: Part 1. Surgical technique, nerve action potentials and morphological studies. *Neurosurg.* 17(2): 300-8, 1985.
10. Jenx CB, Coggeshall RE. Long term Patterns of Axon Regeneration in the Sciatic Nerve and its Tributaries. *Brain Res.* 345: 34-44, 1985.
11. Jenq CB, Coggeshall RE. Nerve regeneration through holey silicone tubes. *Brain Res.* 361: 233-241, 1985(b).
12. Le Beau JM, Ellisman MH, Powell HC. Ultrastructural and morphometric analysis of long-term peripheral nerve regeneration through silicone tubes. *J Neurocytol.* 17(2): 162-72, 1988.
13. Hollowell JP, Villadiego A, Riach KM. Sciatic nerve regeneration across a gap within a silicone chamber, long-term effects of NGE and consideration of axonal branching. *Exp. Neurol.* 110: 45-51, 1990.
14. Scaravilli F, Love S, Myers R. X irradiation impairs regeneration of peripheral nerve across a gap. *J. Neurocytol.* 15(4): 439-51, 1990.
15. Williams LR et al. Spatial-Temporal progress of peripheral nerve regeneration within a silicone chamber: parameters for a bioassay. *J. Comp. Neurol.* 218: 460-70, 1983.
16. Williams LR et al. Exogenous matrix precursors promote functional regeneration across a 15 mm gap within a silicone chamber in the rat. *J. Comp. Neurol.* 264: 284-290, 1987.
17. Le Beau JM, Powell HC, Ellisman MH. Node of Ranvier formation along fibres regenerating through silicone tube implants: a freeze fracture and thin section electron microscopic study. *J. Neurocytol.* 16: 347-58, 1987.
18. Azzam NA, Zalewski AA, Williams LR, Azzam RN. Nerve cables formed in silicone chambers reconstitute a perineurial but not avascular endoneurial permeability barrier. *J. Comp. Neurol.* 314(4): 807-19, 1990.
19. Fields RD, Ellisman MH. Axons regenerated through silicone tube splices. I. Conduction properties. *Exp. Neurol.* 92: 48-60, 1986.
20. Scaravilli F. Regeneration of the perineurium across a surgically induced gap in a nerve encased in a plastic tube. *J. Anat.* 139: 411-424, 1984.
21. Williams LR, Azzam NA, Zalewski AA, Azzam RN. Regenerating axons are not required to induce the formation of a Schwann cell cable in a silicone chamber. *Exp. Neurol.* 120: 49-59, 1993.
22. Kim DH, Connolly SE, Kline DG et al. Labeled Schwann cell transplants versus sural nerve grafts in nerve repair. *J. Neurosurg.* 80(2): 254-60, 1994.
23. Chen HH, Liu HM. The use of collagen polymer tube and fibrin clot in peripheral nerve repair. *Proc. Natl. Sci. Counc. Repub. China B.* 18(2): 58-63, 1994.
24. Langone F, Lora S, Veronese FM, et al. Peripheral nerve repair using a poly (organo) phosphazene tubular prosthesis. *Biomaterials.* 16(5): 347-53, 1995.
25. Le Beau JM, Knox CA, Kokmen E, Dyck PJ. Morphometric Alteration of Rat Myelinated Fibers with Aging. *J. Neuropathol. Exp. Neurol.* 48: 119-139, 1989.
26. Reier PJ, Hughes H. Evidence for spontaneous axon degeneration during peripheral nerve maturation. *Am. J. Anat.* 135: 147-52, 1972.
27. Williams LR, Long FM, Powell HC. Spatial-temporal progress of peripheral nerve regeneration within a silicone chamber: parameters for a bioassay. *J. Comp. Neurol.* 218: 460-470, 1983.