

Osman GÜLER  
Metin AYDIN  
Muammer KARAAYVAZ  
Osman Nuri DİLEK

## The Effect of Hepatic Plexus Vagotomy on the Sphincter of Oddi in Humans

Received: March 23, 1998

Department of Surgery, Research Hospital of  
the Medical Faculty, Yüzüncü Yıl University  
Van-Turkey

**Abstract:** Right upper quadrant biliary type pain is classified in three types. Biliary group III patients have only biliary type pain that is due to sphincter of Oddi dyskinesia and without any abnormalities. In these patients, endoscopic sphincterotomy is a current treatment method that is performed to decrease the choledochal pressure and to facilitate bile flow into the duodenum. In this prospective study, the effect of hepatic plexus vagotomy as an adjunct to cholecystectomy on the sphincter of Oddi was investigated in biliary group III patients who were potential sufferers of postcholecystectomy syndrome. Common bile duct pressures in 62 cholelithiasis patients were recorded by means of a catheter introduced through the cystic duct after open cholecystectomy. The upper limit of normal choledochal pressure was hypothesized to be 15cm H<sub>2</sub>O. The perfusion pressures were above this limit in 15 patients. The first 7 patients formed the

study group and the subsequent 8 patients were the controls. Hepatic plexus vagotomy was performed on the patients in the study group. The mean decrease of common bile duct pressure was 31.6% after hepatic plexus vagotomy and was significant ( $p < 0.001$ ). Neither right upper quadrant pain nor the pathologic symptoms due to vagotomy were reported in the study group during the follow up. Resisting right upper quadrant pain without an organic disorder was determined in 3 of the 8 patients in the control group and in 1 of the 47 remaining patients. Hepatic plexus vagotomy performed as an adjunct to cholecystectomy in biliary group III patients eliminates the sphincter spasm that is the cause of biliary tract pain and it may be an alternative treatment to sphincterotomy.

**Key Words:** Hepatic plexus, vagotomy, sphincter of Oddi, humans.

### Introduction

The causes of pain after cholecystectomy are various. Oddi's sphincter dysfunction has been implicated in 13 % of patients with right upper quadrant pain after cholecystectomy (1). Hogan and Geenen have classified right upper quadrant biliary type pain into three types. Biliary group I; these patients have biliary type pain, abnormal liver enzymes documented on two or more occasions, delayed drainage or dilated common bile duct. In this group, sphincter of Oddi stenosis is more likely than dyskinesia. Biliary group II; these patients have biliary type pain but have only one or two of the aforementioned criteria. In this group, the etiology may be stenosis or dyskinesia. Biliary group III; these patients have only biliary type pain and no other abnormalities. In this group, then pain may be due to sphincter of Oddi dyskinesia (2).

The sphincter of Oddi is innervated by both sympathetic and parasympathetic nervous systems. Whereas the role of the sympathetic system in regulating sphincter function appears to be minimal, at least under basal conditions, cholinergic stimulation appears to increase sphincter of Oddi activity (3). Hepatic plexus has branches of the left vagal nerve and is the most important nerve for motor functions of the biliary tract. Both gallbladder and sphincter of Oddi are contracted with stimulation of the hepatic plexus (4). Although experimentally, it was demonstrated in dogs that the choledochal pressure decreased after hepatic plexus vagotomy, to our knowledge, this is the first study on humans (5, 6).

The aim of this study was to determine the effect of hepatic plexus vagotomy as an adjunct to cholecystectomy on the sphincter of Oddi in biliary group

III patients who were potential sufferers of postcholecystectomy syndrome.

## Materials and Methods

Sixty-two cholelithiasis patients without choledocholithiasis or common bile duct dilatation were included in this study. These patients had normal liver function tests. All of them underwent open cholecystectomy. Later, a catheter (2 mm diameter) was introduced into the common bile duct through the cystic duct and this catheter was connected to a Caroli's manometer for the recording of common bile duct pressures. The choledochal perfusion pressure was recorded two minutes after the infusion of isotonic sodium chloride. Since normal baseline pressure reported in the literature is about 5 to 13 + 2 cm H<sub>2</sub>O (7-10), we hypothesized 15 cm H<sub>2</sub>O as the upper limit of normal choledochal pressure. The perfusion pressures were above this limit in 15 patients. The first 7 patients composed study group and the subsequent 8 patients were the controls. The hepatic plexus vagotomy was performed on the study group patients. The hepatic plexus consists of vagal fibers that extends towards the biliary tract through the lesser omentum separating from the left vagus nerve. These may show different anatomical variations (figure 1) but all of them pass through the lesser omentum. Therefore, the vagal branches passing through the lesser omentum were found and the hepatic plexus vagotomy was performed by cutting a piece of the lesser omentum. The common bile duct perfusion pressure was again recorded 20 minutes after this procedure. The hepatic plexus vagotomy was not performed on the control group or on those with choledochal pressures lower than 15 cm H<sub>2</sub>O.

## Results

The choledochal pressure decreased in all patients who underwent hepatic plexus vagotomy (table 1). The mean decrease of common bile duct pressure was 31.6% after hepatic plexus vagotomy and was significant ( $p < 0.001$ ). We followed up all patients for 18 to 24 months. Neither right upper quadrant pain after cholecystectomy nor the pathologic symptoms due to vagotomy were established in the patients who underwent hepatic plexus vagotomy. Resisting right upper quadrant pain was determined in 3 of the 8 patients in the control group and in 1 of the 47 remaining patients. An organic disorder or residual stone was not present in these patients. Liver enzymes were normal.

These 4 patients improved after endoscopic sphincterotomy.

## Discussion

There is clearly orchestration of sphincter of Oddi motility in concert with gastrointestinal tract motor activity and the interdigestive migrating motor complex. The gallbladder stores and concentrates hepatic bile during the fasting state and discharges stored bile during eating. Gallbladder filling is facilitated by tonic contraction of the sphincter of Oddi (3). The sphincter of Oddi regulates the pressure in the biliary tree and the flow of bile. The sphincter relaxes with increasing gallbladder pressure and permits the entrance of bile into the duodenum (11). The sphincter of Oddi has an intrinsic myogenic tonicity. The sphincter's basal tone is controlled by the vagal nerve. Electrical stimulation of the vagal nerve elicits contractile motor responses from the sphincter of Oddi. At the same time, it has been shown that after blockade of muscarinic cholinergic receptors with atropine, the vagally induced contractile response of the sphincter of Oddi was effectively antagonized (12). In this study, we determined that the choledochal pressure decreased in all patients who underwent hepatic plexus vagotomy. Although this is an indirect technique, the results are consistent with those reported in the literature.

The bile flows by secretion pressure of the liver after cholecystectomy. If there is sphincter of Oddi dyskinesia, the bile flow into the duodenum is difficult and the right upper quadrant pain called postcholecystectomy syndrome occurs (Biliary group III). Just as in a study of 56 postcholecystectomy patients, balloon distension of the common bile duct through the T tube resulted in pain in 45 patients (13). Hypertonic dyskinesia of the sphincter of Oddi is the most important factor in cases without organic causes such as choledocholithiasis, biliary structure, malignancy or papillary stenosis. In up to 30% of cases of so-called postcholecystectomy syndrome, functional disturbances of the sphincter of Oddi are responsible for the clinical picture (14). Similar investigations of the sphincter of Oddi in patients with recurrent idiopathic pancreatitis have demonstrated motility disorders in almost 90% of cases (15). Biliary group III patients have only biliary type pain and no other abnormalities. In this group, the pain is due to sphincter of Oddi dyskinesia (3). Endoscopic sphincterotomy in patients with postcholecystectomy syndrome as a result of sphincter of Oddi dysfunction is performed to decrease the choledochal pressure and to facilitate bile flow into

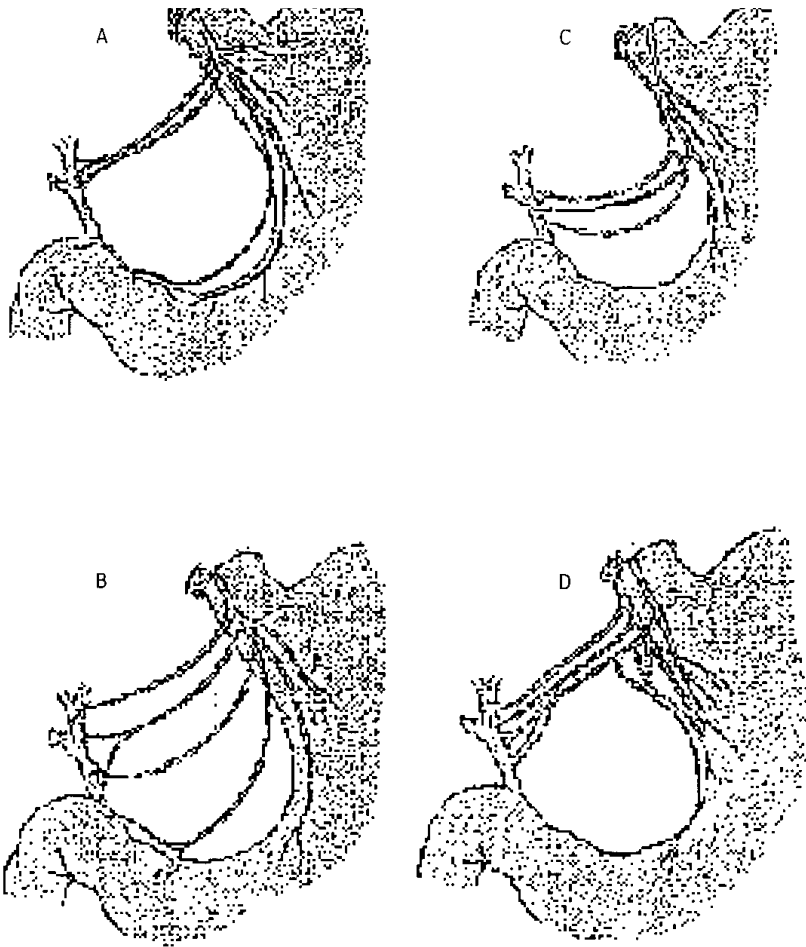


Figure 1. The anatomical variations of hepatic plexus.

the duodenum. In this way, it achieves permanent relief of symptoms (16). In our study, 4 patients with resisting right upper quadrant pain improved after endoscopic sphincterotomy. But the sphincter also acts as an important antireflux barrier that prevents duodenal contents from entering the common bile duct or pancreatic duct. It has been shown that duodenal biliary reflux revealed because of anatomic structure damaged after sphincterotomy and of this was an important route of infection in the biliary system (17). In opossums and cats, the pharmacologic inhibition of sphincter of Oddi contractions and basal tone with the smooth muscle relaxant sodium nitroprusside does not affect the unidirectional valvular action of the sphincter of Oddi (18, 19). This indicates that the mechanism for prevention of duodenobiliary reflux is independent of sphincter of Oddi smooth muscle contraction and is probably related to anatomic factors of the bilioduodenal junction (3). We inhibited only Oddi's sphincter contractions by hepatic

plexus vagectomy. The anatomic structure was not damaged as in sphincterotomy.

The choledochal sphincter is not present in animals with no gallbladder such as horses (20). This phylogenetic observation is significant because it reveals that constant bile flow into the duodenum unrelated to meals may be consistent with normal digestion. It is clear that sphincter of Oddi function after cholecystectomy is unnecessary and on the contrary, the removal of the sphincter of Oddi is advantageous. In the experimental studies performed on dogs, it has been demonstrated that the mean choledochal pressure decreased from 32% to 28% after hepatic plexus vagectomy (5, 6). Thus, the bile could easily flow into the duodenum. We hypothesized 15 cm H<sub>2</sub>O as the upper limit of normal choledochal pressure because normal pressure reported in the literature was 5 to 13 cm H<sub>2</sub>O and SD + 2 cm H<sub>2</sub>O (5-8). The mean decrease of choledochal pressure in patients who underwent hepatic plexus vagectomy was 31.6% after

Table 1. The changes of common bile duct pressures in the patients who underwent hepatic plexus vagotomy.

Patients	Common Bile Duct Pressures (cm H <sub>2</sub> O) Vagotomy		The decrease of common bile duct pressure	
	Before	After	cm H <sub>2</sub> O	%
1	20	14	6	30
2	16	11	5	31.2
3	18	10	8	44.4
4	17	12	5	29.4
5	16.5	10	6.5	39.4
6	19	15	4	21
7	17	12.5	4.5	26.4

vagotomy. Whereas the right upper quadrant pain was established in none of the patients in the study group, it was determined in 3 of the 8 control patients and in 1 of the 47 remaining patients. This may be evidence of being

an effective method of hepatic plexus vagotomy to prevent right upper quadrant pain after cholecystectomy in the biliary group III patients. Just as the improvement in these patients after endoscopic sphincterotomy shows that functional disturbance of the sphincter of Oddi is responsible for the clinical picture. Furthermore during the follow up, we did not determine any complications due to vagotomy. For these reasons, we decided that hepatic plexus vagotomy was both an effective and safe method providing a regular flow of bile into the duodenum with undamaged anatomic structure.

We performed this method in open cholecystectomy. However, we are of the opinion that it can easily be performed in laparoscopic cholecystectomy too. In conclusion, hepatic plexus vagotomy performed as an adjunct to cholecystectomy in biliary group III patients eliminates the sphincter spasm that is the cause of biliary tract pain and it may be an alternative to sphincterotomy. But further studies are required.

**References**

1. Botoman VA, Kozarek RA, Novell LA et al. Long-term outcome after endoscopic sphincterotomy in patients with biliary colic and suspected sphincter of Oddi dysfunction. *Gastrointest Endosc* 1994; 40: 165-70.
2. Hogan WJ, Geenen JE. Biliary dyskinesia. *Endoscopy* 1988; 20: 179-83.
3. Chuttani R, Carr-locke DL. Motility and dysmotility of the biliary tract and sphincter of Oddi. In: Sleisenger MH, Fordtran JS eds. *Gastrointestinal disease*. W.B. Saunders Co. Philadelphia, 1993, pp: 1777-1788.
4. Schein CJ, Benevantonio TC. Choledochal dynamics in man. *Surg Gynecol Obstet* 1968; 126: 591-6.
5. Amdrup BM, Griffith CA. The effects of vagotomy upon biliary function in dogs. *J Surg Res* 1970; 10: 209-12.
6. Şener M, Çilingiroğlu K. The influence of hepatic plexus vagotomy as an adjunct to cholecystectomy on the sphincter of Oddi (Experimental study in dogs). *Turkish J Surg* 1986; 3: 31-8.
7. Gregg JA, Carr-Locke DL. Endoscopic pancreatic and biliary manometry in pancreatic, biliary, and papillary disease, and after endoscopic sphincterotomy and surgical sphincteroplasty. *Gut* 1984; 25: 1247-54.
8. Carr-Locke DL. Sphincter of Oddi manometry: the control population. *Ital J Gastroenterol* 1985; 17: 341-5.
9. Meshkinpour H, Mollot M, Eckerling GB, Bookman L. Bile duct dyskinesia: clinical and manometric study. *Gastroenterology* 1984; 87: 759-62.
10. Toouli J, Roberts-Thomson IC, Dent J, Lee J. Manometric disorders in patients with suspected sphincter of Oddi dysfunction. *Gastroenterology* 1985; 88: 1243-50.
11. Gadacz TR. Anatomy and physiology of the gallbladder and extrahepatic biliary ducts. In: Shackelford RT, Zuldema GD eds. *Surgery of the alimentary tract*. W.B. Saunders Co. Philadelphia, 1983, pp 163-71.
12. Dahlstrand C. The vagal nerves and peptides in the control of extrahepatic biliary motility. An experimental study in the cat. *Acta Physiol Scand Suppl* 1990; 589: 1-52.
13. Doran FS. The sites to which pain is referred from the common bile duct in man and its implication for the theory of referred pain. *Br J Surg* 1967; 54: 599-606.
14. Brandstatter G, Kratochvil P, Wurzer H. Dysfunction of the sphincter of Oddi as a cause of so-called postcholecystectomy syndrome. *Wien Klin Wochenschr* 1991; 103: 577-80.
15. Tooli J, Roberts-Thomson IC, Dent J, Lee J. Sphincter of Oddi motility disorders in patients with idiopathic recurrent pancreatitis. *Br J Surg* 1985; 72: 859-63.

16. Chuttani R, Carr-lock DL. Pathophysiology of the sphincter of Oddi. *Surg Clin North Am* 1993; 73: 1311-22.
17. Sung JY, Leung JW, Shaffer EA et al. Ascending infection of the biliary tract after surgical sphincterotomy and biliary stenting. *J. Gastroenterol Hepatol* 1992; 7: 240-5.
18. Calabuig R, Ulrich-Baker MG, Moody FG, Weems WA. The propulsive behavior of the opossum sphincter of Oddi. *Am J Physiol* 1990; 258: 138-142.
19. Calabuig R, Weems WA, Moody FG. Choledochoduodenal flow: Effect of the sphincter of Oddi in opossums and cats. *Gastroenterology* 1990; 258: 138-142.
19. Calabuig R, Weems WA, Moody FG. Choledochoduodenal flow: Effect of the sphincter of Oddi in opossums and cats. *Gastroenterology* 1990; 99: 1641-6.
20. Didio LJA, Boyden EA. The choledochoduodenal junction in the horse, a study of the musculature around the ends of the bile and pancreatic ducts in a species without a gallbladder. *Anatomy records* 1962; 143: 61-6.