

Mustafa ÖZTÜRK¹
Okkeş İbrahim KARAMAN¹
Ahmet Candan DURAK¹
Nevzat ÖZCAN¹
Mustafa KÜÇÜKAYDIN²

Uterus Didelphys With an Obstructed Hemivagina and Ipsilateral Renal Agenesis

¹Department of Radiology, Hospital of Erciyes University, Medical Faculty, Kayseri-Turkey

²Department of Pediatric Surgery, Hospital of Erciyes University, Medical Faculty, Kayseri-Turkey

Received: November 12, 1996

Uterus didelphys with an obstructed hemivagina is always associated with renal agenesis, mostly ipsilateral to the blind vaginal pouch(1). In the present report, magnetic resonance (MR) imaging features of this rare syndrome are described.

A review of the literature reveals that 125 cases of this complex malformation have been reported (2). Patients who have this malformation usually complain of a pelvic mass and severe dysmenorrhea. We report a similar case who has Müllerian duct anomalies associated with renal agenesis and accumulation of seropurulent fluid (probably sedimentated and infected menstrual blood) in the obstructed vagina.

A 14 year-old-girl was admitted to the department of pediatric surgery, due to severe vaginal discharge and recurrent left lower abdominal pain for the past 11 months. The patient had regular menstrual periods. Her menarche was 14 months prior to admission. Past medical history included several episodes of vaginal discharges.

Physical examination was normal. Pelvic examination showed an intact hymen and normal external genitalia and introitus. Rectal examination revealed a tender, left sided pelvic mass.

Pelvic ultrasonography demonstrated two separate uterine bodies and a cystic mass of 38x23x25 mi-

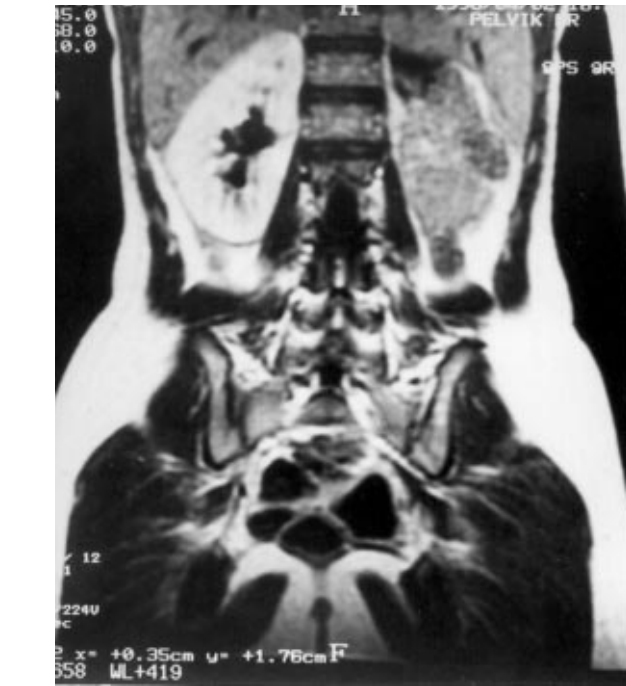

Figure 1. T1-W coronal image. Left renal agenesis and enlarged right kidney.

limeters, located on the left side posterior to the vagina. Left kidney could not be found ultrasonographically. It was not visualised on excretory urography or scintigraphy, either.

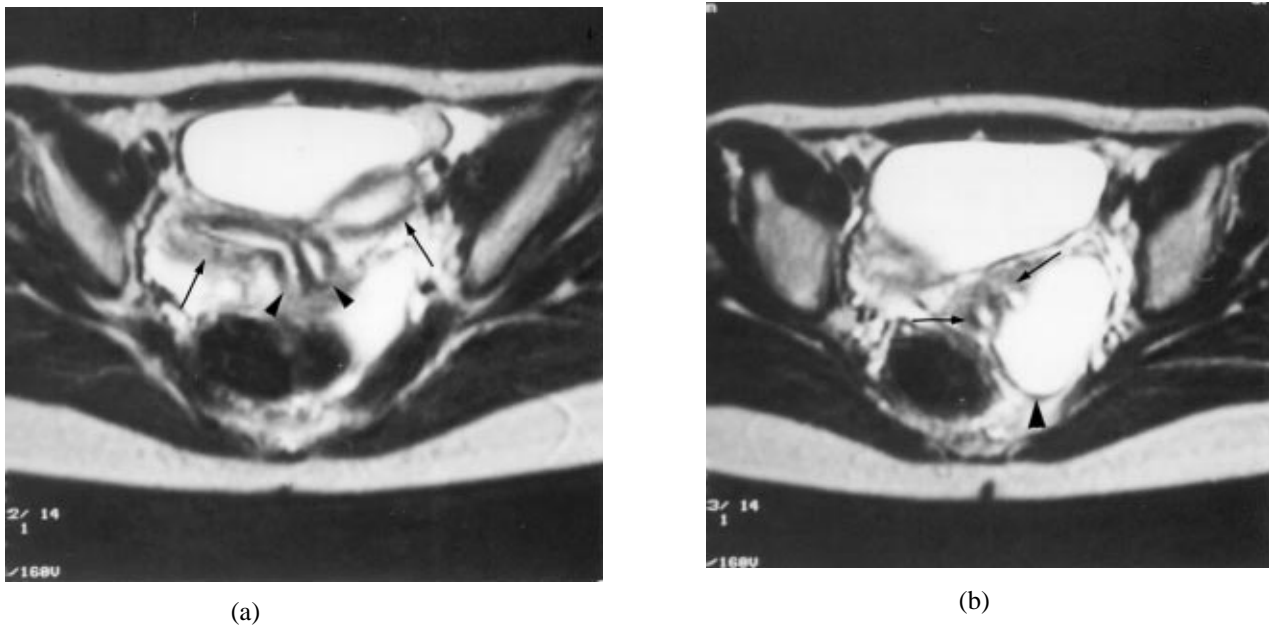


Figure 2. T 2-W axial image. A. Separate uterine horns (arrows) and two adjacent cervixes (arrowheads). B. Two adjacent cervixes (arrows) and left posterolaterally loculated hyperintense menstrual blood (arrowhead)

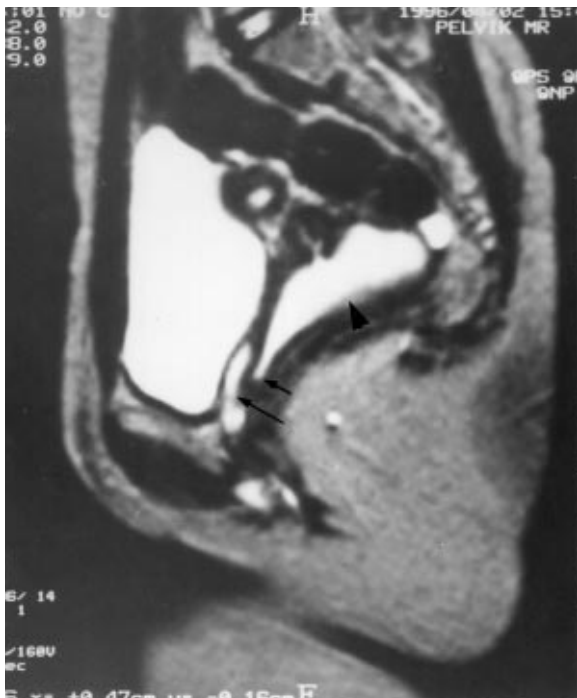


Figure 3. T2-W sagittal image. Hyperintense loculated menstrual blood (arrowhead), left obstructed hemivagina (short arrow) and right patent hemivagina (long arrow).

MR scanning was performed to demonstrate the anatomical details with a General Electric 0.5 T Vectra

System. T1 weighted (TR/TE; 600/23) and T2 weighted (TR/TE; 5000/110) images were obtained in axial, coronal, and sagittal planes.

On T1W images, right kidney was enlarged and there was a left renal agenesis (Figure 1). On T2W images, two separate uterine horns adjacent to two cervixes, endometrial linings as two separate linear high signal intensities within uterine horns and the septum extending through the cervix as a low signal intensity are seen. (Figure 2). Sagittal images showed the obstructed hemivagina containing loculated menstrual blood as a hyperintense area. The right hemivagina is patent (Figure 3).

The patient underwent laparotomy. The findings of our examination have been confirmed and seropurulent fluid was aspirated which was thought to be hematocolpos. The septum between the cystic mass and the vagina was excised. The patient was discharged a few days later and remains asymptomatic since then.

Uterus didelphys with an imperforate hemivagina is an embryonic malformation of the genitourinary system of the female occurring between the 12th and

16th weeks of pregnancy (3). The Müllerian ducts, just lateral to the Wolffian (mesonephric) ducts, grow towards to the midline and come into contact with each other. Then they fuse and continue to grow downwards. Completing the fusion, they join the urogenital sinus. When fusion is complete, by the 16th week, the uterus, fallopian tubes on each side and vagina down to the hymenal ring are formed (4).

If one of the Wolffian ducts is absent, ipsilateral kidney and ureter will fail to develop. The Müllerian ducts may also fail to fuse in the midline, either completely or incompletely. If the failure to fuse is complete a uterus didelphys is formed. The Müllerian duct on the side where Wolffian duct is absent, displaces itself laterally and cannot come into contact with the urogenital sinus in the center. Thus, the contralateral Müllerian duct gives way to a vagina, while its already displaced component on the other side forms a blind sac, i.e. an imperforate or obstructed hemivagina. The part of the vagina distal to the hymenal ring which derives itself from the urogenital sinus is not affected (5).

MR imaging is an ideal modality for evaluation of such congenital anomalies of the genital tract. Be-

fore the introduction of MR imaging, diagnostic laparoscopy was often necessary to fully define the abnormal anatomy because other imaging studies proved usually inconclusive. More invasive diagnostic procedures are so avoided (6).

For MR evaluation, it is important to obtain scans sagittally and coronally through the corpus uteri. Standard axial scans may be insufficient to demonstrate the endometrial cavity or fundal contour because the uterus can vary in its degree of antelexion or retroflexion. Uterus didelphys is easily diagnosed when two separate uteri and adjacent two cervixes are visualised (7).

The first treatment of the obstructed hemivagina is incision of the obstructing septum providing adequate drainage to the retained blood. In a further operation, vaginal septum should be excised totally resulting in a single vagina with two cervixes (8). If surgery is delayed hemihysterectomy with or without salpingo-oophorectomy may become necessary because of continued retrograde menstruation leading to hematometra, hematosalpinx. Therefore early diagnosis and proper treatment is crucial for the fertility and life expectancy.

References

- Miyazaki Y, Ebisuno S, Eukado Y, Ogawa T, Senzaki A, Ohkawa T. Uterus didelphys with unilateral imperforate vagina and ipsilateral renal agenesis. *J Urol* 135:107-9, 1986.
- Stassart JP, Nagel TC, Prem KA, Phipps WR. Uterus didelphys obstructed hemivagina and ipsilateral renal agenesis: The University of Minnesota experience. *Fertil Steril* 57:756-61, 1992.
- Chaim W, Kommehl P, Kopernik G, Meizner I. Uterus didelphys with unilateral imperforate vagina and ipsilateral renal agenesis: The challenge of non-invasive Diagnosis. *J Clin Ultrasound* 19:583-85, 1991.
- Hording U, Legarth J. Uterus didelphys with a unilateral imperforate hemivagina and ipsilateral renal agenesis. *Acta Obstet Gynecol Scand* 66:277-8, 1987.
- Erdoğan E, Okan G, Daragenli Ö. Uterus didelphys with unilateral obstructed hemivagina and renal agenesis on the same side. *Acta Obstet Gynecol Scand* 71: 76-7, 1992.
- Dietrich RB. Pediatric Body imaging. Stark DD, Bradley WG Jr, Eds. *Magnetic resonance imaging*. St Louis: Mosby-Yearbook. 1992, pp:2086-89.
- Scoutt LM, Mc Carthy SM. Female pelvis. In: Stark DD, Bradley WG Jr, Eds. *Magnetic resonance imaging*. St Louis: Mosby-Yearbook. 1992, pp:1956.
- Broseta E, Boronat F, Ruiz JL, Alonso M, Osca JM, Jimenez-Crus JF. Urological complications associated to uterus didelphys with unilateral hematocolpos. *Eur Uro* 20:85-8, 1991.