

Bülent DİNÇ  
Ayhan DİNÇKAN  
Ayhan MESÇİ  
Taner ÇOLAK  
Cumhur ARICI  
Alihan GÜRKAN

## Relapsing giant liposarcoma originating in the chest wall

**Abstract:** Liposarcomas are usually seen in the retroperitoneal region and in extremities, but can be seen in the head, neck, inguinal region, and chest wall less frequently. In this report, a relapsing giant liposarcoma weighing 9 kg and with a diameter of 50 cm originating in the chest wall is discussed.

**Key words:** Liposarcoma, chest wall, relapse

### Göğüs duvarından kaynaklanan nüks dev liposarkom

**Özet:** Liposarkomlar genellikle ekstremiteler ve retroperitoneal bölgede görülürken, baş, boyun, inguinal bölge ve göğüs duvarında da daha nadir görülebilirler. Bu vaka sunumunda göğüs duvarından kaynaklanan 50 cm çapında ve 9 kg ağırlığında nüks dev liposarkom olgusu tartışılmıştır.

**Anahtar sözcükler:** Liposarkom, göğüs duvarı, relaps

Department of Surgery,  
Faculty of Medicine,  
Akdeniz University,  
Antalya - TURKEY

### Introduction

Soft tissue sarcomas originating in mesenchymal tissue are rarely seen and account for only 1% of malignant tumors (1). Malignant fibrous histiocytomas and liposarcomas are the most common soft tissue sarcomas, with liposarcomas accounting for 20% (2). Liposarcomas are usually seen in the retroperitoneal region and in extremities, but can be seen in the head, neck, inguinal region, and chest wall less frequently. Involvement of the chest wall is observed the least, with a frequency of 3% (3). Two-thirds of the patients are over 40 years of age. Complete surgical resection is the recommended therapy. Radiotherapy can be used palliatively for prevention of early recurrences (4). In this report, a relapsing giant liposarcoma weighing 9 kg and with a diameter of 50 cm is discussed with the relevant data in the literature.

Received: March 14, 2008  
Accepted: April 17, 2009

### Case Report

An 80-year-old male was admitted with fatigue, weight loss, and a swelling originating in his left chest wall and extending to his left axilla and back. Ten years before, because of liposarcoma, the patient had been operated on 4 times at different centers. He had hypertension and congestive heart failure, and his physical examination revealed a hard, large mass extending from the left front chest wall to the left axillary region and back with a transverse diameter of 65 cm (Figure 1).

Chest radiography showed a nonspecific intensification on soft tissue and effacement in basilar regions of the left hemithorax. On thoracoabdominal computerized tomography (CT) scan with opaque material, a giant mass was seen extending towards the fossa axillaris and left breast at the left thoracal level. The mass was heterogeneous and rich in fat tissue (Figure 2). No finding on chest

#### Correspondence

Ayhan DİNÇKAN  
Department of Surgery  
Faculty of Medicine  
Akdeniz University  
07059 Antalya - TURKEY

adinckan@akdeniz.edu.tr

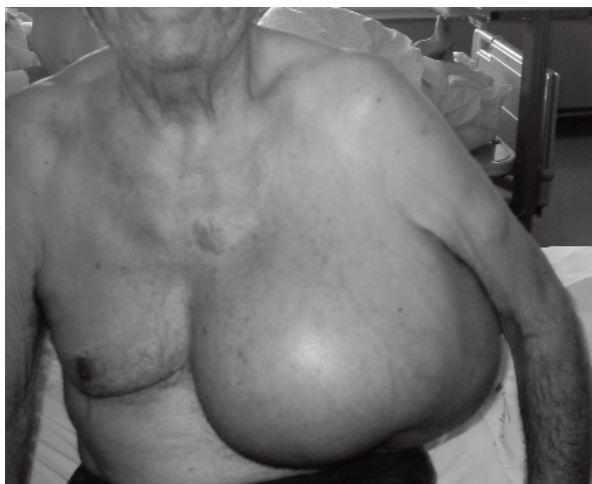

Figure 1. The hard mass which extends from the chest anterior wall to the left axillary.

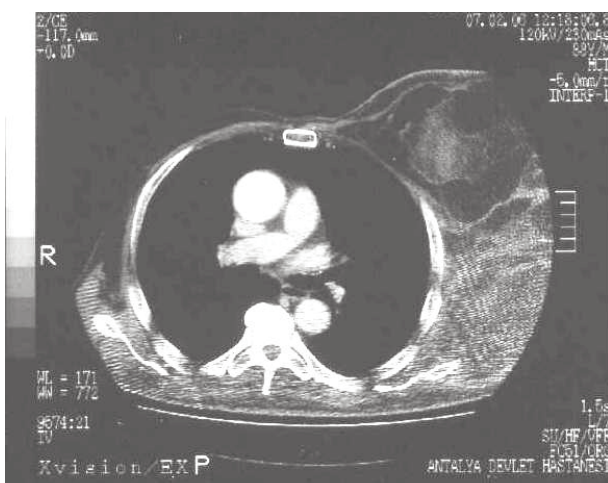


Figure 2. The giant soft tissue mass, which is at the level of the left anterior and lateral thorax wall on CT imaging, and expands to the axillar fossa and breast area.

radiography or thoracoabdominal CT scan was consistent with metastatic tissue.

Intraoperative frozen section analysis confirmed the mass to be a liposarcoma, and a wide resection, with 2 cm intact tissue around tumor border, was performed (Figure 3). Histopathological examination determined that the mass was a high-grade undifferentiated liposarcoma containing atypical lipoblasts, weighing 9 kg,  $50 \times 27 \times 12$  cm in diameter, and with 50% necrotic areas. Owing to the fact that the surgical borders were negative, re-excision was not performed. The patient had no recurrences during the

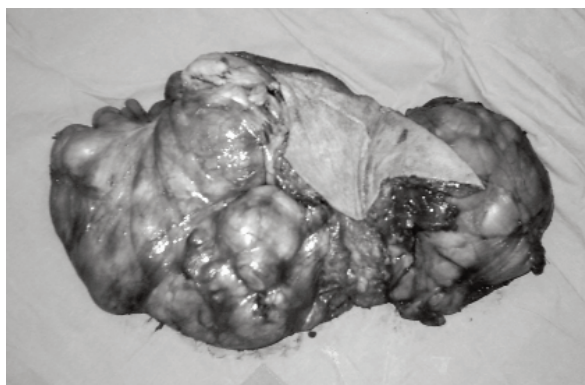

Figure 3. The macroscopic image of the specimen after resection.

follow-up but died 11 months after the last operation due to cardiopulmonary causes.

### Discussion

Sarcomas can be divided into 2 groups, soft tissue sarcomas and primary osteoid sarcomas, each of which has different staging and treatment approaches. Soft tissue sarcomas, which account for less than 1% of all malignant tumors, can be derived from skin and other organs as well as soft tissues. The most common subgroups of soft tissue sarcomas are malignant fibrous histiocytomas, liposarcomas, and leiomyosarcomas (1). Liposarcoma is the most common subtype, accounting for 20% of all soft tissue sarcomas (2). Although radiation, chronic lymphedema, some chemicals (vinyl chloride), and a number of genetic disorders (neurofibromatosis and von Recklinghausen syndrome) are blamed for sarcomas, etiological factors for liposarcomas are not yet clarified (1). Patients are usually over 40 years old, as in the present case (4).

Liposarcomas usually originate in the extremities and the retroperitoneum, less frequently in the head, neck, and inguinal region, and rarely in the thorax. The frequency of liposarcomas derived from the chest wall is about 3%, and liposarcomas account for 15% of all sarcomas derived from the chest wall (3). Liposarcomas develop from mesenchymal cells rather than mature lipocytes and are mostly seen in the retroperitoneum and deep tissue of the lower extremities (75%) (5).

Liposarcomas are tumors that enlarge slowly to gigantic dimensions with local invasion. If the tissue they originate in is easily seen, patients develop an asymptomatic mass. If there is neural invasion, the major symptom can be pain (1). It is reported that 85% of liposarcoma cases derived from the chest wall are with local enlargement and/or invasion, whereas 15% of them are diagnosed incidentally during routine chest radiography (6). Liposarcomas are usually gigantic. There have been reports in the literature of liposarcomas measuring 6-40 cm and weighing approximately 1500 g (3). In this case, the liposarcoma measured 50 × 27 cm and weighed 9000 g and thus may represent the largest liposarcoma originating in the chest wall in the literature to date.

While liposarcomas can be diagnosed by CT scan and magnetic resonance imaging (MRI), the latter is superior for differential diagnosis of benign lipomas and liposarcomas. A sufficient tissue specimen must be obtained during biopsies (open or thick needle core biopsy) for pathological diagnosis of sarcomas (1). In this case, no MRI or biopsies were conducted since pathological reports were available. The diagnosis was confirmed by intraoperative frozen section biopsy and total excision was performed.

Different types of liposarcomas have been identified, as well-differentiated, round cell, dedifferentiated, and pleomorphic (7). Dedifferentiated liposarcomas originating from well-differentiated liposarcomas, frequently seen in the retroperitoneal region, are high-grade tumors with aggressive progression (1). Grading of liposarcomas is the most valuable predictor for local invasion and survival (8). The present case was a dedifferentiated liposarcoma showing a random localization in the chest wall and with the unique feature of multiple recurrence.

The treatment of choice is surgical resection with negative surgical borders. Although radiotherapy may be beneficial for huge and high-grade tumors in order to decrease local invasion, it does not cause an increase in survival. Chemotherapy can be used to minimize the tumor tissue preoperatively or to prevent local invasion postoperatively (1). Surgical resection is the preferred treatment for sarcomas. Although wide resection is the choice of surgery, definition for wide resection is variable in the literature. Some studies showed that the surgical margin has no direct effect on survival. Due to the massive dimensions of the tumor, negative margins were obtained as far as possible (9). The primary prognostic factors for sarcomas are grade, extent, and primary localization of the tumor (8). Local lymphatic nodule involvement appears rarely and is a criterion of poor prognosis (10). Survival after surgical resection in patients with soft tissue sarcomas originating in the chest wall is comparable to that reported for sarcomas originating in extremities. In our case, a relapse was seen after 4 resections and the liposarcoma caused cosmetic complications due to its gigantic dimensions. After resection of the tumor, no radiotherapy or chemotherapy was administered due to the patient's advanced age.

In conclusion, primary soft tissue sarcomas of the chest wall are seen rarely and there are limited data regarding the treatment and consequences of these tumors. For these tumors, which become gigantic and have frequent local invasions, complete surgical resection with negative surgical borders is recommended for treatment. The effects of radiotherapy and chemotherapy are not clear. In patients with high-grade and differentiated tumors, strict follow-up is advised because of frequent recurrence.

## References

1. Skubitz KM, D'adamo DR. Sarcoma. *Mayo Clin Proc* 2007; 82: 1409-32.
2. Jemal A, Siegel R, Ward E, Murray T, Xu J, Smigal C et al. Cancer statistics. *CA Cancer J Clin* 2006; 56: 106-30.
3. Enzinger FM, Weiss SW. In: *Soft tissue tumors*, 3rd ed. St. Louis: Mosby; 1995.431-66.
4. Karamustafaoglu YA, Güngör A. Giant soft tissue liposarcoma of chest wall. *J Thorac Cardiovasc Surg* 2005; 129: 1189-90.
5. Dei Tos AP, Mentzel T, Fletcher CDM. Primary liposarcoma of the skin: a rare neoplasm with unusual high grade features. *Am J Dermatopath* 1998; 20: 332-38.

6. Schweitzer DL, Aguan AS. Primary liposarcoma of the mediastinum. Report of a case and review of the literature. *J Thorac Cardiovasc Surg* 1977; 74: 83-97.
7. Fletcher CD, Unni KK, Mertens F, eds. *World Health Organization Classification of Tumors*. Vol 5. Lyon, France: IARC Press; 2002.
8. Pisters PW, Leung DH, Woodruff J, Shi W, Brennan MF. Analysis of prognostic factors in 1,041 patients with localized soft tissue sarcomas of the extremities. *J Clin Oncol* 1996; 14: 1679-1689.
9. Gross JL, Younes RN, Haddad FJ, Deheinzelin D, Pinto CA, Costa ML. Soft-tissue sarcomas of the chest wall: prognostic factors. *Chest* 2005; 127: 902-8.
10. Fong Y, Coit DG, Woodruff JM, Brennan MF. Lymph node metastasis from soft tissue sarcoma in adults: analysis of data from a prospective database of 1772 sarcoma patients. *Ann Surg* 1993; 217: 72-77.