

Short Communication

Age-related Differences in Localization of Beta-defensin-2 in Human Gingival Epithelia

**Kenichi Matsuzaka, Daisuke Sato, Kazuyuki Ishihara,
Sadamitsu Hashimoto, Masao Yoshinari,
Akira Katakura and Takashi Inoue**

*Oral Health Science Center HRC7, Tokyo Dental College,
1-2-2 Masago, Mihama-ku, Chiba 261-8502, Japan*

Received 27 November, 2006/Accepted for publication 31 January, 2007

Abstract

Defensins are known to play an important role in defense against bacteria. It is also known that immunity against infection is compromised with age. The purpose of this study was to evaluate the localization of human beta-defensin (HBD)-2 in human gingival epithelia according to age. Gingival epithelia in maxillary premolar buccal normal regions was immunohistochemically stained for HBD-2. Specimens were divided into two groups: 6 cases in a young group (<20 years old) and 7 cases in an elderly group (>50 years old). Expression of HBD-2 in gingival epithelium in young subjects was mostly detected in the superficial layer of the parakeratinized layer, while some areas of the spinous cell layer in elderly subjects were positive for HBD-2, as was the superficial layer. Two cases in the young group and 5 cases in the elderly group immunoreacted with HBD-2 in the spinous cell layer. Furthermore, immunoreaction was stronger in the elderly group. The results revealed HBD-2 positive cells in spinous cells in the elderly group and in the parakeratinized layer in the young group.

Key words: Beta-defensin-2—Gingival epithelium—Aging

Introduction

Defensins are single-chain, strongly cationic peptides with a molecular weight of 34 kDa³⁾. They can be classified into alpha- and beta-defensins based on the sequence relationship of their three intermolecular disulfide bonds^{4,7)}. Alpha-defensins are expressed in neutrophils and intestinal Paneth cells¹⁰⁾. Human beta-defensins (HBDs) are mainly produced by the epithelial cells of many organs, including skin, lung, kidney, pancreas, uterus, eye, and nasal

and oral mucosa¹⁶⁾. Expression of the first three HBDs (HBD1–3) is well documented in oral tissues^{9,15)}. HBD-1 is constitutively expressed, and may be modulated by inflammation. HBD-2 and HBD-3 are inducible in cells with stimulation by pro-inflammatory cytokines such as IL-1beta, TNF-alpha, IFN-gamma and microorganisms^{2,14)}. Therefore, HBD-1 may influence normal epithelial interactions with the commensal flora, and HBD-2 and HBD-3 may participate in the host defense response to enteric microbes. HBD-2 was originally detected in

the skin of patients with psoriasis^{8,14}. Antimicrobial activity of natural beta-defensins has been observed against *Pseudomonas aeruginosa*, *Candida albicans* and so on.

Localized expression of HBD-2 was shown in both normal and inflamed oral epithelia¹². Although HBD-2 is expressed only in the presence of infection or inflammation in most tissues, including skin, trachea and gut epithelium, it is expressed in normal uninflamed oral epithelia^{8,11,14}. Therefore, oral epithelia may be the most appropriate site for observation of individual differences in HBD-2 expression. The production of defensins is an ancient defense mechanism. It is elicited by contact between microorganisms and epithelial cells, and is completely independent of leukocyte-dependent immune defense mechanisms¹⁵. HBD-2 plays an important role the defense against bacteria. However, immunity against infection is compromised with age, and there have been few reports about changes in the localization of HBD-2 associated with aging. Therefore, the purpose of this study was to evaluate the localization of HBD-2 expression in human gingival epithelia according to age.

Materials and Methods

Thirteen healthy specimens of gingival mucosa obtained from biopsies performed following diagnosis of epulis in the maxillary premolar buccal region were used in this study. The specimens were divided into two groups: one from subjects under 20 years of age as a young group (11-year-old female, 14-year-old female, 17-year-old female, two 17-year-old males, 19-year-old male) and the other from subjects over 50 years of age as an elderly group (two 59-year-old females, 72-year-old female, two 72-year-old males, 74-year-old female, 78-year-old male). Specimens were fixed in buffered 10% formalin, and then processed and embedded in paraffin. The embedded tissues were oriented such that approximately 5 μ m sections could be cut at 90 degrees to the epithelial surface. Specimens were chosen after confirmation that they were without candidi-

asis or other microinfections at the surface of the regions to be observed using PAS staining (data not shown). Immunohistochemical staining was then performed using a primary antibody to HBD-2 (1:100, Rabbit anti-beta defensin-2 (human), Peptide, Japan), and the specimens were observed by light microscopy at a site distant from the lesions. Informed consent was obtained for use of all specimens.

Results

HBD-2 expression was found in the cytoplasm of epithelial cells located throughout the upper spinous cell layer to the parakeratinized layer of the gingiva. Expression of HBD-2 in the gingival epithelium from young subjects was mostly in the superficial layer of the parakeratinized layer (Fig. 1a), while some areas of the spinous cell layer from elderly subjects were positive for HBD-2, as was the superficial layer (Fig. 1b). Two cases in the young group (Table 1) and 5 cases in the elderly group (Table 2) immunoreacted with HBD-2 in the spinous cell layers. Furthermore, HBD-2 immunoreaction was stronger in the elderly group.

Discussion

HBD-2 positive expression in the spinous cell layer suggests keratinization in elderly people. Sawaki *et al.*¹² found HBD-2 expression in the cytoplasm of epithelial cells throughout the upper spinous cell layer to the parakeratinized layer of the epithelia, both in normal skin and in buccal skin with candidiasis. Dale *et al.* reported that in adult human gingiva, HBD-2 expression occurred within well differentiated cells in the upper spinous and granular cell layers⁵. In this study, HBD-2 expression in the young group was mainly detected in the superficial layer of the gingival epithelium. Although HBD-2 is reportedly active against Gram-negative bacteria, it is also well known to exert an anti-microbial effect against *Escherichia coli*, *Pseudomonas aeruginosa*

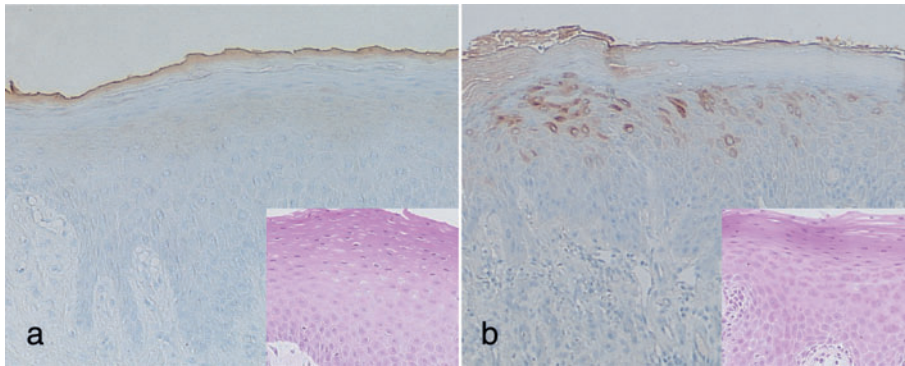


Fig. 1 Immunohistochemical staining of HBD-2 (Original magnification $\times 40$) and H-E staining in inset a: 14-year-old female; note that HBD-2 immunoreacted in superficial layer of parakeratinized layer. b: 74-year-old female; note that HBD-2 reacted not just in superficial layer, but in spinous cell layer also.

Table 1 HBD-2-positive area in young group

age sex	11 female	14 female	17 female	17 male	17 male	19 male
superficial layer	+	+	+	+	+	+
spinous layer	-	-	+	-	-	+

Table 2 HBD-2-positive area in elderly group

age sex	59 female	59 female	72 female	72 male	72 male	74 female	78 male
superficial layer	+	+	+	+	+	+	+
spinous layer	+	-	+	+	+	+	-

and *Candida albicans*^{3,12}). On the other hand, it is known that the prevalence of *Candida albicans* is higher in the elderly¹). Feng *et al.* obtained results supporting the hypothesis that HBD controls fungal colonization through hyphal induction, direct fungicidal activity and inhibition of candidal adherence⁶). In other words, candida and other microorganisms upregulate HBD-2 activity, widening localization of HBD-2. The higher frequency of bacteria carriers in elderly people is high, may be the reason for observation of HBD-2-positive cells in the spinous cell layer in elderly people. Although specimens without apparent candidiasis were used in this study,

these results suggest that the difference in expression of HBD-2 in elderly subjects and young subjects is a response to microorganisms. The turnover of oral epithelium in elderly people is slower, and single cell keratinization, metabolic abnormality in protein differentiation, can often be observed in the spinous cell layer in elderly people. This suggests that keratinocytes age before keratinization and single cell keratinization can be seen in the spinous cell layer. We believe this to be the reason that HBD-2 positive cells were observed in spinous cells in the elderly group, and in the parakeratinized layer in the young group.

Acknowledgements

The authors would like to thank Ms. Saori Takano for her technical assistance, and associate professor Jeremy Williams for his assistance with the English of the manuscript. This research was supported by Oral Health Science Center Grant HRC7 from Tokyo Dental College, (and) by a "High-Tech Research Center" Project for Private Universities: matching fund subsidy from MEXT (Ministry of Education, Culture, Sports, Science and Technology) of Japan, 2006–2010.

References

- 1) Abe S, Ishihara K, Okuda K (2001) Prevalence of potential respiratory pathogens in the mouths of elderly patients and effects of professional oral care. *Arch Gerontol Geriatr* 32:45–55.
- 2) Abiko Y, Jinbu Y, Noguchi T, Nishimura M, Kusano K, Amaratunga P, Shibata T, Kaku T (2002) Upregulation of human beta-defensin 2 peptide expression in oral lichen planus, leukoplakia and candidiasis. An immunohistochemical study. *Pathol Res Pract* 198: 537–542.
- 3) Bensch KW, Raida M, Magert HJ (1995) hBD-1: A novel beta-defensin from human plasma. *FEBS Lett* 368:331–335.
- 4) Bissell J, Joly S, Johnson GK, Organ CC, Dawson D, McCray PB Jr, Guthmiller JM (2004) Expression of beta-defensins in gingival health and in periodontal disease. *J Oral Pathol Med* 33:278–285.
- 5) Dale BA, Kimball JR, Krisanaprakornkit S, Roberts F, Robinovitch M, O'Neal R, Valore EV, Ganz T, Anderson GM, Weinberg A (2001) Localized antimicrobial peptide expression in human gingiva. *J Periodontol Res* 36:285–294.
- 6) Feng Z, Jiang B, Chandra J, Ghannoum M, Nelson S, Weinberg A (2005) Human beta-defensins: differential activity against candidal species and regulation by *Candida albicans*. *J Dent Res* 84:445–450.
- 7) Ganz T, Lehrer RI (1995) Defensin. *Pharmacol Ther* 66:191–205.
- 8) Harder J, Bartels J, Christophers E (1997) A peptide antibiotic from human skin. *Nature* 387:861.
- 9) Joly S, Maze C, McCray PB Jr, Guthmiller JM (2004) Human beta-defensins 2 and 3 demonstrate strain-selective activity against oral microorganisms. *J Clin Microbiol* 42:1024–1029.
- 10) Lehrer RI (2004) Primate defensins. *Nat Rev Microbiol* 2:727–738.
- 11) Mathews M, Jia HP, Guthmiller JM, Losh G, Graham S, Johnson GK, Tack BF, McCray PB Jr (1999) Production of beta-defensin antimicrobial peptides by the oral mucosa and salivary glands. *Infect Immun* 67:2740–2745.
- 12) Sawaki K, Mizukawa N, Yamaai T, Fukunaga J, Sugahara T (2002) Immunohistochemical study on expression of alpha-defensin and beta-defensin-2 in human buccal epithelia with candidiasis. *Oral Dis* 8:37–41.
- 13) Schroder JM, Harder J (1999) Human beta-defensin-2. *Int J Biochem Cell Biol* 31:645–651.
- 14) Singh PK, Jia HP, Wiles K, Hesselberth J, Liu L, Conway BAD, Greenberg EP, Valore EV, Welsh MJ, Ganz T, Tack BF, McCray PB Jr (1998) Production of β -defensins by human airway epithelia. *Proc Natl Acad Sci USA* 95:14961–14966.
- 15) Wehkamp J, Harder J, Wehkamp K, Wehkamp-von Meissner B, Schlee M, Enders C, Sonnenborn U, Nuding S, Bengmark S, Fellermann K, Schroder JM, Stange EF (2004) NF-kappaB- and AP-1-mediated induction of human beta defensin-2 in intestinal epithelial cells by *Escherichia coli* Nissle 1917: a novel effect of a probiotic bacterium. *Infect Immun* 72:5750–5758.
- 16) Weinberg A, Krisanaprakornkit S, Dale BA (1998) Epithelial antimicrobial peptides: review and significance for oral applications. *Crit Rev Oral Biol Med* 9:399–414.

Reprint requests to:

Dr. Kenichi Matsuzaka
 Department of Clinical Pathophysiology,
 Tokyo Dental College,
 1-2-2 Masago, Mihama-ku,
 Chiba 261-8502, Japan
 Tel: +81-43-270-3581
 Fax: +81-43-270-3583
 E-mail: matsuzak@tdc.ac.jp