

Case Report

Nasolabial Flap Reconstruction of Floor of Mouth

Chihaya Ikeda, Akira Katakura, Nobuharu Yamamoto, Isao Kamiyama, Takahiko Shibahara, Norio Onoda* and Hidetoshi Tamura*

Department of Oral and Maxillofacial Surgery, Tokyo Dental College, 1-2-2 Masago, Mihama-ku, Chiba 261-8502, Japan

**Department of Oral and Maxillofacial Surgery, Kameda General Hospital, 929 Higashi-cho, Kamogawa City, Chiba 296-8602, Japan*

Received 6 July, 2007/Accepted for publication 28 November, 2007

Abstract

We treated two patients requiring nasolabial flap reconstruction.

The first patient was a 75-year-old man with mucoepidermoid carcinoma in the left-side floor of the mouth; requiring resection of the floor of the mouth, partial mandibulectomy, and left supraomohyoid neck dissection.

The second patient was a 74-year-old man with recurrent acinic cell carcinoma in the anterior oral floor infiltrating as far as the mandible. This patient required wide excision of the anterior part of the oral cavity, including amputation of the mandible.

After tumor resection, both cases had a nasolabial flap reconstruction. The post-operative course of both cases was good; neither postoperative flap necrosis nor infection developed.

Key words: Oral cancer—Oral reconstruction—Local flap—Nasolabial flap—Intraoral defect

Introduction

Resection of tumors in the anterior aspect of the oral cavity or the floor of the mouth may leave the patient with a significant functional and cosmetic defect. With T1 (maximum tumor size <2 cm) lesions, there are rarely problems, and they may be effectively dealt with by primary closure. However, defects resulting from resection of early T2 (maximum tumor size, 2–4 cm) lesions, or those requiring pull-through ablative technique, are often too large for this; and usually require distant or local flaps. Local flaps from the

tongue may be rotated into the defect. The tongue flap is readily available, and is well vascularized. However, its use interferes with normal tongue mobility, and may compromise speech and deglutition. Therefore, regional flaps are more popular, with favorite donor sites including the tongue, neck, and chest. These flaps provide the greatest potential amount of available tissue, but may be too bulky for smaller defects.

In our experience in reconstructing small defects in the anterior aspect of the oral cavity, the tunneled, inferiorly based nasolabial flap has been effective from both the aesthetic and

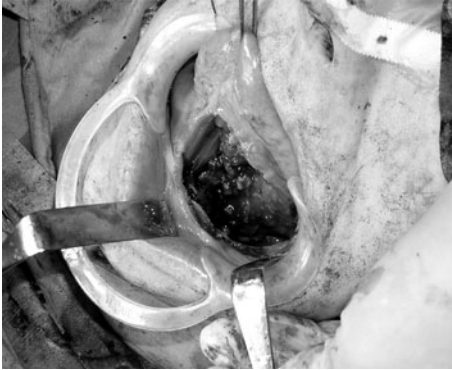

Fig. 1 Defect after resection of mucoepidermoid carcinoma on the left floor of the mouth

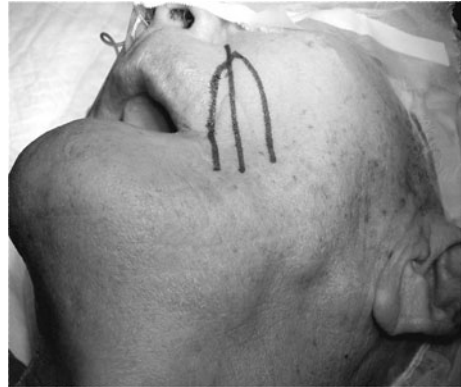

Fig. 2 The design of nasolabial flap is marked on left nasolabial folds. This flap is based inferiorly.

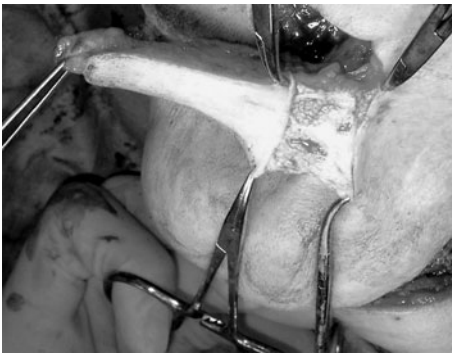

Fig. 3 The nasolabial flap that denuded one part of the subcutaneous tissue

functional points of view. This report describes the use of two types of nasolabial flap.

Case 1

A 75-year-old man with a mucoepidermoid carcinoma (maximum tumor size 3.5 cm and regional lymph nodes 2 cm: T2N2bM0) in the left-side floor of the mouth. The floor of the mouth was resected (Fig. 1), and left supraomohyoid neck dissection was performed. The tumor has been treated with *en bloc* local resection, including elective radical neck dissection by pull through method. The intraoral margins were reported as negative on frozen section examination. Postop-

eratively, the patient had a 5×3 cm defect in the floor of the mouth. During dissection, the facial artery, the submental artery, and external jugular vein were tied off in the superior aspect. Oral cavity reconstruction involved an inferiorly based nasolabial flap. The tip of the flap extended to a point approximately 10 mm from the medial canthus; the inferior 2.0 cm of the flap was de-epithelialized and formed into a subcutaneous pedicle flap (Fig. 2). A tunnel was created at the base through the soft tissue and buccal mucosa (Fig. 3). The tissue at the base was undermined, and adequate tunnel width was created to allow good flap mobility and prevent constriction of the flap. The flap was passed through the tunnel and sutured into place without tension. The donor site was then closed primarily. Since the flap was based on subcutaneous tissue, it had an anastomotic circulation that ensured a good blood supply. There were no postoperative complications, such as mobility restriction of the tongue or buccal mucosa. The patient's final appearance one year after surgery is shown in Fig. 4; the patient remains disease-free.

Case 2

The patient was a 74-year-old man with recurrent acinic cell carcinoma originating in

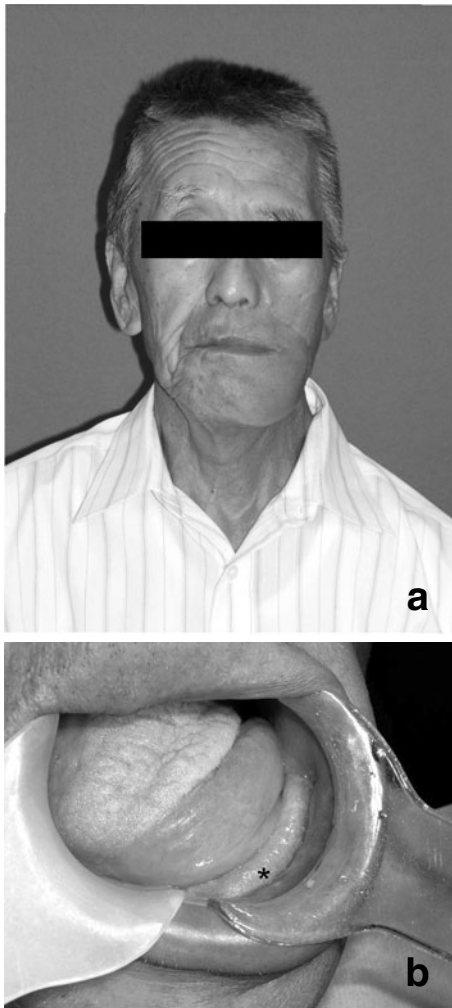


Fig. 4 A year after operation
There is no scar contracture, donor site morbidity or functional disability.
a: facial appearance, b: intraoral feature,
*: nasolabial flap

the anterior oral floor and infiltrating as far as the mandible. As he was seen in our clinic postoperatively, his initial TNM was unclear. Radiotherapy (total dose, 60 Gy) was used to treat the primary lesion. Four years later, an extending ulcer consisting of mandibular osteomyelitis (induced by radiotherapy) combined with acinic cell carcinoma was noted. The patient required a wide excision of the anterior aspect of the oral cavity, including amputation of the left mandibular ramus, and

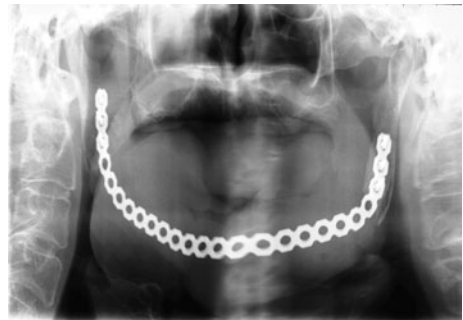

Fig. 5 The orthopantomography of post-operation
The mandibular body was resected.

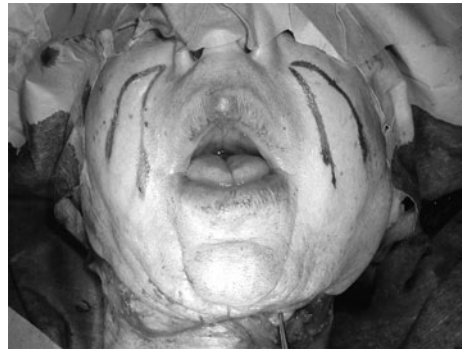

Fig. 6 The design of nasolabial flap is marked on bilateral nasolabial folds
Each nasolabial flap is based inferiorly.

reconstruction of mandibular bone by metal plate. (Fig. 5).

Each nasolabial flap was based inferiorly, with the hairless skin between the nose and the cheek providing a triangle of skin (Fig. 6). The flaps were raised and tunneled through the full thickness of the cheek, which created pedicles that allowed the flaps to be brought into an intraoral position. Therefore, the flaps could be placed alongside one another, with the tip of one flap against the base of the other flap. The flaps were raised with enough subcutaneous tissue to avoid facial nerve injury. This degree of cover functions well, even if bone and mucosa have been resected. The donor site was closed primarily.

The patient's final appearance one year after surgery is shown in Fig. 7; the patient

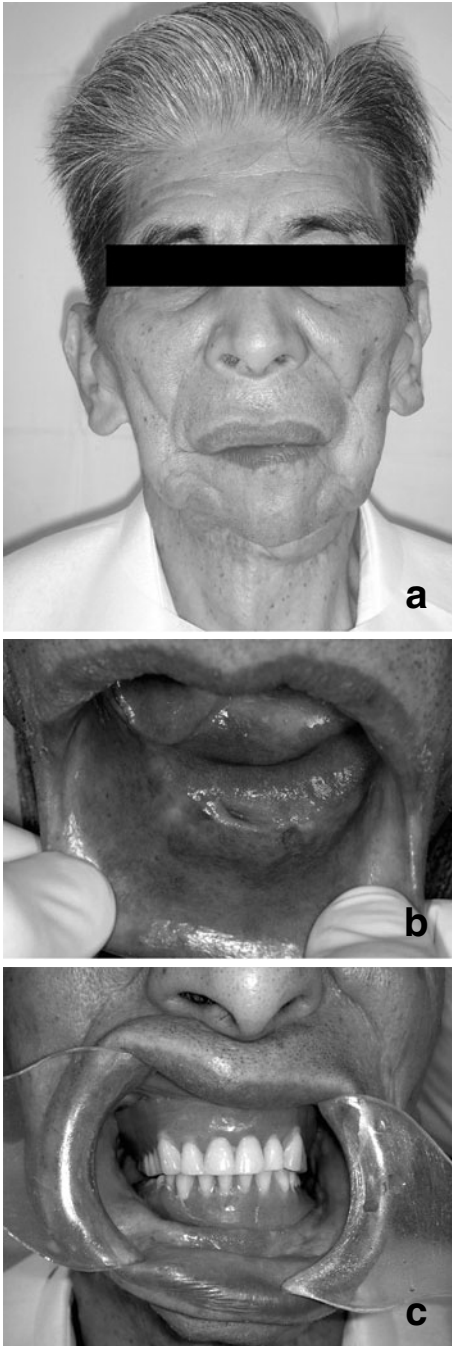


Fig. 7 The final aesthetic result a year after surgery is shown

The nature of the nasolabial flap allows a denture to be worn.

a: facial appearance, b: intraoral feature, c: patient worn the denture

remains disease-free. A pronounced spontaneous thinning of the initially bulky flap was observed, which allowed denture insertion. The donor site healed by primary intention without any complications.

Discussion

Recently, the development of the free flap with a vascular pedicle based on microsurgery and technical advances has greatly increased the choice of rebuilding methods that can be used to reconstruct postoperative defects in patients with head and neck tumors. However, microsurgical reconstruction requires a long operation time, and there is a waiting period after the initial resection. Therefore, it is not uncommon for the patient to become quite distressed. And, furthermore, these flaps are too large for intraoral defect.

Originally described by Thiersch²⁰ in 1868 and then modified by Esser⁹ in 1918, such flaps have been employed by a number of surgeons to close a variety of intraoral and facial defects^{7,22}. The specific use of the inferiorly based nasolabial flaps to repair mouth floor defects has been described by Cohen *et al.*, Edgerton *et al.*, and Zarem^{2,3,7,22}. The nasolabial flap is well suited for intermediate-size intraoral defects of the medial cheek, upper lip, palate, and anterior floor of the mouth.

There is controversy regarding the blood supply to the inferiorly based nasolabial flap¹³. Some authors have insisted on raising the nasolabial flap on the side contralateral to the radical neck dissection. We believe that the inferiorly based nasolabial island flap can be raised as a random pattern flap¹¹, as shown by its viability in cases with transected ipsilateral facial arteries¹⁴. The blood supply through the general anastomotic circulation is excellent¹⁰, so surgical delay is unnecessary. The combined use of such a nasolabial flap with a radical neck dissection does not jeopardize the flap's rich blood supply. The contribution made by vessels other than the facial artery is highlighted by the fact that the nasolabial flap can be successfully used, even after the ipsilateral

facial artery has been ligated³⁾. The inferiorly based nasolabial flap can also be used, even with an ipsilateral radical neck dissection. In fact, in the present case 1, an ipsilateral flap was raised.

For small defects of the floor of the mouth, the following flaps have been used: submental flaps^{6,15)}; platysma myocutaneous flaps^{1,4,5,17-19)}; pedicle flaps, such as buccal mucosa flaps which stem the facial artery; and free flaps, such as forearm flaps. However, while the use of the flap after neck dissection and radiation therapy is difficult, reconstruction using micro-surgically anastomosed flap surgery can place a heavy burden on the patient^{1,5,18)}. When the tumor size is under 2 cm, primary closure is sufficient to close the defect, but often causes functional disorder, such as tongue motor deficit.

The flap ensures a supple oral cavity floor, thereby providing for maximum mobility of the remaining tongue. As can be seen in case 2, these flaps also provide excellent cover for exposed irradiated mandible remaining after removal of the alveolus or inner cortex¹³⁾. In our two cases, the donor site was readily closed primarily, leaving only a small, residual cosmetic deficit. In fact, in an elderly patient, lip support is improved, and facial appearance can actually be made more appealing. Unilateral or bilateral flaps may be employed. Unilateral nasolabial flap can cover a defect if the tumor size is up to 2 cm, whereas bilateral nasolabial flap is sufficient if the defect is up to 5×5 cm, as has been previously reported^{12,16)}.

A possible disadvantage of the technique is that there is occasional rotation of hair-bearing tissue into the oral cavity. This can be prevented by proper patient selection and outlining of the flap. Inaccurate evaluation of the size of the surgical defect may result in an inadequate amount of tissue being available for lining. If the deficit is small, mobilization of the tip of the tongue flap or adjacent tissues may allow for satisfactory closure. There is a strict limit to the lateral extent of the defect for which it is suitable. If either of these limitations exists, one of the other methods of reconstruction should be used^{8,13)}.

In our experience, the tunneled, inferiorly based nasolabial flap has been effective in the reconstruction of small defects in the anterior aspect of the oral cavity. This flap is simple, effective, and safe, with a low complication rate. Although other authors have reported complications (infection, minor or major flap necrosis, wound dehiscence) in a small minority of their patients¹²⁾, neither of our patients had any complications, and most authors have reported that the flaps healed without complication^{14,21)}. Furthermore, nasolabial flap reconstruction of the floor of the mouth brings satisfactory results from both the functional and aesthetic points of view. However, with a young patient, potential damage to the face must be taken into consideration. We believe that the usefulness of the nasolabial tunnel flap merits further study.

References

- 1) Berenholz L, Kessler A, Segal S (1999) Platysma myocutaneous flap for intraoral reconstruction: an option in the compromised patient. *Int J Oral Maxillofac Surg* 28:285-287.
- 2) Cohen IK, Edgerton MT (1971) Transbuccal flaps for reconstruction of the floor of the mouth. *Plast Reconstr Surg* 48:8-10.
- 3) Cohen IK, Theogaraj SD (1975) Nasolabial flap reconstruction of the floor of the mouth after extirpation of oral cancer. *Am J Surg* 130: 479-480.
- 4) Conley JJ, Lanier DM, Tinsley P Jr (1986) Platysma myocutaneous flap revisited. *Arch Otolaryngol Head Neck Surg* 112:711-713.
- 5) Cannon CR, Johns ME, Atkins JP Jr, Keane WM, Cantrell RW (1982) Reconstruction of the oral cavity using the Platysma myocutaneous flap. *Arch Otolaryngol Head and Neck Surg* 108:491-494.
- 6) Ducic Y, Burye M (2000) Nasolabial flap reconstruction of oral cavity defect: A report of 18 case. *J Oral Maxillofac Surg* 58:1104-1108.
- 7) Edgerton MT, DesPrez JD (1957) Reconstruction of the oral cavity in the treatment of cancer. *Plast Reconstr Surg* 19:89-113.
- 8) El Khatib K, Danino A, Trost O, Jidal B, Malka G (2005) Use of nasolabial flap for mouth floor reconstruction. *Ann Chir Plast Esthet* 50:216-220.
- 9) Esser JF (1918) Deckung von Gaumendefekten

- mittels gestielter Naso-Labial-Hautlappen. Dtsch ZschrChir 147:128–135.
- 10) Grate MR Jr, Hicks JN (1973) Nasolabial subcutaneous pedicle flap. South Med J 66:1234–1235.
 - 11) Hynes B, Boyd BB (1987) Axial or random? Arch Otolaryngol Head and Neck Surg 114: 1389.
 - 12) Ioannides C, Fossion E (1991) Nasolabial flap for the reconstruction of defect if the floor of mouth. Int J Oral Maxillofac Surg 20:40.
 - 13) Joshi A, Rajendraprasad JS, Shetty K (2005) Reconstruction of intraoral defects using facial artery musculomucosal flap. Br J Plast Surg 58:1061–1066.
 - 14) Lazaridis N (2003) Unilateral subcutaneous pedicled nasolabial island flap for anterior mouth floor reconstruction. J Oral Maxillofac Surg 61:182–190.
 - 15) Li Z (2005) Repairing defects of tongue and mouth floor with submental island flap after tumor surgery. Zhongguo Xiu Fu Chong Jian Wai Ke Za Zhi 19:786–788.
 - 16) Maurer P, Eckert AW, Schubert J (2002) Functional rehabilitation following resection of the floor of the mouth: the nasolabial flap revisited. J Cranio-Maxillofac Surg 30:369–372.
 - 17) McGuirt WF, Matthews BL, Brody JA, May JS (1991) Platysma myocutaneous flap: caveats reexamined. Laryngoscope 101:1238–1244.
 - 18) Persky MS, Kaufman D, Cohen NL (1983) Platysma myocutaneous flap for intraoral defect. Arch Otolaryngol Head and Neck Surg 109:463–464.
 - 19) Saito H, Tsuda G, Ohtsubo T, Noda I, Fujieda S, Saito T (1998) Platysma myocutaneous flap including the external jugular vein with special reference to neck dissection. ORL; J Otorhinolaryngol Relat Spec 60:218–223.
 - 20) Thiersch C (1868) Verschluss eines loches im harten gaumen durch die weichteile der wange. Archiv der Heilkunde 9:159–162.
 - 21) Vural E, Suen JY (2000) The submental island flap in head and neck reconstruction. Head Neck 22:572–578.
 - 22) Zarem HA (1971) Current concepts in reconstructive surgery in patients with cancer of the head and neck. Surg Clin North Am 51:149–173.

Reprint requests to:

Dr. Akira Katakura
 Department of Oral &
 Maxillofacial Surgery,
 Tokyo Dental College,
 1-2-2 Masago, Mihama-ku,
 Chiba 261-8502, Japan
 E-mail: katakura@tdc.ac.jp