

Case Report

Two Cases with Supernumerary Teeth in Lower Incisor Region

**Taishi Yokose, Teruo Sakamoto, Kenji Sueishi*,
Kenichi Yatabe*, Keiichirou Tsujino**, Shuhei Kubo***,
Masashi Yakushiji*** and Hideharu Yamaguchi**

*Department of Orthodontics, Tokyo Dental College,
1-2-2 Masago, Mihama-ku, Chiba 261-8502, Japan*

* *Division of Orthodontics,*

*Department of Clinical Oral Health Science, Tokyo Dental College,
2-9-18 Misakicho, Chiyoda-ku, Tokyo 101-0061, Japan*

** *Division of Pediatric Dentistry,*

*Department of Clinical Oral Health Science, Tokyo Dental College,
2-9-18 Misakicho, Chiyoda-ku, Tokyo 101-0061, Japan*

*** *Department of Pediatric Dentistry, Tokyo Dental College,
1-2-2 Masago, Mihama-ku, Chiba 261-8502, Japan*

Received 6 February, 2006/Accepted for publication 19 April, 2006

Abstract

Abnormalities in number of teeth are occasionally noted in clinical cases. Many theories have been proposed as regards the causes of the occurrence of supernumerary teeth, including atavism theory, mechanical tooth germ separation theory, tissue induction theory, and dental lamina morphological disturbance theory. However, none of these theories alone offers a sufficient explanation for this phenomenon. The incidence of supernumerary permanent teeth is approximately 1–3%. These are the maxillary anterior teeth, the maxillary molars, and the maxillo-mandibular premolars in terms of descending order of site of occurrence. On the other hand, incidence in the mandibular anterior tooth area, of which there have been few detailed reports, is about 0.01%, a markedly low value. In this paper, we report two rare cases of supernumerary teeth in the mandibular incisor area. We discuss their etiology and orthodontic treatment, and detail a differential diagnosis between the normal and supernumerary teeth. We found that it was difficult to establish a clear etiology and differentiation between the normal and supernumerary teeth.

Key words: Supernumerary teeth—Lower incisor—Etiology—Fused tooth—
Orthodontic treatment with supernumerary teeth

Introduction

In clinical cases, we often meet with a lot of

abnormal teeth. Stafne⁹⁾ reported that the incidence of supernumerary permanent teeth was about 1–3%. These were the maxillary

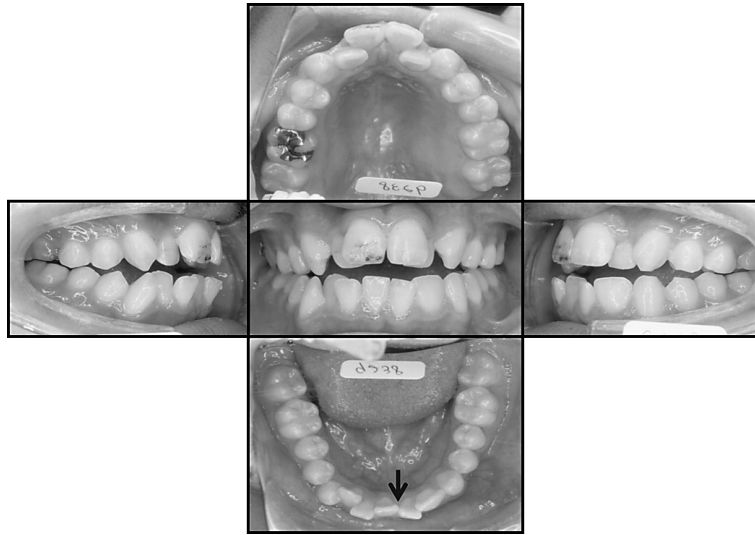


Fig. 1 Intraoral photographs
Mark shows mandible dental midline, determined by positional relationship of lingual frenum and inferior labial frenum.

anterior teeth, the maxillary molars, and the maxillo-mandibular premolars in descending order of occurrence. Incidence in the mandibular anterior tooth area is about 0.01%⁹⁾, a markedly low value. However, there have been few detailed reports^{3,6,8,10,11)} on the etiology of supernumerary teeth or differential diagnoses of normal and supernumerary teeth. In this paper, we report two cases of supernumerary teeth in the mandibular anterior tooth area.

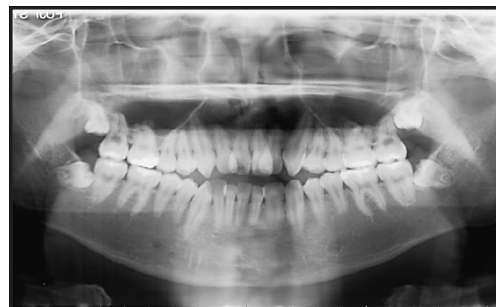


Fig. 2 Panoramic radiograph

Case History

Patient 1

The patient was a boy aged 16 years 11 months who visited our department chiefly complaining of maxillo-mandibular anterior tooth crowding. The molar occlusal relationship was Angle class I, and open bite and crowding were noted in the anterior tooth area. The patient had neither history of the disorder, nor family history of supernumerary teeth. Examination of the median area, as defined positionally by the relationship between the

lingual frenum, the inferior labial frenum, and the maxillo-mandibular bones, revealed a supernumerary tooth in the right mandibular lateral incisor region (Figs. 1 and 2). Furthermore, since the crown width of the left mandibular lateral incisor tooth was large, the tooth was morphologically regarded as a fused tooth (Figs. 3, 4 and 5). Orthodontic treatment was initiated, extracting the left mandibular fused tooth of the lateral incisor and the bilateral maxillo-mandibular first premolars.

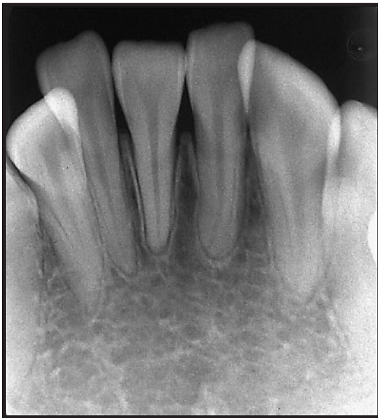

Fig. 3 Dental radiograph

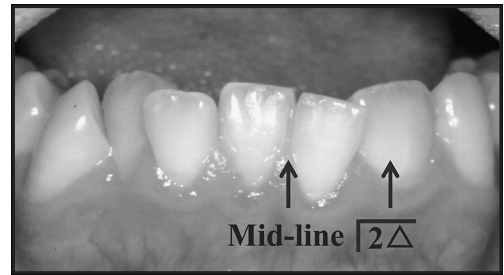


Fig. 4 Mandibular anterior

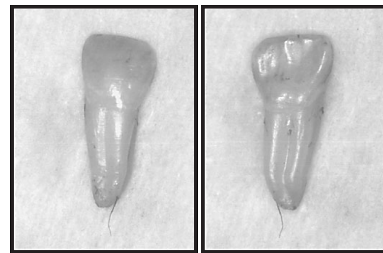


Fig. 5 $\overline{2\Delta}$ extracted teeth

Patient 2

The patient was a girl aged 13 years 1 month who visited our department chiefly complaining of maxillary anterior tooth protrusion and mandibular anterior tooth crowding. The patient had a left cleft lip, but had no family history of supernumerary teeth. The molar occlusal relationship was Angle class II, and maxillary protrusion and crowding were noted. Examination of the median area, as defined by the positional relationship between the lingual frenum, the inferior labial frenum, and the maxillo-mandibular bones, revealed a left supernumerary tooth and a right supernumerary tooth in the mandibular anterior tooth area (Figs. 6, 7 and 8). Treatment was performed, extracting two incisors and the bilateral maxillary first premolars. Two mandibular incisors in pronounced misalignment with the dental arch were selected for extraction.

Discussion

In patient 1, the fused tooth in the left mandibular lateral incisor area was considered to be a fused tooth comprising a lateral incisor and a supernumerary tooth. This was because the tooth crown width was larger than that of the adjacent incisors, and a longitudinal

groove in the central area of the tooth root was detected after extracting the tooth (Figs. 3, 4 and 5). Panoramic X-ray photographs were also used for the diagnosis. On the other hand, since the supernumerary tooth in the right mandibular lateral incisor region showed similar tooth crown morphology to that of normal incisors, without abnormal X-ray findings of the tooth root or pulp cavity, differentiation of a supernumerary tooth among the incisors was impossible. In patient 2, the tooth crown morphology of the bilateral supernumerary teeth was similar to that of normal incisors, and differentiation of supernumerary teeth was also impossible by X-ray observation of the tooth root and pulp cavity.

In determining which tooth is a supernumerary tooth among maxillary anterior teeth¹⁰, teeth with morphological abnormalities are regarded as supernumerary teeth, and when no morphological abnormalities are noted, the tooth with the minimum measurements among the anterior teeth is regarded as

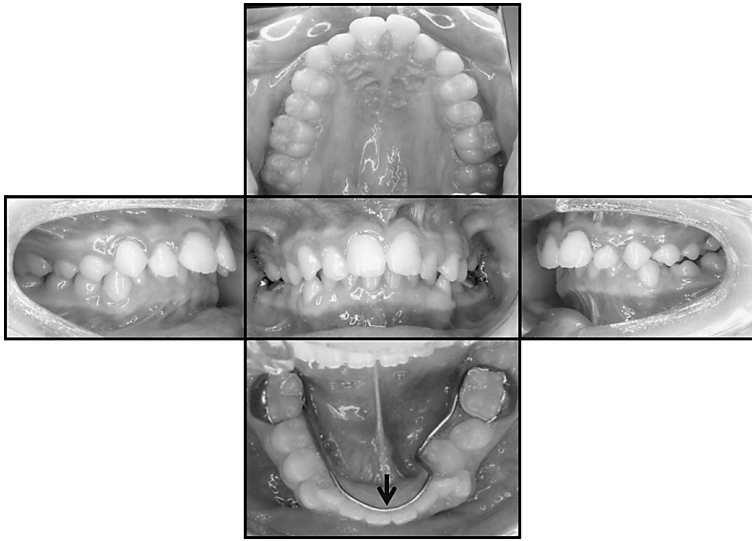


Fig. 6 Intraoral photographs
Mark shows mandible dental midline, determined by positional relationship of lingual frenum and inferior labial frenum.

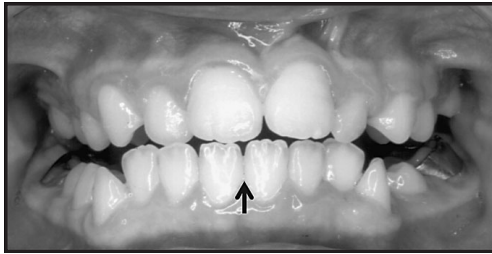


Fig. 7 Mark shows mandible dental midline

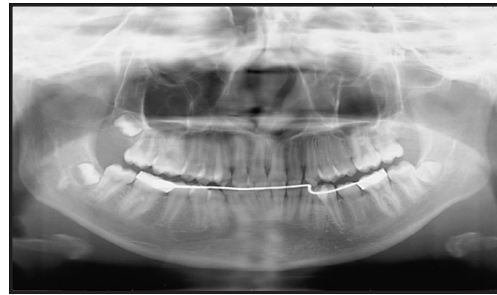

Fig. 8 Panoramic radiograph

the supernumerary tooth. In patient 1, the tooth with morphological abnormalities was differentiated as a fused tooth comprising a lateral incisor and a supernumerary tooth. In patient 2, since no significant differences in the tooth crown width were noted among the anterior teeth, differentiation of a supernumerary tooth was impossible.

A number of theories have been proposed as regards the causes of the occurrence of supernumerary teeth, including atavism theory¹⁾, mechanical tooth germ separation theory²⁾, tissue induction theory⁷⁾, and dental

laminar morphological disturbance theory⁴⁾. However, none of these theories alone offers a sufficient explanation for this phenomenon.

Fujita⁵⁾ reported that local developmental disorders in the jaw area, which are frequently observed in maxillary dentition, induced division or hyperplasia of tooth germs, suggesting this as a cause of supernumerary teeth. To the author's knowledge, no other cases of both mandibular supernumerary anterior teeth and alveolar cleft have been reported to date.

According to Fujita⁵⁾, hyperplasia of tooth germs may occur in areas with wide intervals

between tooth primordiums at the end of the dental lamina; therefore, it does not easily occur in the mandibular anterior tooth area, where there is a high inter-tooth primordium density, and the occurrence of mandibular supernumerary anterior teeth here is considered rare.

Conclusion

In this paper, we report two rare cases of supernumerary teeth in the mandibular incisor area and discuss their etiology. Differentiation of normal teeth and supernumerary teeth was found to be problematic.

References

- 1) Bolk L (1914) Supernumerary teeth in molar region in man. *Dental Cosmos* 56:154–167.
- 2) Bush W (1886) Die Uberzahl und Unterzahl in Den Zahnen des Menschlichen Gebisses mit Einschluss der sogenannten Dentition teria, *Dtsch. Monatschr Zhk Bd* 4:447–464.
- 3) Davis PJ (1987) Hypodontia and hyperdontia of permanent teeth in Hong Kong school children. *Community Dent Oral Epidemiol* 15: 218–220.
- 4) Fujita K (1958) Evolution of mammalian teeth with special reference to the human dentition. *Kaibogaku Zasshi* 33:89–94.
- 5) Fujita K (1958) Unusual number of teeth. *Kokubyo Gakkai Zasshi* 25:97–106. (in Japanese)
- 6) Fukuta Y (1999) Two atypical supernumerary teeth in the lower anterior region. *Jpn J Oral Diagn* 12:472–474.
- 7) Hattori S (1959) Study on supernumerary tooth, deficiency of tooth, fused tooth, dwarfish tooth, etc. From evolutionary point of view. *Shikwa Gakuho* 59:1124–1137. (in Japanese)
- 8) Ruprecht A, Batniji S, el-Neweihi E (1984) Incident of supernumerary teeth. *Ann Dent* 43:18–21.
- 9) Stafne EC (1932) Supernumerary teeth. *Dental Cosmos* 74:653–659.
- 10) Tada I (1980) A case report of supernumerary teeth in lower anterior region. *Shika Igaku* 43:277–284.
- 11) Totsuka M (1984) A case of supernumerary tooth in lower anterior region. *Dent J Iwate Med Univ* 9:118–127.

Reprint requests to:

Dr. Taishi Yokose
Department of Orthodontics,
Tokyo Dental College,
1-2-2 Masago, Mihama-ku,
Chiba 261-8502, Japan
E-mail: yokose@tdc.ac.jp