

"Special Contribution"

RECURRENT COLORECTAL METASTATIC LESION, IDENTIFIED BY F-18 FDG COINCIDENCE PET SCAN.

Philip Cohen, MD

Lions Gate Hospital, Vancouver, BC, Canada

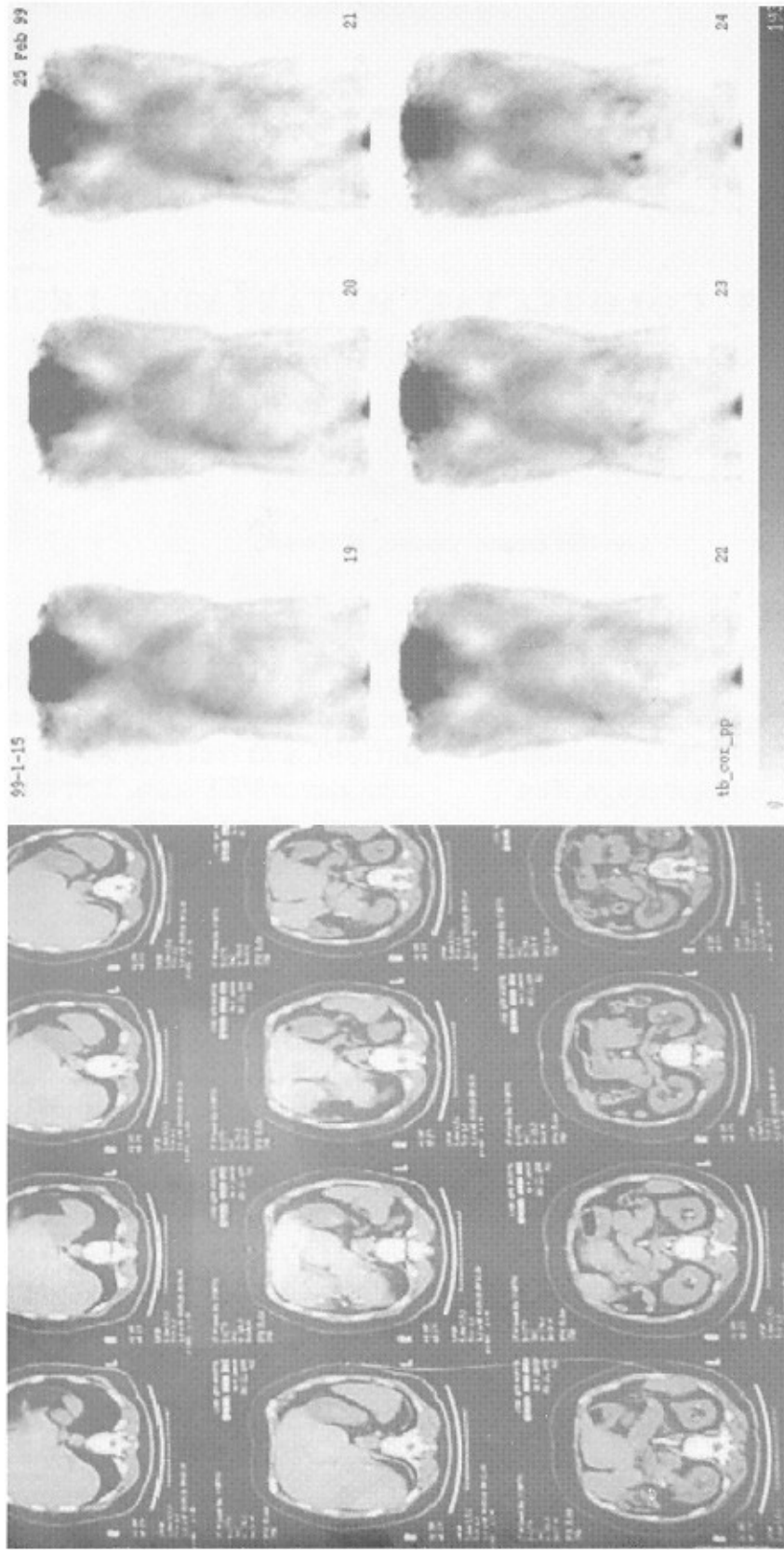
A 65 year old woman presented to the Department of Nuclear Medicine at Lions Gate Hospital with rising tumor markers (Serum CEA) for coincidence PET scan. She had been diagnosed 1 year previously with colorectal carcinoma with solitary metastasis to the liver, and had undergone colon resection and liver resection.

Her CT Scan (fig. 1) showed evidence of previous resection of the right lobe of the liver, but was otherwise negative. A coincidence PET scan (fig. 2) was carried out after intravenous injection of 5 mCi of F-18 FDG, and showed a faint solitary focus in the right lobe of the liver near the resection line. She was consequently referred for surgery, and underwent surgical exploration of the right lobe. A suspicious area of liver was removed, but at pathology was shown only to contain

necrotic liver tissue and no tumor. Following surgery, the patient's CEA tumor marker continued to rise, and the patient was referred for a second coincidence PET scan. The second study showed more definite tumor focus (figure 3) at the resection line in the liver, with other foci now visualized in the left lobe of the liver.

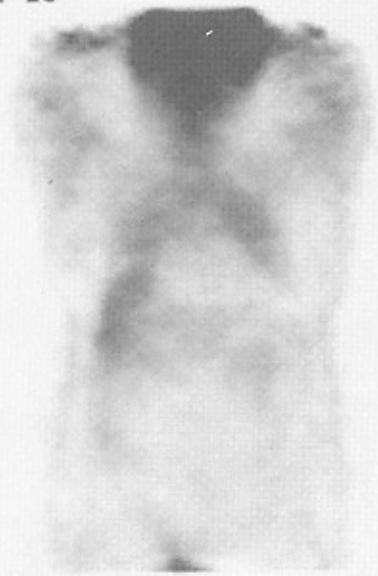Findings suggest that F-18 FDG was precise at identifying the tumor site of recurrence, at a time when other imaging modality (CT scan) was negative, and the only indicator of tumor recurrence was rising CEA marker. It also points out that PET is exquisitely sensitive, even using a coincidence detection system (ADAC Vertex Camera) rather than a dedicated PET camera, even when the recurrent lesion is difficult to see during exploratory surgery.

65 YR FEMALE WITH RECTAL CA, RISING CEA, PREVIOUS HEPATIC RESECTION FOR LIVER METS

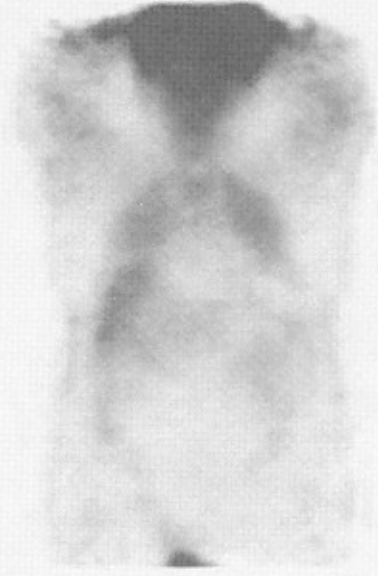

Recurrent Colorectal metastatic lesion

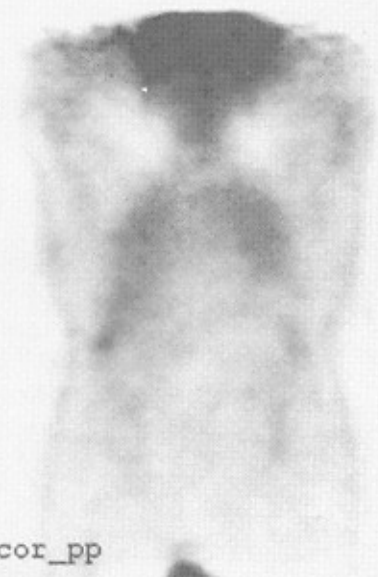99-1-15



19

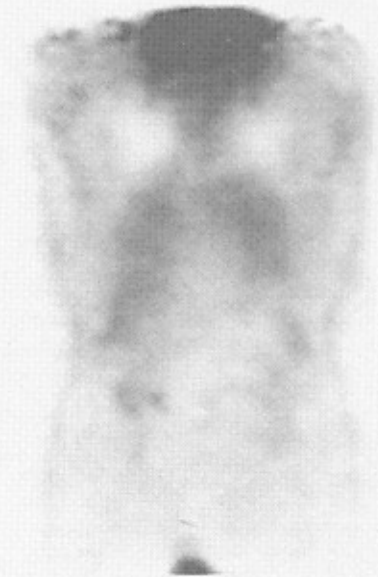

20

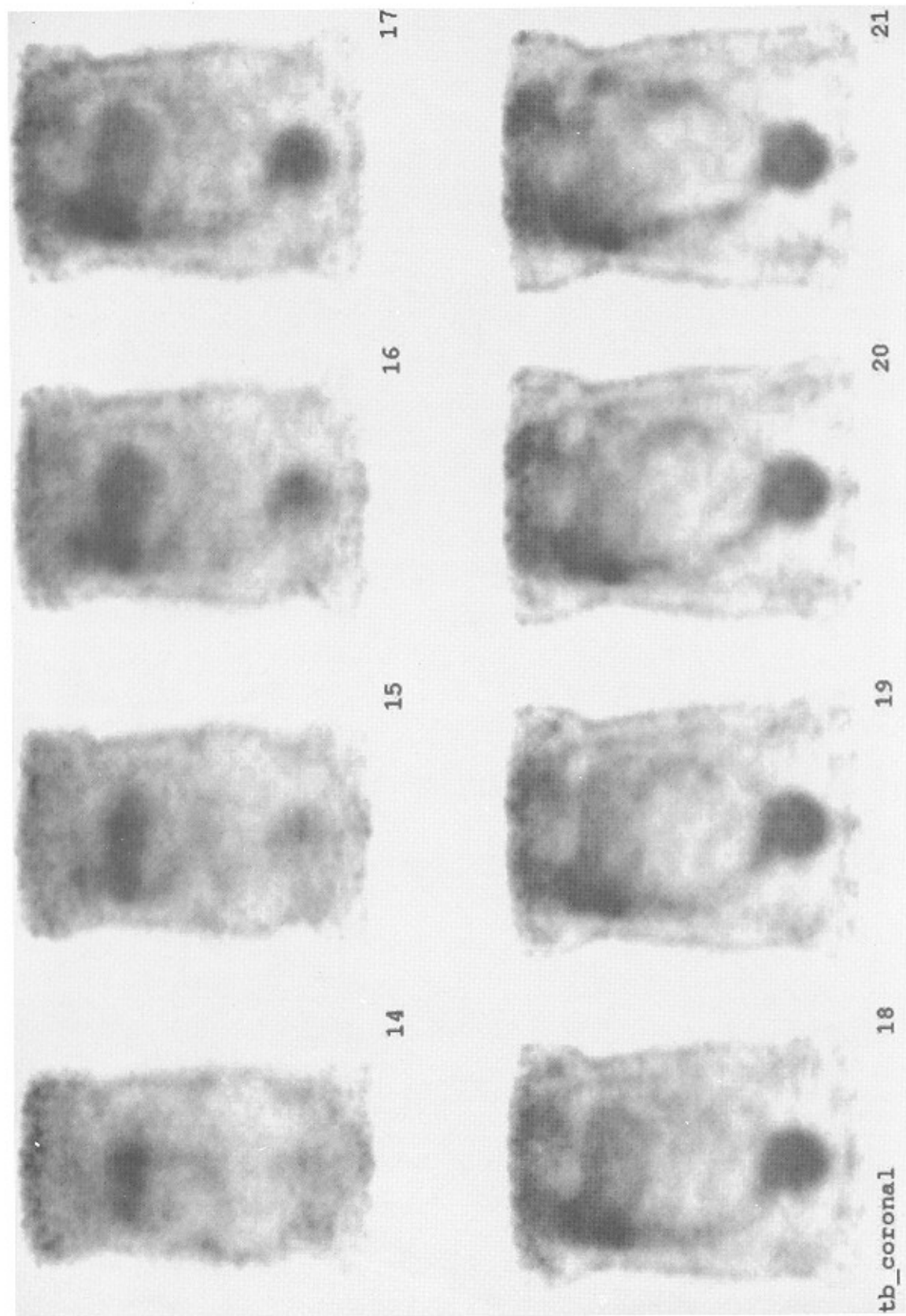


tb_cor_pp

22



23



References

- 1 - Weber W, Young DO, Abdet-Dayem H, Sfakianakis G, Wier G, Shreve P, Swaney C, Gates M, Girardeau MO, Rijk P, Parker A, Valk
- 2 - Delbeke D, Sandler MP, Al-Sugair A, Martin WH, Coleman RE, Comparison of FDG in patients with focal pulmonary lesions, Abstract J of Nuclear Med, Vol 39., No 5 May 1998: P.108
- 3 - Abdel-Dayem HM, Bonfils E, Teitgin P, El-Zeftawy HA, Luo J, Naddaf S, Kumar M, Atay S, Degirmenci B. Dual head coincidence imaging (DHCL) of F-18 FDG in primary lung nodules (PLN), Abstract J of Nuclear Med, Vol 39., No 5, May 1998: P.109
- 4 - Murthy K, Thompson CJ, Bergman AM, Robar JL, Lisbona R, Loutfi A, Gagnon JH, 18F-FDG PEM: preliminary clinical evaluation of a metabolic imaging system dedicated to the early detection of breast carcinoma, Abstract J of Nuclear Med, Vol 39., No 5, May 1998: P.146
- 5 - Shreve P, Steventon RS, Gross M, Diagnosis of spine metastasis by FDG imaging using a gamma camera in coincidence mode, Clinical Nuclear Medicine Vol 23, No 12. PP. 799-802.