

# A Case of Drug-Induced Hypersensitivity Syndrome-Like Symptoms Following HHV-6 Encephalopathy

Satoshi Saida<sup>1</sup>, Akira Yoshida<sup>1</sup>, Rieko Tanaka<sup>1</sup>, Junya Abe<sup>1</sup>, Keigo Hamahata<sup>1</sup>, Mitsuyoshi Okumura<sup>1</sup> and Toru Momoi<sup>1</sup>

## ABSTRACT

**Background:** Drug-induced hypersensitivity syndrome (DIHS) is a rare but severe disorder due to a systemic hypersensitivity reaction. We report on a case with DIHS-like symptoms following human herpes virus 6 (HHV-6) infection complicated with encephalopathy.

**Case Summary:** An 11-month-old girl suffered from a human herpes virus 6 (HHV-6) infection (exanthema subitum) complicated with encephalopathy. We treated the patient with continuous infusion of thiopental, assisted mechanical ventilation, methylprednisolone pulse therapy, and  $\gamma$ -globulin infusion therapy starting on the fifth day of the illness and started phenobarbital administration on the eleventh day. The patient developed a fever, systemic erythematous exanthema, lymphadenopathy, and eosinophilia two weeks after the start of phenobarbital administration. Steroid therapy, methylprednisolone (4 mg/kg/day) followed by oral prednisolone (1 mg/kg/day), was started on the 28th day and was tapered off on the 72nd day after admission. Serum anti-HHV-6 IgG antibody elevation and the presence of HHV-6 DNA in the peripheral blood detected by polymerase chain reaction (PCR) analysis suggested reactivation of HHV-6 after the primary infection of HHV-6. Lymphocyte transformation test for phenobarbital was positive three weeks after the DIHS crisis.

**Discussion:** HHV-6 reactivation is a unique feature in DIHS. In general one develops DIHS accompanied by reactivation of HHV-6 which has been residing in the body since the initial infection (exanthema subitum) in early childhood. This is the first report of a patient with DIHS-like symptoms which developed immediately following the primary infection of HHV-6.

## KEY WORDS

drug-induced hypersensitivity syndrome, drug-induced lymphocyte transformation test, HHV-6 encephalopathy, hypersensitivity syndrome, phenobarbital

## INTRODUCTION

Drug-induced hypersensitivity syndrome (DIHS) is one of the severe drug eruptions combined with multi organ disorders.<sup>1,2</sup> This syndrome has several unique features; delayed onset, worsening of clinical symptoms even after withdrawal of the causative drugs and cross-reactivity to multiple drugs with different structures. A close relationship between reactivation of herpes viruses including human herpes virus 6

(HHV-6) and the development of DIHS has been suggested.<sup>1,3,4</sup>

We present an 11-month-old girl who suffered from DIHS following a primary HHV-6 infection complicated with encephalopathy. DIHS developed 27 days after the onset of exanthema subitum and 14 days after the start of phenobarbital treatment.

## CLINICAL SUMMARY

The patient was an 11-month-old girl who visited our

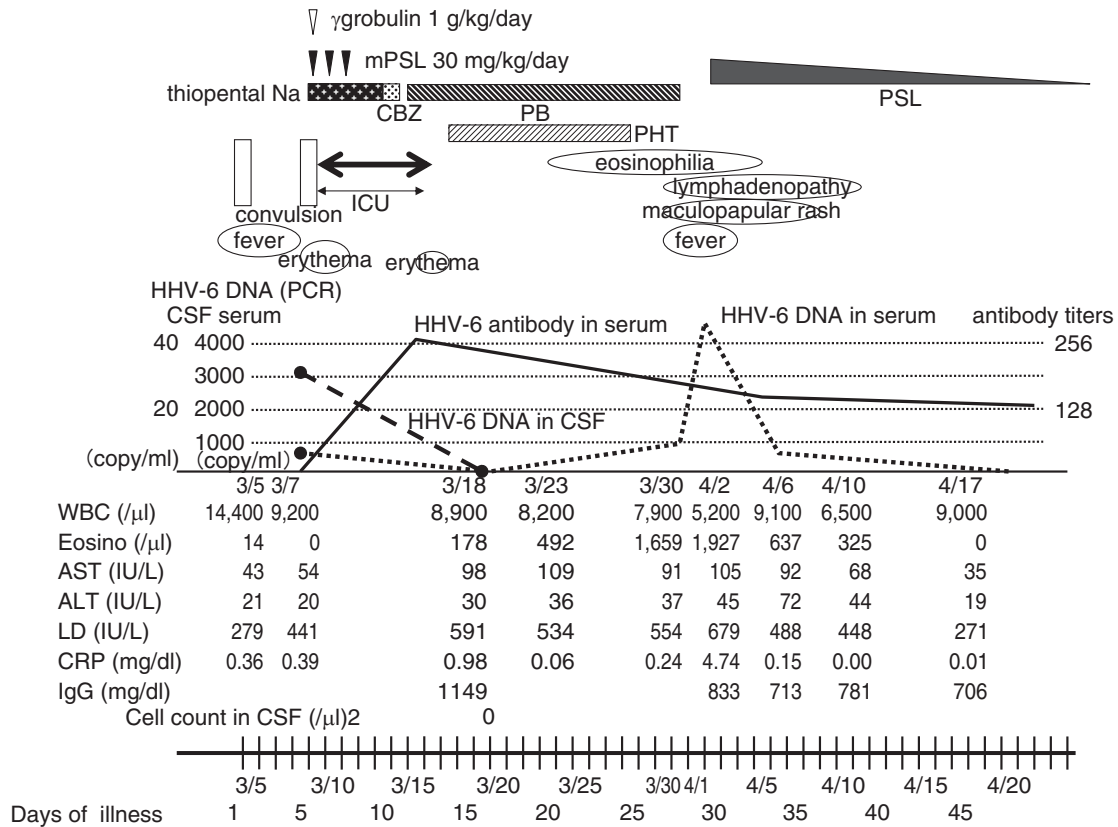
<sup>1</sup>Department of Pediatrics, Japanese Red Cross Wakayama Medical Center, Wakayama, Japan.

Correspondence: Akira Yoshida, MD, Pediatrics, Japanese Red Cross Wakayama Medical Center, 4-20 Komatsubara-dori, Wakayama City, Wakayama 640-8558, Japan.

Email: jxmc423@yahoo.co.jp

Received 1 February 2009. Accepted for publication 25 June 2009.

©2010 Japanese Society of Allergology



**Fig. 1** Clinical course. Solid line indicates HHV-6 antibody in serum, broken line indicates HHV-6 DNA in serum and bold-broken line indicates HHV-6 DNA in CSF. Abbreviations: mPSL, methylprednisolone; PSL, prednisolone; HHV-6, human herpes virus 6; CSF, cerebrospinal fluid; ICU, intensive care unit; CBZ, carbamazepine; PB, phenobarbital; PCR, polymerase chain reaction assay; AST, aspartate aminotransferase; ALT, alanine aminotransferase; LD, lactate dehydrogenase; CRP, C-reactive protein; WBC, white blood cell.

hospital due to right tonic hemiconvulsions and upward deviation of the eyes without any preceding symptoms. The convulsions were controlled by the intravenous administration of diazepam one hour after onset. On admission her body temperature was 39.1°C, heart rate was 148/minute and respiration rate was 30/minute. She was ill tempered but her consciousness was clear. Physical findings were as follows: skin was free of eruption, throat was injected, breath sounds were normal, heart sounds were clear without murmurs, abdomen was soft and flat and both right upper and lower extremities were paralysed. Laboratory data on admission were as follows (Fig. 1); WBC 14,400/ $\mu$ l (eosinophil 0.1%), AST 43 IU/l, LD 279 IU/l, CRP 0.36 mg/dl, BS 145 mg/dl. Head CT revealed no remarkable changes. Rapid influenza antigen test was negative.

On the fourth day of the illness she became afebrile with normal laboratory data and a millimetric erythematous rash appeared over her whole body which persisted for 3 days. We diagnosed her as suffering from exanthema subitum complicated with febrile seizure. On the fifth day she had a generalized

cluster of right hemiconvulsions. Lumbar puncture showed no abnormal findings but diffusion-weighted magnetic resonance imaging (DW-MRI) showed abnormal hyperintensity in the subcortical white matter of the frontal lobes.

We treated the patient with continuous infusion of thiopental and assisted mechanical ventilation. Thereafter the seizures were not seen. Intravenous methylprednisolone pulse therapy (30 mg/kg/day for 3 days),  $\gamma$ -globulin and acyclovir therapy were introduced from the same day. On the tenth day the thiopental infusion therapy was discontinued and oral carbamazepine was started instead. On the eleventh day a maculopapular erythematous rash appeared on face, extremities and trunk. So we changed carbamazepine to phenobarbital suspecting a hypersensitivity reaction to carbamazepine. On the 14th day intravenous phenytoin injection was added. Afterwards the erythema subsided with no seizure episodes. We started nasogastric tube feeding and rehabilitation on the 17th day. Phenytoin injection therapy was discontinued on the 25th day. At that time she could neither recognize her parents, nor sit by herself. Right hemi-

paresis persisted.

On the 27th day the patient had a fever with erythema over the whole body with cervical lymphadenopathy. The next day we stopped phenobarbital therapy suspecting drug allergy. However, the high fever and erythema continued and facial edema developed. On the 30th day eosinophil count elevated to 1,927/ $\mu$ l. Aspartate aminotransferase (AST) was 105 IU/l and alanine aminotransferase (ALT) was 45 IU/l. We suspected DIHS and methylprednisolone was administered intravenously. On the 31st day she became afebrile and skin eruptions disappeared. On the 34th day intravenous methylprednisolone was changed to oral prednisolone. On the 35th day she smiled and could eat orally. Then the erythematous rash had turned to pigmentation and desquamation.

Gradually she had improved to recognize and look around at her parents by the 50th day but right hemiparesis remained. The EEG showed spikes in the left temporal lobe and MRI showed slight brain atrophy on the day of discharge. She was discharged on the 61st day. Subsequently the steroid was tapered off on the 72nd day. Afterwards no symptoms reappeared. Her development was as follows: she stood by herself at 18 months, walked by herself at 19 months and recognized words at 24 months.

#### **VIROLOGICAL AND SEROLOGICAL STUDIES**

HHV-6 DNA was detected in serum (635 copy/ml) and CSF (31.5 copy/ml) on the fifth day of the illness when she had cluster convulsions during the eruptive stage of exanthema subitum but was not detected on the 16th day. It was detected again in the serum on the 28th day (805 copy/ml) when she had high fever and generalized erythema. On the 30th day, serum HHV-6 DNA was 4360 copy/ml and DIHS due to HHV-6 reactivation was suspected. The anti-HHV-6 IgG antibody was negative on the day of admission, and it was x256 on the 11th day and x128 on the 34th day. The anti-HHV-6 IgM antibody was not measured in our patients. The IgG antibody titer against Epstein-Barr virus was 6.7 (<1.0) and the IgM antibody was negative on the 30th day.

#### **DRUG-INDUCED LYMPHOCYTE TRANSFORMATION TEST (LTT)**

The results of drug-induced lymphocyte transformation test on the 45th day for phenobarbital, phenytoin and carbamazepin were 917%, 239% and 105%, respectively.

#### **DISCUSSION**

This is the first report of a patient with DIHS-like symptoms which developed shortly after the primary infection of HHV-6. This case is consistent with the diagnostic criteria of DIHS<sup>1</sup> such as maculopapular rash, fever, eosinophilia, lymphadenopathy and HHV-6 reactivation, but inconsistent with the criteria in

terms of prolonged clinical symptoms after discontinuation of the causative drug and liver dysfunction (ALT >100 IU/l). Earlier introduction of the steroid might have contributed to the mild liver dysfunction and lack of prolonged clinical symptoms in our patient.

Early recognition and immediate discontinuation of the causative drug is the most important step in the treatment of this syndrome. Supportive therapy alone without the use of systemic steroids may lead to a cure within a few weeks in mild cases. But this syndrome may cause infliction of other organ system such as myocarditis,<sup>5</sup> rhabdomyolysis,<sup>6</sup> encephalitis,<sup>7</sup> pneumonitis and hepatitis.<sup>8</sup> Although there have been no randomized, controlled trials to prove the efficacy of steroids, many reports showed the rapid resolution of the symptoms and fair prognosis with steroid therapy.<sup>1,2</sup> In our case steroid therapy started four days after the development of high fever, erythema and slight elevation of ALT which were indicative of DIHS.

The causative drugs of DIHS are anti-convulsants (carbamazepine, phenytoin, phenobarbital and zonisamide), antimicrobials, allopurinol and others.<sup>1</sup> Considering the result of LTT and the clinical course, the causative drug in our patient was phenobarbital.

The number of reports of DIHS in children are few. Patients under 2 years old are especially rare since the long term use of anti-convulsants are not common in infants under 2-years of age.<sup>2</sup> Fever and rash in children may be regarded as symptoms of more common diseases such as bacterial and viral infection. Prompt recognition and differential diagnosis is essential for the early treatment in these patients to prevent serious complications.

The pathomechanisms in DIHS remains largely unknown. HHV-6 reactivation is a unique feature in DIHS and is not observed in other drug eruptions. Recent studies have demonstrated that other herpesviruses such as Epstein-Barr virus (EBV),<sup>9</sup> HHV-7,<sup>3</sup> or cytomegalovirus (CMV)<sup>10</sup> are reactivated in the course of the disease as well. These herpesviruses can be reactivated in DIHS in a sequential order.<sup>11</sup> Sequential reactivation of various herpesviruses could result in exacerbations and remissions of clinical symptoms. The cascade of the reactivation events is usually initiated by EBV or HHV-6 and followed by HHV-7 and CMV.<sup>12</sup> HHV-6 reactivation can be detected around 2 to 3 weeks after onset being coincident with overshooting increases in serum Ig levels.

Whether the reactivation of herpesviruses has a causal role of DIHS or DIHS is initiated by an immune reaction to the incriminated drugs which seem to have a substantial ability to stimulate T cells is controversial. Recently the role of anti-viral T cells has been noticed.<sup>12</sup> It is postulated that certain drugs which have intrinsic properties to potentially induce immunosuppression lead to reactivation of herpes vi-

ruses, and then activation of anti-viral T cells occurs followed by cross-reaction with drug antigens. As a consequence DIHS would ensue.

There have been few reports regarding the possible etiological association of DIHS with other microorganisms including mycoplasma,<sup>13</sup> parvovirus B19,<sup>14</sup> and paramyxovirus.<sup>15</sup>

HHV-6 is the causative agent of the popular childhood infectious disease, exanthema subitum. It has been recognized that primary infection of HHV-6 can cause CNS disorders including febrile seizures and encephalitis/encephalopathy.<sup>16</sup> HHV-6 reactivation is a unique feature in DIHS. In general one develops DIHS accompanied by reactivation of HHV-6 which has been residing in the body since the initial infection as exanthema subitum in early childhood. Our patient is unique in that DIHS-like symptoms developed immediately following the primary infection of HHV-6.

The diagnosis of primary HHV-6 infection was made based on a typical clinical course compatible with exanthema subitum and the detection of HHV-6 DNA in the serum and CSF during the early stage of infection (the fifth day of illness). Negative serum anti-HHV-6 IgG antibody on the first day and elevated antibody on the 11th day of illness also support the diagnosis of primary HHV-6 infection in our patient.

DIHS associated with primary infections may suggest a novel mechanism which is different from DIHS developing long after the primary infection. Recent investigations have disclosed various complicated aspects of DIHS. Various cytokines, for example IL-6, TNF- $\alpha$ , were generated in cases of certain infections. In patients with DIHS, elevations of TNF- $\alpha$  and IL-6 were reported.<sup>17</sup> These cytokines may modify the immune mechanisms inducing interplay among herpes viruses, antiviral immune responses and drug-specific immune responses. The elucidation of the pathogenesis of DIHS requires further studies.

## ACKNOWLEDGEMENTS

We would like to thank Dr Tetushi Yoshikawa of the Department of Pediatrics, Fujita Health University School of Medicine, for measuring HHV-6 DNA and anti-HHV-6 IgG antibody.

## REFERENCES

1. Shiohara T, Inaoka M, Kano Y. Drug-induced hypersensitivity syndrome (DIHS): a reaction induced by a complex

interplay among herpesviruses and antiviral and antidrug immune responses. *Allergol Int* 2006;**55**:1-8.

2. Carroll MC, Yueng-Yue KA, Esterly NB, Drolet BA. Drug-induced hypersensitivity syndrome in pediatric patients. *Pediatrics* 2001;**108**:485-92.
3. Suzuki Y, Inagi R, Aono T, Yamanishi K, Shiohara T. Human herpesvirus 6 infection as a risk factor for the development of severe drug-induced hypersensitivity syndrome. *Arch Dermatol* 1998;**134**:1108-12.
4. Tohyama M, Yahata Y, Yasukawa M *et al*. Severe hypersensitivity syndrome due to sulfasalazine associated with reactivation of human herpesvirus 6. *Arch Dermatol* 1998;**134**:1113-7.
5. Taliere CP, Olney BA, Lie JT. Myocarditis related to drug hypersensitivity. *Mayo Clin Proc* 1985;**60**:463-8.
6. Engel JN, Mellul VG, Goodman DB. Phenytoin hypersensitivity: a case of severe acute rhabdomyolysis. *Am J Med* 1986;**81**:928-30.
7. Fujino Y, Nakajima M, Inoue H, Kusuhara T, Yamada T. Human herpesvirus 6 encephalitis associated with hypersensitivity syndrome. *Ann Neurol* 2002;**51**:771-4.
8. Knowles SR, Shapiro LE, Shear NH. Anticonvulsant hypersensitivity syndrome: incidence, prevention and management. *Drug Saf* 1999;**21**:489-501.
9. Descamps V, Mahe E, Houhou N *et al*. Drug-induced hypersensitivity syndrome associated with Epstein-Barr virus infection. *Br J Dermatol* 2003;**148**:1032-4.
10. Aihara M, Sugita Y, Takahashi S *et al*. Anticonvulsant hypersensitivity syndrome associated with reactivation of cytomegalovirus. *Br J Dermatol* 2001;**144**:1231-4.
11. Kano Y, Hiraharas K, Sakuma K, Suzuki Y. Several herpesviruses can reactivate in a severe drug-induced multiorgan reaction in the same sequential order as in graft-versus-host disease. *Br J Dermatol* 2006;**155**:301-6.
12. Shiohara T, Kano Y. A complex interaction between drug allergy and viral infection. *Clin Rev Allergy Immunol* 2007;**33**:124-33.
13. Kosseian-Bal I, Bocquet H, Beneton N *et al*. [Hypersensitivity syndrome during Mycoplasma pneumoniae infection]. *Ann Dermatol Venereol* 1998;**125**:328-30 (in French).
14. Regnier S, Descamps V, Boui M *et al*. [Parvovirus B19 infection mimicking drug-induced hypersensitivity syndrome]. *Ann Dermatol Venereol* 2000;**127**:505-6 (in French).
15. Naniwa T, Maeda S, Sawada H *et al*. Drug-induced hypersensitivity syndrome associated with a marked increase in anti-paramyxovirus antibody titers in a scleroderma patient. *Allergol Int* 2007;**56**:303-8.
16. Yoshikawa T, Asano Y. Central nervous system complications in human herpesvirus-6 infection. *Brain Dev* 2000;**22**:307-14.
17. Yoshikawa T, Fujita A, Yagami A *et al*. Human herpesvirus 6 reactivation and inflammatory cytokine production in patients with drug-induced hypersensitivity syndrome. *J Clin Virol* 2006;**37**:S92-6.