

# Drug-induced Hypersensitivity Syndrome(DIHS): A Reaction Induced by a Complex Interplay among Herpesviruses and Antiviral and Antidrug Immune Responses

Tetsuo Shiohara<sup>1</sup>, Miyuki Inaoka<sup>1</sup> and Yoko Kano<sup>1</sup>

## ABSTRACT

A relationship between viral infections and the simultaneous or subsequent development of allergic inflammation has often been observed in various clinical situations. Recent studies suggest an intimate relationship between reactivations of herpesviruses including human herpesvirus 6 (HHV-6) and the development of a severe systemic hypersensitivity reaction referred to as drug-induced hypersensitivity syndrome (DIHS). This syndrome has several important clinical features that cannot be solely explained by drug antigen-driven oligoclonal expansion of T cells: they include paradoxical worsening of clinical symptoms after discontinuation of the causative drug. In view of the similarity to GVHD or immune reconstitution syndrome (IRS) in clinical manifestations and emergence of viral infections, the clinical symptoms observed during the course of DIHS and GVHD are likely to be mediated by antiviral T cells that can cross-react with the drug and alloantigens, respectively. In considering common intrinsic properties of the causative drugs to potentially induce immunosuppression, reconstitution of a valid immune response to these viruses, which is typically observed in IRS, may be the most crucial process that takes place after withdrawal of the causative drug in patients with DIHS. Thus, this syndrome should be regarded as a reaction induced by a complex interplay among several herpesviruses (EB virus, HHV-6, HHV-7, and cytomegalovirus), antiviral immune responses, and drug-specific immune responses. This review includes discussion of the pathomechanism, the clinical symptoms, laboratory findings, pathological findings and therapy.

## KEY WORDS

drug-induced hypersensitivity syndrome, GVHD, herpesviruses, HHV-6, NK cells

## INTRODUCTION

A large body of evidence clearly shows that infections do play a role in the development of various allergic diseases, although the exact nature of their contribution is largely unknown.<sup>1-3</sup> Do they directly induce immune cell cross-reactivity with drug-modified host antigens? Alternatively, do they represent merely the trigger that sets off an otherwise subliminal allergy through the action of proinflammatory cytokines? Given their potential to activate innate and acquired immune responses, investigators have become very

interested in the relationship between viral infections and allergic inflammation. For instance, a relationship between viral infection and the simultaneous or subsequent development of drug eruptions has been often observed in the clinical situation; and ampicillin rash during infectious mononucleosis and an increased risk for developing drug eruptions in AIDS are perhaps the best known examples of the relationship.<sup>4,5</sup> However, although a number of viruses have been reportedly associated with drug eruptions, no convincing evidence has linked a single viral agent with the subsequent risk of developing one disease

<sup>1</sup>Department of Dermatology, Kyorin University School of Medicine, Tokyo, Japan.

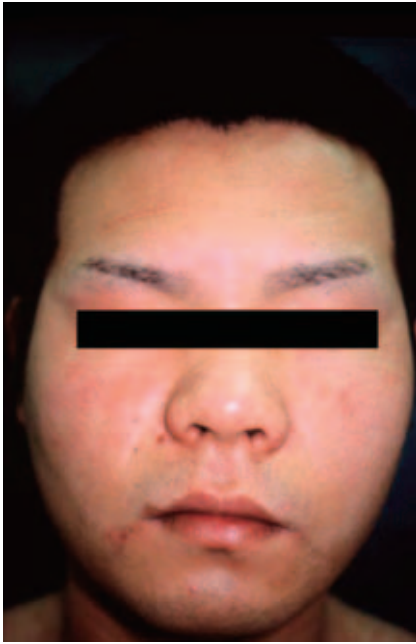
Correspondence: Tetsuo Shiohara, M.D., Department of Dermatology, Kyorin University School of Medicine, 6-20-2 Shinkawa,

Mitaka, Tokyo 181-8611, Japan.

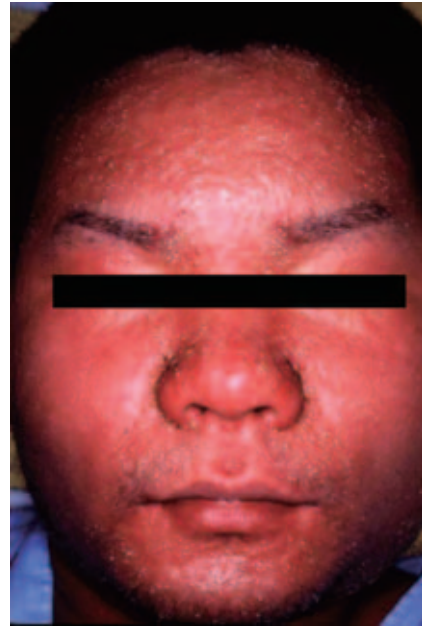
Email: tpshio@kyorin-u.ac.jp

Received 2 November 2005.

©2006 Japanese Society of Allergology



**Fig. 1A** Face of patient on his initial presentation demonstrates slight erythema.



**Fig. 1B** Patient's face on admission three days after his initial presentation demonstrates edema, erythema studded with small pustules, and lymphadenopathy despite discontinuation of the causative drug.

**Table 1** Drugs frequently causing DIHS/DRESS

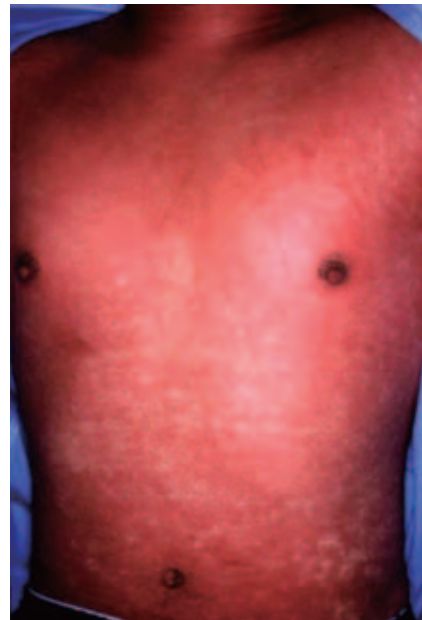
• Carbamazepine	• Dapsone
• Phenytoin	• Salazosulfapyridine
• Phenobarbital	• Allopurinol
• Mexiletine	• Minocycline

outcome.

Nevertheless, recent studies including ours<sup>6,7</sup> suggest an intimate relationship between human herpesvirus 6 (HHV-6) and the development of a severe systemic hypersensitivity reaction referred to as drug-induced hypersensitivity syndrome (DIHS) or drug reaction with eosinophilia and systemic symptoms (DRESS).<sup>8</sup> In this review, we focus on the clinical symptoms of DIHS/DRESS and the possible etiologic role of herpes viruses including HHV-6 in the development of this syndrome.

### CLINICAL SYMPTOMS

DIHS/DRESS usually occurs 3 weeks to 3 months after starting therapy with a limited number of drugs: they include carbamazepine, phenytoin, phenobarbital, dapsone, mexiletine, salazosulfapyridine, allopurinol, and minocycline (Table 1).<sup>9</sup> Cross-reactivity among these drugs has been frequently reported, because phenytoin, phenobarbital, and carbamazepine are metabolized to hydroxylated aromatic compound and arene oxides are suggested intermediates in the reaction.<sup>10</sup> DIHS/DRESS has no age or sex predilection. The delayed onset in relation to introduction of



**Fig. 2** Patient's chest and abdomen with confluent purpuric erythematous rash on admission, three days after discontinuation of the causative drug.

the causative drug is one of the important features of DIHS/DRESS that can be distinguished from other types of drug eruptions.

This syndrome commonly begins with a fever

**Table 2** Diagnostic criteria for DIHS/DRESS

1. Maculopapular rash developing > 3 weeks after starting therapy with a limited number of drugs
2. Lymphadenopathy
3. Fever (> 38°C)
4. Leukocytosis (> 10 × 10<sup>9</sup>/L)
  - a. Atypical lymphocytosis
  - b. Eosinophilia
5. Hepatitis (ALT > 100 U/L)
6. HHV-6 reactivation

The diagnosis is confirmed by the presence of five of the six criteria above

shortly followed by a maculopapular rash, which is usually pruritic, and variable degrees of lymphadenopathy. The temperature ranges from 38°C and 40°C with spikes that usually generate a concern of an underlying infection. The spiking fever often persists even for weeks despite discontinuation of the offending drugs. Initially, the upper trunk, face, upper extremities are affected and followed by involvement of lower extremities. Periorbital, facial or neck edema with pinhead-sized pustules is one of the characteristic features of DIHS/DRESS at the early stage (Figs. 1,2). The rash often generalizes into a severe exfoliative dermatitis or erythroderma. The severity of diseases at onset provides only a guide to prognosis and is not absolute. There is usually no mucocutaneous involvement, which helps distinguish DIHS/DRESS from other forms of severe drug eruptions, such as Stevens-Johnson syndrome (SJS) and toxic epidermal necrolysis (TEN).

Tender lymphadenopathy can be seen in most patients early in the illness, affecting predominantly cervical nodes or generalized. Bilateral swelling of salivary glands with severe xerostomia is frequently observed at first visit. These findings suggest that reactivation of mumps virus may occur before onset of this syndrome. Hepatomegaly accompanied by splenomegaly is a common finding. The onset of these symptoms is highly variable; usually patients develop two or three features of symptoms followed by a step-wise development of other symptoms (Table 2). In many severe cases, these symptoms continue to deteriorate or several flare-ups can be seen even for weeks after stopping the offending drug. Interestingly, the more severe reactions often occur 3 days after withdrawal of the causative drug (Fig. 1A vs 1B). Such variability in the presentation and course of clinical symptoms allows for a delay in diagnosis, which can lead to significant morbidity.

Involvement of other organs varies, depending on the drug: allopurinol-induced DIHS/DRESS has more frequent renal involvement,<sup>11</sup> whereas there appears to be a higher risk of liver involvement in phenytoin or dapsone-induced disease.<sup>12</sup> Other features of

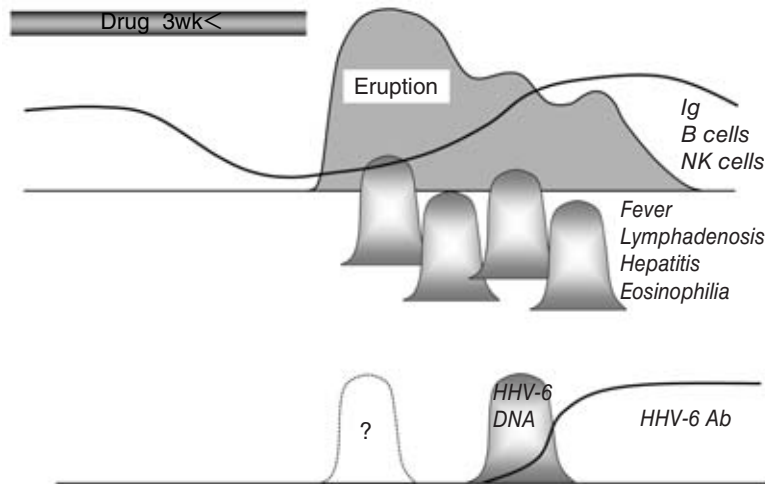
DIHS/DRESS include pneumonitis, coronary artery thrombosis, thyroiditis, rhabdomyolysis, encephalitis,<sup>13-15</sup> and diabetes mellitus.<sup>16</sup> Depending on the sites and severity of organ damages, various clinical symptoms would develop at various time points after onset. Nevertheless, in most cases their development is clinically silent and may be recognized only months or years later. In this regard, we have recently seen patients with DIHS/DRESS who developed limbic encephalitis and the syndrome of inappropriate secretion of antidiuretic hormone (SIADH) long after resolution of rashes. We have also seen patients with DIHS/DRESS who developed viral meningitis and herpes zoster 1–2 months after resolution of rashes. Thus, in the later phase, after an undefined period of critical illness of days to weeks, various organ failures will emerge. Despite withdrawal of the offending drug, resolution of symptoms in one organ is often followed by a step-wise development of such organ system failures (Fig. 3).

### LABORATORY FINDINGS

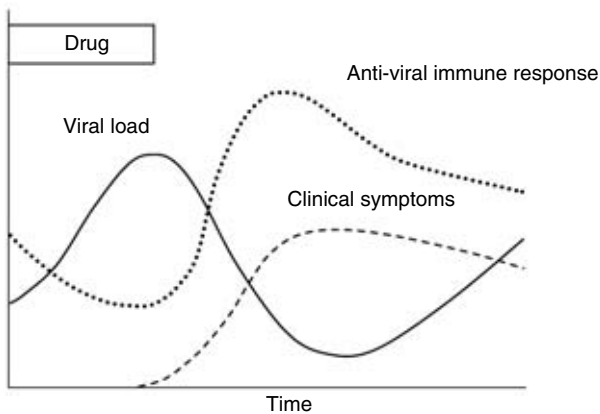
Leukocytosis with atypical lymphocytes and eosinophilia of various degrees is also a prominent feature of this syndrome. Nevertheless, leukopenia and lymphopenia have been also reported<sup>17</sup> and they occasionally precede leukocytosis. Our analyses showed that atypical lymphocytes predominantly consist of activated CD8<sup>+</sup> T cells.<sup>16</sup> The eosinophilia may often be delayed for 1 to 2 weeks and occur even after elevations in liver enzyme return to baseline. The true frequency of eosinophilia may actually be lower (~60%) than previously reported.

Liver abnormalities occur in up to 70% of patients and are characterized by a marked increase in serum alanine aminotransferase value. Severe hepatitis portends a prolonged course characterized by multiple exacerbations and remissions of both rash and liver disease.<sup>18,19</sup> The hepatitis is usually anicteric; but if it is icteric, it tends to have a poorer prognosis.<sup>20</sup> Although the bilirubin may be normal at presentation, hyperbilirubinemia can develop even after the causative drug is discontinued.<sup>12</sup> Elevations in liver enzymes usually continue to persist for several days after discontinuation of the offending drug. The mortality from DIHS/DRESS can be approximately 20% and has been correlated with the degree of hepatic or renal involvement.

As we previously reported,<sup>21</sup> a dramatic decrease in serum IgG, IgA, and IgM levels is typically observed at onset and the lowest IgG, IgA, or IgM levels are usually detected several days after withdrawal of the offending drug. Thus, serum IgG levels seem to continue to decrease for at least several days after drug therapy is discontinued. Immediately after the nadir in the decrease, the overshoot in IgG levels is transiently observed within 1 to 2 weeks and they finally return to normal on full recovery. Another



**Fig. 3** The clinical course of DIHS/DRESS. This syndrome usually begins with a fever shortly followed by a maculopapular rash > 3 weeks after starting therapy with a limited number of drugs. Patients usually develop two or three features of symptoms followed by a step-wise development of other symptoms. These symptoms continue to deteriorate or several flare-ups can be seen even for weeks after stopping the offending drug. Despite such a wide variety of clinical symptoms, HHV-6 reactivation can be detected at the certain timing, 3 weeks after withdrawal of the causative drug.



**Fig. 4** Schematic figure illustrating the relationship among viral loads, anti-viral immune responses and clinical symptoms before and after discontinuation of the causative drug in DIHS/DRESS. Although a strong immune response to viruses is presumably beneficial in reducing viral loads, it may also have harmful consequences. Harmful aspects of this immune response are reflected in the clinical symptoms of DIHS/DRESS.

unique feature of this syndrome is unexplained cross-reactivity to multiple drugs with structures different from the offending drug which are used after onset of the symptoms.

Although close clinical similarities between DIHS/

DRESS and infectious mononucleosis suggested a viral etiology, previous attempt to prove this etiology have failed; this is because previous studies ruled out the possibility that EB virus, cytomegalovirus (CMV), and hepatitis viruses could have produced the clinical syndrome or laboratory findings, solely based on serologic analyses. In this regard, we and Hashimoto's group reported an intimate relationship between HHV-6 reactivation and the development of this syndrome.<sup>6,7</sup> This would be the first example, in which the relationship between a single viral agent and the subsequent risk of developing one disease outcome has been convincingly demonstrated. It should be kept in mind, however, that HHV-6 reactivation as evidenced by the rise in HHV-6 IgG titers and HHV-6 DNA levels occurs generally 2–3 weeks after the onset of rashes in the vast majority of patients with DIHS/DRESS (Fig. 3). One may suppose, therefore, that HHV-6 reactivation is a consequence of cell activation occurring during the course of drug eruptions. Nevertheless, because HHV-6 reactivation can be detected in the vast majority of patients with DIHS/DRESS but not in other drug eruptions in Japan, this becomes a specific and sensitive diagnostic test to correct identification of all patients with this syndrome. This appears to be a gold standard test for DIHS/DRESS in Japan, which helps to confirm the identification of this syndrome. Recent studies including our own have also demonstrated that other herpesviruses, CMV, EBV, and HHV-7, can be se-

quentially reactivated during the course of this syndrome.<sup>6,26-28</sup> Based on these findings, we have proposed the concept that various herpes viruses may reactivate in sequential order during the course of DIHS/DRESS.<sup>29</sup>

To prove hypersensitivity to the causative drug, confirmatory testing such as patch tests and lymphocyte transformation tests (LTT) is often performed. The LTT is laboratory-based *in vitro* technology that is most widely available for the assessment of drug-reactive T cells.<sup>22</sup> Although these *in vivo* and *in vitro* tests are consistently positive in the vast majority of patients with DIHS/DRESS and negative in controls, contradictory results can be reported when performed during the acute stage<sup>23-25</sup>: false negative reactions are observed due to the early timing. Positive reactions can be consistently observed when tests are performed after remission, usually 4–6 weeks after onset. In particular, LTT become positive at least 4 weeks after onset and strong positive reactions can be observed even >1 year after discontinuation of the causative drug, a finding never observed in other severe drug eruptions, such as SJS. Considering the strong positivity long after resolution of the lesions, LTT appears more reliable and less cumbersome than patch testing, although the reported sensitivity of both tests are comparable.

### **PATHOLOGICAL FINDINGS**

The common pathological findings are superficial perivascular lymphocytic infiltrates and some extravasated erythrocytes or eosinophils. A dense, band-like lymphocytic infiltrates with epidermotropism, suggestive of lymphoma, can be seen in some patients. In some patients, there is liquefaction degeneration of the basal cell layer with a lichenoid infiltrate, compatible with severe drug eruptions. However, this lichenoid infiltrates with apoptotic keratinocytes, a finding frequently seen in SJS and TEN, are relatively atypical findings in DIHS/DRESS. Immunohistochemical stains demonstrate a predominance of T cells.

In our first report on HHV-6 in a patient with DIHS/DRESS, we detected high levels of HHV-6 genome and viral antigens on infiltrating cells in the skin lesions taken at the early stage,<sup>6</sup> which suggests an etiological role of this microorganism. However, the presence of HHV-6 DNA in the lesions cannot be taken as proof of causation of the lesions; and we could not exclude the possibility that the detection of HHV-6 DNA in the cellular infiltrates could merely reflect a propensity for viral recurrence to lead to infection of these cells.

### **PATHOMECHANISMS**

Although several theories have been proposed, the pathomechanisms of DIHS/DRESS remains largely unknown. So far, no satisfying explanation for diver-

sity of the clinical symptoms as described above has been offered. The results of the patch tests and LTT indicate that drug-specific T cells are the driving force behind this syndrome.<sup>6,21,30-32</sup> However, not easily reconciled with drug antigen-driven oligoclonal expansion of T cells are clinical features, such as its delayed onset, frequent deterioration or several flares-ups after withdrawal of the causative drugs, multiorgan involvement, and unexplained cross-reactivity to multiple drugs used after onset of rashes. An alternative theory is that toxic oxidative metabolites of these drugs generated under certain circumstances bind to tissue macromolecules thereby acting as haptens stimulating CD4<sup>+</sup> and CD8<sup>+</sup> T cells.<sup>10</sup>

We have recently suggested an important role of herpesvirus reactivations sequentially occurring before and during the course of this syndrome in the development of DIHS/DRESS<sup>29</sup>: reactivation of latent herpesviruses, such as EBV, may be initially induced far before onset of clinical symptoms and strong immune responses to the reactivations might have the dual effects of reducing viral loads and developing clinical symptoms. According to this theory, clinical symptoms are likely mediated by an expansion of virus-specific and nonspecific T cells in response to the reactivations of these viruses. Indeed, in EBV-induced infectious mononucleosis, an increase in systemic viral loads is not reflected in symptom severity; the severity is rather a reflection of massive expansion of T cells. In this regard, we for the first time reported a patient who experienced severe skin rash associated with sequential reactivations of various herpesviruses.<sup>29</sup> Until now, however, longitudinal analyses of herpesvirus reactivations during the course of the syndrome have been predominantly performed by serologic tests, but not by PCR-based detection of viral DNA, which is obscured by uncertainty about the rise in antibody titers to viruses in this setting: reactivations of herpesviruses at the early phase cannot be reflected in antibody titers at the early phase because a dramatic decrease in Ig production has been reported to occur at that time.<sup>21</sup> We therefore performed real-time PCR to detect and quantify viral DNA, using blood samples sequentially obtained from patients with DIHS/DRESS after onset of rashes.

Although the order of herpesviruses sequentially reactivated was not exactly the same in patients with DIHS/DRESS examined, our PCR analyses showed that various herpesviruses can sequentially reactivate during the course of this syndrome (Kano Y *et al.* Manuscript submitted). The cascade of virus reactivation initiated by HHV-6 or EBV extended, with some delay, to HHV-7 and eventually to CMV. Surprisingly, this cascade of sequential herpesvirus reactivations observed in DIHS/DRESS is quite similar to that observed in graft-versus-host disease (GVHD).<sup>33,36</sup> In view of the similarity between DIHS/DRESS and

GVHD with regard to the clinical manifestations, the highly variable waxing and waning nature of the clinical manifestations occurring in different organs despite discontinuation of the offending drug could be explained by sequential reactivations of these herpesviruses; nevertheless, sequential reactivations of these viruses were not always associated with evidence of overt clinical symptoms. Interestingly, recent studies have provided strong suggestive evidence for a role of viral infections in the emergence of alloreactive T cells and the development of GVHD.<sup>33-35</sup> In the setting of GVHD, it has been hypothesized that activation of donor-derived antiviral T cells by alloantigens or bystander activation of the antiviral T cells by massive cytokine production are responsible for the development of GVHD. In support of this hypothesis, herpesvirus genome can be detected at high frequency coincident with the clinical symptoms, suggesting that virus-driven clonal expansions of alloreactive T cells that may have originally generated to deal with herpesviruses are involved in initiating GVHD<sup>37</sup>; if so, the severity of clinical symptoms in DIHS/DRESS as well as GVHD would be determined by the magnitude of expansions of antiviral T cells. These similarities to GVHD, together with the ability of HHV-6 and HHV-7 to reactivate heterologous viruses,<sup>38,39</sup> led us to consider the possibility that these herpesviruses might be functionally linked *in vivo*, the reactivation of one leading to the reactivation of the other, thus explaining the ambiguity in the apportioning their role. These considerations raise the possibility that the clinical manifestations originally attributed to CMV or EBV can be ascribed to HHV-6 or HHV-7.

Thus, by analogy with the similarities to GVHD, the clinical symptoms observed during the course of DIHS/DRESS are likely to be mediated by antiviral T cells that can cross-react with the drugs but not solely by drug-driven oligoclonal expansions of drug-specific T cells. This scenario could provide answers to many questions arising on DIHS/DRESS: why frequent deterioration can be seen after withdrawal of the offending drug; why multiple organs are involved in a sequential order; and why unexpected cross-reactivity to multiple drugs with different structures can be seen despite a very limited number of drugs responsible for initiating this syndrome. Our unpublished finding that LTT to the offending drug was negative during the development of rash and became strong positive after recovery (Manuscript in preparation) could be also explained by this scenario, because these herpesviruses could induce and maintain a potent specific memory T-cell response for long times after recovery from DIHS/DRESS due to their common properties of ubiquitous prevalence in human populations and the capacity to grow in lymphoid cells.

Assuming that antiviral T cells are primarily in-

involved in the development of DIHS/DRESS, the question arises why viral genome was only detected 2–3 weeks after onset of this syndrome but not at the early stage. In this regard, of note are previous reports indicating that causative drugs shown to induce DIHS/DRESS have in common intrinsic properties to potentially cause immunosuppression.<sup>21</sup> In view of these properties of these drugs, our finding that paradoxical worsening of clinical and laboratory parameters was often observed after discontinuation of the causative drug in many patients with DIHS/DRESS<sup>6,21</sup> can be alternatively interpreted as follows: discontinuation of these drugs could be associated with rapid restoration of virus-specific cellular and humoral responses that would reduce viral loads on the one hand but cause tissue damage on the other (Fig. 4). Thus, unrecognized reactivations of herpesviruses would be already present by protracted administration of these drugs before onset of this syndrome and this reactivation may be only unmasked by rapid restoration of anti-viral immune responses due to discontinuation of these drugs. In support of this possibility, many cases with various pathogens-associated immune reconstitution syndrome (IRS) have been reported to occur in HIV-infected individuals after administration of potent antiretroviral therapy or withdrawal of immunosuppressive agents that can cause improved anti-viral immune responses.<sup>40</sup> Unlike the widely held notion, clinical symptoms in DIHS/DRESS are likely to be mediated by rapidly restored anti-viral immune responses, just like those in IRS, but not by viruses themselves. Thus, our finding of no detection of viral genome at the time of clinical onset<sup>21</sup> can be explained by assuming that virus clearance may take place upon reconstitution of a valid immune response after withdrawal of the causative drug in patients with DIHS/DRESS.

## TREATMENT

Early recognition of this syndrome is the most important step in treatment and is essential in improving patient outcomes, because many physicians are not familiar with this syndrome. Empirical treatment with antibiotics or NSAIDs should not be done during the acute period, which may confuse or worsen the clinical picture probably due to unexplained cross-reactivity.

The mainstay of treatment is systemic corticosteroids. Rapid resolution of rashes and fever occurs within several days after starting systemic corticosteroids: the usual dosage is prednisolone 40–60 mg/day. Nevertheless, this treatment has not been formally studied in randomized placebo-controlled trials; however, this trial is difficult to perform due to the life-threatening nature of this syndrome. Systemic corticosteroids need to be tapered over 6–8 weeks to prevent the relapse of various symptoms of this syn-



drome. Marked deterioration of various symptoms is often observed with accidental discontinuation or too rapid tapering of corticosteroids. We therefore recommend that all patients with DIHS/DRESS be hospitalized even if the initial presentation is mild. If symptoms deteriorate despite systemic corticosteroids, other options used successfully in small series of patients include pulsed intravenous methylprednisolone (30 mg/kg for 3 days), intravenous immunoglobulin G (IVIG), and plasmapheresis, or a combination of these. It should be further noted that these immunosuppressive therapies may enhance the risk of infectious complications and sepsis. Mild cases may recover from this syndrome by supportive care without the need of systemic corticosteroids within few weeks. Even in these mild cases, however, hepatic and renal value should be monitored closely and appropriate testing should be performed to exclude involvement of specific organs, such as lungs, heart, and thyroid, known to be affected by this syndrome. In particular, because hypothyroidism may appear for several months after the acute illness is completely resolved, thyroid function should be monitored carefully for at least several months after resolution of the acute illness.

## CONCLUSION

Although great strides have been made in our understanding of the natural history and pathomechanism (s) of this syndrome, many questions remain unanswered. DIHS/DRESS should not be regarded as a reaction solely mediated by drug antigen-driven oligoclonal expansion of T cells, but as a reaction induced by a complex interplay among viruses, antiviral innate and adaptive immune responses, and, of course, drug-specific immune responses. Thus, DIHS/DRESS provides a fascinating model for studying the complex interplay leading from viral infection to the development of allergic diseases.

## ACKNOWLEDGEMENTS

This work was supported in part by grants from Ministry of Education, Sports, Science and Culture in Japan (to T. S).

## REFERENCES

- Gern JE, Busse WW. The role of viral infections in the natural history of asthma. *J. Allergy Clin. Immunol.* 2000; **106**:201-212.
- Dahl ME, Dabbagh K, Liggitt D, Kim S, Lewis DB. Viral-induced T helper type 1 responses enhance allergic disease by effects on lung dendritic cells. *Nature Immunol.* 2004; **5**:337-343.
- Selin LK, Welsh RM. Plasticity of T cell memory responses to viruses. *Immunity* 2004; **20**:5-16.
- Pullen H, Wright N, Murdoch JM. Hypersensitivity reactions to antibacterial drugs in infectious mononucleosis. *Lancet* 1967; **2**:1176-1178.
- Coopman SA, Johnson R, Platt R, Stern R. Cutaneous disease and drug reactions in HIV infection. *N. Engl. J. Med.* 1993; **328**:1670-1674.
- Suzuki Y, Inagi R, Aono T, Yamanishi K, Shiohara T. Human herpesvirus 6 infection as a risk factor for the development of severe drug-induced hypersensitivity syndrome. *Arch. Dermatol.* 1998; **134**:1108-1112.
- Tohyama H, Yahata Y, Yasukawa M *et al.* Severe hypersensitivity syndrome due to sulfasalazine associated with reactivation of human herpesvirus 6. *Arch. Dermatol.* 1998; **134**:1113-1117.
- Descamps V, Collot S, Mahe E, Houhou N, Crickx B, Ranger-Rogez S. Active human herpesvirus 6 infection in a patient with drug rash with eosinophilia and systemic symptoms. *J. Invest. Dermatol.* 2003; **121**:215-216.
- Prussick R, Shear NH. Dapsone hypersensitivity syndrome. *J. Am. Acad. Dermatol.* 1996; **35**:346-349.
- Shear NH, Spielberg SP. Anticonvulsant hypersensitivity syndrome. *In vitro* assessment of risk. *J. Clin. Invest.* 1988; **82**:1826-1832.
- Lupton GP, Odon RB. The allopurinol hypersensitivity syndrome. *J. Am. Acad. Dermatol.* 1979; **1**:365-374.
- Sanders DY, Thompson JR, Carlton FB. Phenytoin hypersensitivity syndrome. *J. Miss. State Med. Assoc.* 1996; **37**:471-475.
- Taliercio CP, Olney BA, Lie JT. Myocarditis related to drug hypersensitivity. *Mayo. Clin. Proc.* 1986; **60**:463-468.
- Engel JN, Mellul VG, Goodman OB. Phenytoin hypersensitivity: a case of severe acute rhabdomyolysis. *Am. J. Med.* 1986; **81**:928-930.
- Fujino Y, Nakajima M, Inoue H, Kusuhara T, Yamada T. Human herpesvirus 6 encephalitis associated with hypersensitivity syndrome. *Ann. Neurol.* 2002; **51**:771-774.
- Sekine N, Motokura T, Oki T *et al.* Rapid loss of insulin secretion in a patient with fulminant type 1 diabetes mellitus and carbamazepine hypersensitivity syndrome. *JAMA* 2001; **285**:1153-1154.
- Horneff G, Lenard HG, Wahn V. Severe adverse reaction to carbamazepine: Significance of humoral and cellular reactions to the drug. *Neuropediatrics* 1992; **23**:272-275.
- Parker WA, Shearer CA. Phenytoin hepatotoxicity: a case report and review. *Neurology* 1979; **29**:175-177.
- Brown M, Schubert T. Phenytoin hypersensitivity hepatitis and mononucleosis syndrome. *J. Clin. Gastroenterol.* 1986; **8**:469-477.
- Vittorio CC, Muglia JJ. Anticonvulsant hypersensitivity syndrome. *Arch. Intern. Med.* 1995; **155**:2285-2290.
- Kano Y, Inaoka M, Shiohara T. Association between anti-convulsant hypersensitivity syndrome and human herpesvirus 6 reactivation and hypogammaglobulinemia. *Arch. Dermatol.* 2004; **140**:183-188.
- Pichler WJ, Tilch J. The lymphocyte transformation test in the diagnosis of drug hypersensitivity. *Allergy* 2004; **59**:809-820.
- Houwerzijl J, De Gast GC, Nater JP, Esselink MT, Nieweg HO. Lymphocyte-stimulation tests and patch tests in carbamazepine hypersensitivity. *Clin. Exp. Immunol.* 1977; **29**:272-277.
- Zakrzewska JM, Ivanyi L. *In vitro* lymphocyte proliferation by carbamazepine, carbamazepine-10, 11-epoxide, and oxcarbamazepine in the diagnosis of drug-induced hypersensitivity. *J. Allergy Clin. Immunol.* 1988; **82**:110-115.
- Hamanaka H, Mizutani H, Nouchi N, Shimizu Y, Shimizu M. Allopurinol hypersensitivity syndrome: hypersensitivity to oxypurinol but not allopurinol. *Clin. Exp. Dermatol.* 1998; **23**:32-34.

26. Aihara M, Sugita Y, Takahashi S *et al.* Anticonvulsant hypersensitivity syndrome associated with reactivation of cytomegalovirus. *Br. J. Dermatol.* 2001;**144**:1231-1234.
27. Descamps V, Mahe E, Houhou N *et al.* Drug-induced hypersensitivity syndrome associated with Epstein-Barr virus infection. *Br. J. Dermatol.* 2003;**148**:1032-1034.
28. Aihara M, Mitani N, Kakemizu N *et al.* Human herpesvirus infection in drug-induced hypersensitivity syndrome, toxic epidermal necrolysis and Stevens-Johnson syndrome. *Allergol. Int.* 2004;**53**:23-29.
29. Kano Y, Shiohara T. Sequential reactivation of herpesvirus in drug-induced hypersensitivity syndrome. *Acta Derm. Venereol.* 2004;**84**:484-485.
30. Bonilla PAG, Aquilera GR, Brito FF *et al.* Phenytoin hypersensitivity syndrome with positive patch test. A possible cross-reactivity with amitriptyline. *Invest. Allergol. Clin. Immunol.* 1998;**8**:186-190.
31. De Vriese ASP, Philippe J, Van Renterghen DM *et al.* Carbamazepine hypersensitivity syndrome; Report of 4 cases and review of the literature. *Medicine* 1995;**74**:144-151.
32. Hashimoto K, Yasukawa M, Tohyama M. Human herpesvirus 6 and drug allergy. *Curr. Opin. Allergy Clin. Immunol.* 2003;**3**:255-260.
33. Zaia JA. Viral infections associated with bone marrow transplantation. *Hematology/Oncology Clinics of North America* 1990;**4**:603-623.
34. Maeda Y, Teshima T, Yamada M *et al.* Monitoring of human herpesviruses after allogeneic peripheral blood stem cell transplantation and bone marrow transplantation. *Br. J. Hematol.* 1999;**105**:295-302.
35. Maeda Y, Teshima T, Yamada M, Harada M. Reactivation of human herpesviruses after allogeneic peripheral blood stem cell transplantation and bone marrow transplantation. *Leuk. Lymphoma* 2000;**39**:229-239.
36. Dockrell DH, Paya CV. Human herpesvirus-6 and -7 in transplantation. *Rev. Med. Virol.* 2001;**11**:23-36.
37. Appleton AL, Sviland L. Pathogenesis of GVHD: role of herpes viruses. *Bone Marrow Transplant* 1993;**11**:349-355.
38. Wang F-Z, Larsson K, Linde A, Ljungman P. Human herpesvirus 6 infection and cytomegalovirus-specific lymphoproliferative responses in allogeneic stem cell transplant recipients. *Bone Marrow Transplant* 2002;**30**:521-526.
39. Katsafanas GC, Schirmer EC, Wyatt LS, Frenkel N. *In vitro* activation of human herpesviruses 6 and 7 from latency. *Pro. Natl. Acad. Sci. U.S.A.* 1996;**93**:9789-9792.
40. Hirsch HH, Kaufmann G, Sendi P, Battagay M. Immune reconstitution in HIV-infected patients. *Clin. Infect. Dis.* 2004;**38**:1159-1166.