

## Case Report

# A case of chronic urticaria due to *Dirofilaria* infestation

Andrea Matucci,<sup>1</sup> Paola Parronchi,<sup>1</sup> Oliviero Rossi,<sup>1</sup> Alessandra Vultaggio,<sup>1</sup> Gaia Deleonardi,<sup>1</sup> Alessandra Orsi,<sup>2</sup> Enrico Maggi<sup>1</sup> and Sergio Romagnani<sup>1</sup>

<sup>1</sup>Department of Internal Medicine, Section of Immunoallergology and Respiratory Diseases, University of Florence and <sup>2</sup>Laboratory of Microbiology, Virology and Parasitology, Azienda Ospedaliera Careggi, Florence, Italy

### ABSTRACT

Urticaria is one of the most common dermatological conditions occurring mainly in children and adolescents and in atopic individuals. The term of chronic idiopathic urticaria (CIU) is used when the pathophysiological mechanisms remain unclear. Chronic infections and parasitic infestations have been suggested to play an important role in the etiology of CIU. In the present paper, we describe a case of chronic, apparently idiopathic urticaria in an adult woman where *Dirofilaria* has been recognized to play a pathogenic role in the determination of the cutaneous disease.

**Key words:** chronic urticaria, *Dirofilaria*.

### INTRODUCTION

Urticaria is one of the most common dermatological conditions, mainly occurring in children and adolescents, as well as in atopic individuals. Urticaria is defined by wheals, with or without angioedema, appearing within minutes to hours, usually disappearing within 24 h and accompanied by pruritus. Urticaria is caused by cutaneous mast cell and/or basophil degranulation due to immunological and non-immunological causes. Following degranulation, potent vasoactive mediators that induce vasodilatation are released, resulting in classical cutaneous manifestations.<sup>1</sup> Among the mediators, histamine plays an essential role, but other substances,

such as eicosanoids, kinins, serotonin and neuropeptides, may also be involved.<sup>2</sup> Moreover, mononuclear cells, lymphocytes, eosinophils, platelets or endothelial cells are also involved in the late-phase reaction, in which cytokines, chemokines and adhesion molecules play a major role.<sup>3,4</sup> Persistence of urticaria beyond 6 weeks is defined as chronic urticaria. The term 'chronic idiopathic urticaria' (CIU) is used when the pathophysiological mechanisms remain unclear. The etiopathophysiology of chronic urticaria is usually more difficult to determine than that of acute urticaria.<sup>5</sup> Chronic infections and parasitic infestations have been suggested to play an important role in the etiology of CIU and it has been suggested that viral, bacterial, parasitic or fungal antigens may form immune complexes together with their specific antibodies, then bind to the vascular walls and activate complement.<sup>6</sup> In any case, it is quite unusual to recognize a parasite infestation as the only cause of CIU.

In the present paper, we describe a case of chronic apparently idiopathic urticaria in an adult woman in whom *Dirofilaria* has been recognized to play a pathogenic role in the determination of the cutaneous disease.

### CASE REPORT

A 63-year-old woman presented with CIU that had started 1 year previously. The patient showed giant urticaria with intense pruritus resistant to common antihistamine treatment and only partially and temporarily responsive to corticosteroid therapy. The cutaneous lesions were classical pale red wheals, more than 10 cm in diameter, diffuse to the entire body but prevalently localized at the trunk and legs, showing less than 24 h duration and disappearing without chromatic alterations. Allergological investigations performed in different

Correspondence: Dr Andrea Matucci, Department of Internal Medicine, Section of Immunoallergology and Respiratory Diseases, Policlinico di Careggi/University of Florence, Viale Morgagni 85, 50134 Firenze, Italy. Email: a.matucci@dmi.unifi.it

Received 19 December 2003. Accepted for publication 18 May 2004.

departments in the absence of therapy were completely negative. In particular, skin prick tests for inhalant and food allergens were negative, as were patch tests for common haptens. Specific and total IgE had been detected with normal results. The history of the patient was negative for allergic manifestations at the ocular or respiratory level. Moreover, the patient denied any hypersensitivity reactions to foods or the occurrence of any adverse reaction including urticaria/angioedema after drug intake.

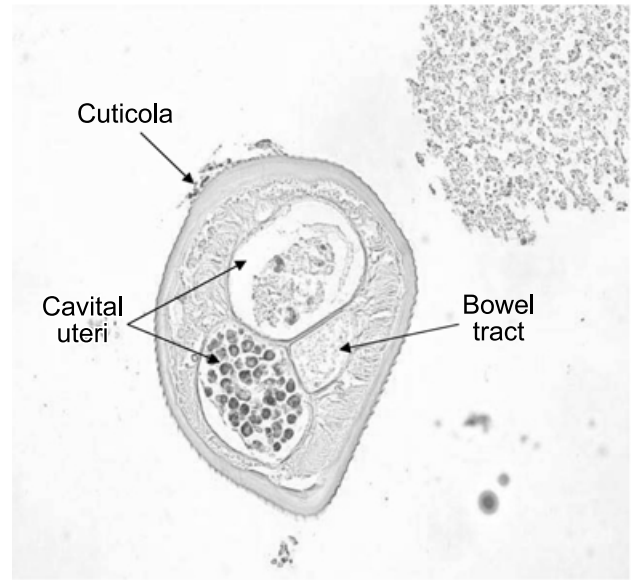
At clinical examination, in addition to classical wheals, some nodules were detected at the right axillary region and these nodules were characterized echographically as cystic nodules showing peculiar features.

Laboratory tests showed normal levels of  $\gamma$ -globulins (IgG 1500 mg/dL, IgM 89 mg/dL and IgA 154 mg/dL), aspartate aminotransferase, alanine aminotransferase and glutamyl transpeptidase and a normal number of white cells in the peripheral blood. In particular, the eosinophils ranged between 2 and 4%. Analysis of the phenotypic profile of circulating CD3<sup>+</sup> cells showed a normal number of CD4<sup>+</sup> and CD8<sup>+</sup> T cells. The complement (C3 and C4) fractions were within the normal range. Culture analysis of repeated fecal specimens was negative for parasitic or mycotic infestations. The prick test for inhalant and food allergens was negative. The detection of specific serum IgE antibodies (CAP RAST FEIA; Pharmacia, Upsalla, Sweden) failed to show any sensitization towards foods or inhalant allergens, the total serum IgE level being 75 kU/L.

An excisional biopsy of one of the cutaneous nodules revealed inflammatory tissue containing a high number of eosinophils and structures consistent with parasitic sections. The specimen was then analyzed in the Laboratory of Microbiology, Parasitology and Virology of Florence University Hospital, where the parasites were identified. The parasites showed characteristic morphological features of *Dirofilaria repens* (Fig. 1). Radical surgical excision of the nodules was performed and the clinical condition of the patient improved rapidly, with complete disappearance of urticaria within 2 weeks.

## DISCUSSION

In this paper, we present the first case, to our knowledge, of human dirofilariasis associated with CIU. *Dirofilaria* species are nematode parasites that are widely distributed in southern Europe, mostly infecting dogs and cats but, more rarely, also humans.<sup>7</sup>



**Fig. 1** Transverse section of a female *Dirofilaria repens*, identified at the histological examination of one of the cutaneous nodules, showing the presence of oocytes in the uterine sections. The digestive system is a unique tube that can vary in terms of its position in the body cavity, diameter and contents. In the present case, amorphous material is present. Sections of the female reproductive organs show the existence of two tubes, as shown in the present histological specimen. The lateral spicula can be seen in the section because it is close to the caudal end.

In humans, these parasites seldom or never complete their life cycle and do not usually reach the adult stage, so that filaremia is exceptional. The parasites are transmitted to humans by zoonanthrophilic blood-sucking insects. Two types of clinical presentation have been described: pulmonary and subcutaneous dirofilariasis.<sup>7</sup> In this second form, subcutaneous nodules can be distributed widely all over the body resulting from the colonization of filarids. Definitive diagnosis and treatment most often result from surgical excision of the nodules, which also allows microscopic examination. The segregation of worms into the tissues is probably the cause of the usual absence of circulating anti-*Dirofilaria* antibodies in patients. Thus, excisional biopsy is both diagnostic and therapeutic. In the present patient, diagnosis and resolution of the clinical manifestations were achieved by excisional biopsy.

Thus, it is recommended that dirofilariasis should be taken into account by both clinicians and pathologists in the differential diagnosis of patients with CIU and subcutaneous nodules.

## REFERENCES

- 1 Greaves MW. Chronic urticaria. *N. Engl. J. Med.* 1995; **332**: 1767–72.
- 2 Berlow RJ, Ross EL, MacDonald DM, Black AK, Greaves MW. Mast cells and T lymphocytes in chronic urticaria. *Clin. Exp. Allergy* 1995; **25**: 317–22.
- 3 Kuna P, Reddigari ST, Schall TJ, Rucinski D, Viksman MY, Kaplan AP. RANTES, a monocyte and T lymphocyte chemotactic cytokine releases histamine from human basophils. *J. Immunol.* 1992; **146**: 636–42.
- 4 Romagnani P, De Paulis A, Beltrame C *et al.* Tryptase-chymase double-positive human mast cells express the eotaxin receptor CCR3 and are attracted by CCR3-binding chemokines. *Am. J. Pathol.* 1999; **155**: 1195–204.
- 5 Liutu M, Kalimo K, Uksila J, Kalimo H. Etiological aspects of chronic urticaria. *Int. J. Dermatol.* 1998; **37**: 515–19.
- 6 Greaves MW. Chronic idiopathic urticaria (CIU) and *Helicobacter pylori*: Not directly causative, but could there be a link? *Aci. Int.* 2001; **13**: 23–6.
- 7 Muro A, Genchi C, Cordero M, Simon F. Human dirofilariasis in the European Union. *Parasitol. Today* 1998; **15**: 386–9.