

Original Article

Pressure on Anterior Region of Palate during Thumb-Sucking

Reiko Yokota, Masayoshi Mishiro, Terumi Abe*, Akiko Miyake, Nene Shiina***, Kenji Sueishi and Hideharu Yamaguchi*****

*Department of Clinical Oral Health Science, Tokyo Dental College,
2-9-18 Misaki-cho, Chiyoda-ku, Tokyo 101-0061, Japan*

** Kouzaki Orthodontic Clinic,
1-38-11 Nakagawachuo, Tsuzuki-ku, Yokohama, Kanagawa 224-0003, Japan*

*** Fukumashi Orthodontic Clinic,
1-1 Hakuraku, Kanagawa-ku, Yokohama, Kanagawa 221-0065, Japan*

**** Department of Orthodontics, Tokyo Dental College,
1-2-2 Masago, Mihama-ku, Chiba 261-8502, Japan*

Received 29 January, 2007/Accepted for publication 25 May, 2007

Abstract

Measurement of the pressure applied to the anterior region of the palate and incisor region of the mandible during thumb-sucking was carried out 3 female children. A polyethylene bag embedded with a high-sensitivity small pressure sensor was fixed on the ventral side of the thumb so that the baroreceptor could be interposed between the thumb and palate during thumb-sucking. The children were allowed to perform habitual thumb-sucking, and the resulting pressure signals were detected with a high-response dynamic strainmeter and recorded. Measured peak pressures were about 2–4.5 kgw, with large individual variation, and waveform patterns also varied. Characteristics of thumb-sucking habits and thumb-sucking pressure were related to malocclusion. Measurement of thumb-sucking pressure is believed to be effective for assessment of the qualitative relationship between thumb-sucking and malocclusion.

Key words: Oral habit—Finger-sucking—Thumb-sucking—Pressure—Pressure sensor

Introduction

Malocclusion is caused by genetic and environmental factors, but the period during which deciduous dentition is replaced by permanent dentition is also when the function of perioral muscles is established, and oral habits in this period are likely to be factors in

malocclusion. A number of studies have suggested that some oral habits in small children are physiologic^{5,6,8,9,21}. However once oral habits persist for some reason and become chronic, their resolution is difficult^{3,4,8,9,18,21}. Prolongation of oral habits may exert marked effects on the morphology and function of the stomatognathic system during the growth



Fig. 1 High-response dynamic strainmeter DPM-612B; oscillographic recorder RDM-100A

period and cause abnormalities in dentition and occlusion. There are a large number of reports on patterns of appearance and disappearance of oral habits^{15,22,23}.

Finger-sucking is a common oral habit, and was observed by Kurosu *et al.*¹¹ in 28.0% of children aged 1–14 years, by Kamiyama *et al.*⁶ in 23.3% of children aged 2–6 years, and by Abe *et al.*¹ in 18.9% of children aged 0–12 years. Finger-sucking often exerts adverse effects on dentition and occlusion^{4,5,8–10,12,13,15,18,20,21}, and open bite, maxillary protraction, narrowing of the maxillary dentition, molar crossbite, posteroinferior displacement of the mandible, and crowding of the mandibular incisors may be caused by this habit^{5,7,8,11,15,21,23}. Abnormal muscular activities in the lips and tongue have been reported in association with such morphological changes, complicating or exacerbating malocclusion. Although, there are many reports on thumb-sucking, few have employed objective measurement of thumb-sucking pressure, the quantitative analysis of which might allow estimation of the effects of the habit.

In this study, we developed a baroreceptor device for the measurement of the pressure applied to the anterior region of the palate and incisor region of the mandible during

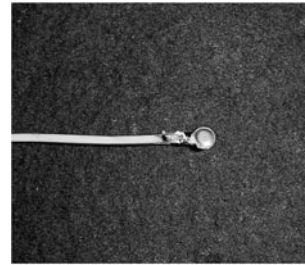


Fig. 2 Ultra-small pressure sensor, Model PSM-1KAB-S-H12

thumb-sucking and evaluated the resulting measurements.

Materials and Methods

1. Subjects

The subjects consisted of 3 children with a thumb-sucking habit who visited the Department of Orthodontics, Tokyo Dental College Chiba Hospital. An outline of the study was explained to the patients and their parents before the study, and their consent and cooperation were obtained.

2. Method of measurement

An ultra-small pressure sensor, Model PSM-1KAB-S-H12 (Fig. 1), was connected to a high-response dynamic strainmeter, DPM-612B, and the output was recorded with an oscillographic recorder, RDM-100A (Fig. 2). All these instruments were obtained from Kyowa Electronic Instruments Co., Ltd. A baroreceptor device for measurement of thumb-sucking pressure would be required to fulfill the following conditions, and so such a baroreceptor device was prepared accordingly. (1) Pressure applied to a wide area should be detectable by a single sensor, (2) the device should not interfere with the usual thumb-sucking movements, (3) it should tolerate thumb and tongue movements, (4) it should have appropriate sensitivity and reproducibility, (5) it should be easy to attach and remove and be used repeatedly, and (6) it should not be affected by the oral environment, includ-

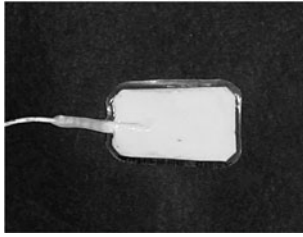


Fig. 3 Baroreceptor

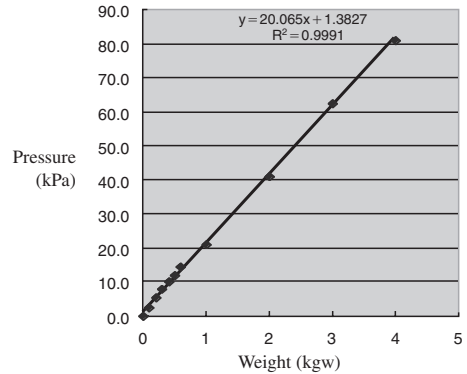


Fig. 4 Weight-pressure conversion equation

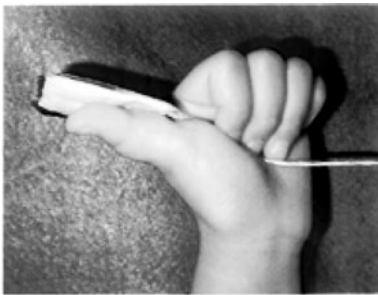


Fig. 5 Baroreceptor was attached to ventral side of thumb

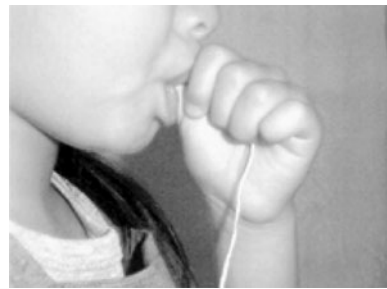

Fig. 6 Baroreceptor was interposed between thumb and palate

ing saliva.¹⁷⁾ In this study a rectangular polyethylene bag was filled with 5g commercial tooth paste. The pressure sensor was placed in the center of the bag, and the bag was sealed according to the method of Miyake *et al.*^{2,16,17)} The baroreceptor was 40 mm long, 25 mm wide, and about 3 mm thick near the center (Fig. 3). The weight-bearing characteristic of the baroreceptor was linear, and it was represented by a weight-pressure conversion equation of $y = 20.27x + 1.38$ (x : weight [kg], y : pressure [kPa]) (Fig. 4).

The subjects were seated in a relaxed state, and the baroreceptor device was attached to the ventral side of the thumb by using double-sided adhesive tape so that it would be interposed between the thumb and palate, and the subjects were allowed to perform thumb-sucking (Figs. 5, 6). The subjects practiced thumb-sucking repeatedly until they were suffi-

ciently adapted to the environment and were relaxed. Recording was performed over several minutes. The baseline of the oscillographic recorder was determined by adjusting the value when the baroreceptor was fixed on the thumb and pressure was measured without loading to zero. Pressure during thumb-sucking was analyzed by selecting 20-second segments of the records considered to show typical waveforms for each subject.

Results

1. Case 1

This patient was a girl aged 8 years and 9 months. She visited the hospital due to open bite in the incisor region. Her oral findings showed a dental age of IIIA, overjet -0.5 mm, overbite -3.5 mm, and a low incisor height.

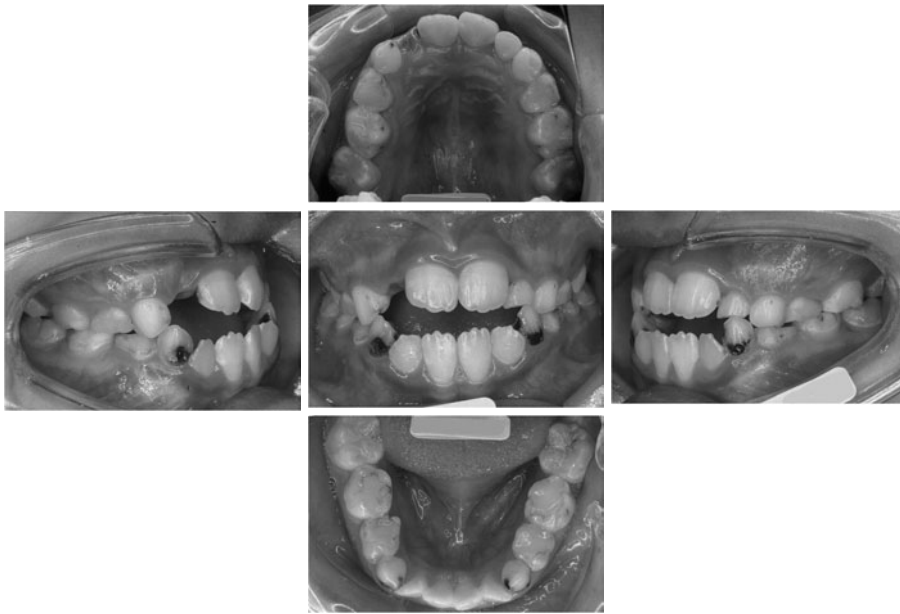


Fig. 7-1 Case 1: Oral photo

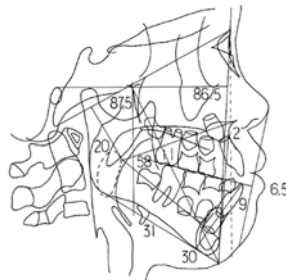


Fig. 7-2 Case 1: Cephalometric analysis

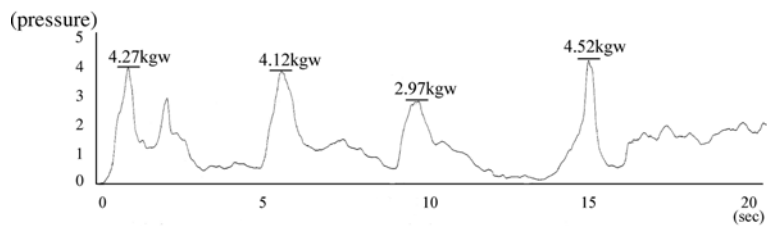


Fig. 7-3 Case 1: Thumb-sucking pressure waves

She had a mesial step-type terminal plane (Fig. 7-1). Airway problems included adenoids, large tonsils, and habitual mouth breathing.

Tongue-thrust was observed in vocalization and swallowing, and the mentum was taut on closing the lips.

Cephalometric analysis of skeletal characteristics revealed a severe dolichofacial pattern, with low facial height and a large mandibular plane, and counter-clockwise rotation of the mandible was noted. Dentally, the mandibular incisors showed labial inclination, and the maxillary incisors were low (Fig. 7-2).

Concerning the characteristics of her thumb-sucking habit, the patient sucked the right thumb deeply down to its base. She was seen to bite into the thumb hard with the mandibular incisors, and distinct callosity was noted on the dorsum of the thumb. Thumb-sucking was observed only before falling asleep. Concerning thumb-sucking pressure waves, a large peak was noted about every 5 seconds. Sucking frequency was low, and peak pressure was very high, at about 3–4.5 kgw (Fig. 7-3). We decided to apply a palatal plate with a tongue crib, and carry out myofunctional therapy as orthodontic treatment.

2. Case 2

The patient was a girl aged 10 years and 11 months. She visited the hospital due to crowding and maxillary protraction. Oral findings were as follows: dental age IIIB, overjet 6 mm, overbite 0 mm, and a distal step-type terminal plane. The mandibular incisors showed crowding, the dental arches were narrowed, and the maxillary central incisors were labially inclined (Fig. 8-1). Airway problems included adenoids and large tonsils. Tongue-thrust was noted during vocalization.

Cephalometric analysis revealed a mild brachyfacial type and her skeletal characteristics were class II, with anterior shifting of both the maxilla and the mandible. Concerning the teeth, the maxillary incisors were labially inclined (Fig. 8-2).

Thumb-sucking was observed only before falling asleep, and was accompanied by a habit of biting the lower lip. The patient opened the right palm in a relaxed state, inserted the thumb halfway into the mouth, and gently sucked it. Callosity on the dorsum of the thumb was mild. The amplitude of the thumb-sucking pressure waves was low, and a continuous pressure of about 2 kgw was noted

(Fig. 8-3). We decided to apply head gear and a utility arch for treatment of maxillary protrusion, and carry out myofunctional therapy as orthodontic treatment.

3. Case 3

The patient was a girl aged 12 years and 10 months. She visited the hospital due to median diastema. Oral findings were as follows: dental age IVA, overjet 4 mm, overbite –3.5 mm, and the molar relationship was class I. The frenulum of the upper lip was thick and attached at a high position. The bilateral maxillary canine teeth were impacted, and the deciduous canine teeth persisted. The lateral incisors were dwarfed. The dentition showed V-shaped dental arches, and the maxillary incisors showed marked labial inclination and were low. Diastemata were observed in the dentition, and the median diastema was particularly wide (Fig. 9-1). Airway problems included large tonsils, mouth-breathing, and low tongue. Tongue-thrust was noted during vocalization and swallowing.

Cephalometric analysis revealed a mild brachyfacial type. Concerning the skeleton, mandibular protraction was observed. Regarding the teeth, the maxillary incisors showed marked labial inclination and were low (Fig. 9-2).

Thumb-sucking was observed before falling asleep. The patient gently closed the right palm and sucked the thumb down to its base in a manner that allowed it to fit into a space in the median maxillary region. Marked callosity was noted on the dorsum of the right thumb. The thumb-sucking pressure showed high-frequency, rhythmical, large waves occurring at a rate of about once a second. Peak sucking pressure was 2–3.5 kgw (Fig. 9-3). We decided to control the habit by applying a fixed lateral expander, as orthodontic treatment.

Discussion

1. Baroreceptor

In measuring pressure produced by the thumb or tongue during thumb-sucking in a

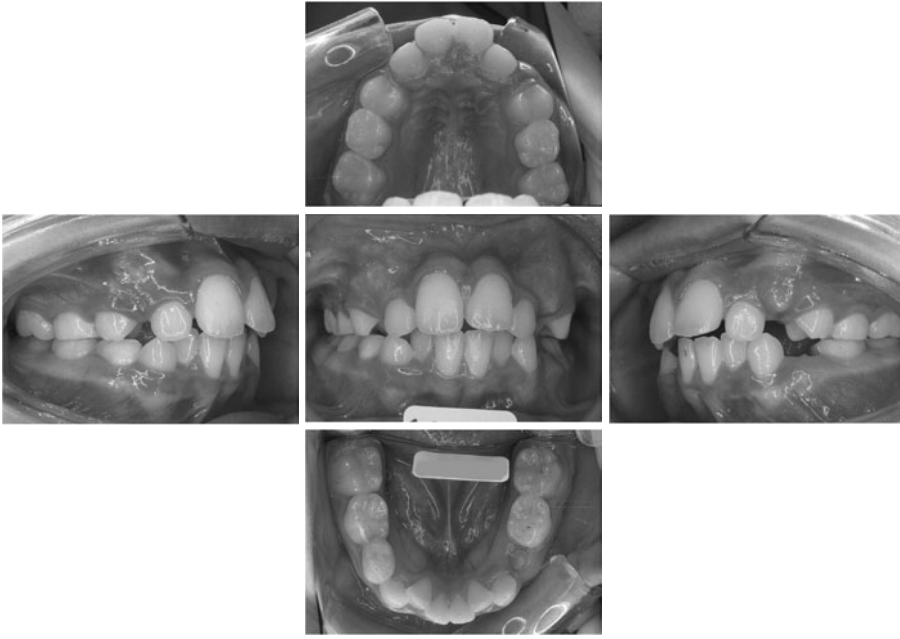


Fig. 8-1 Case 2: Oral photo

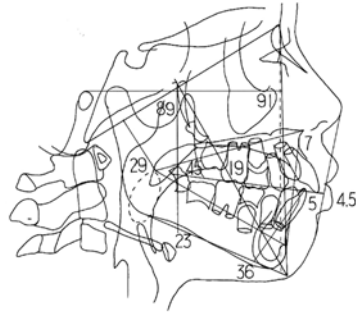


Fig. 8-2 Case 2: Cephalometric analysis

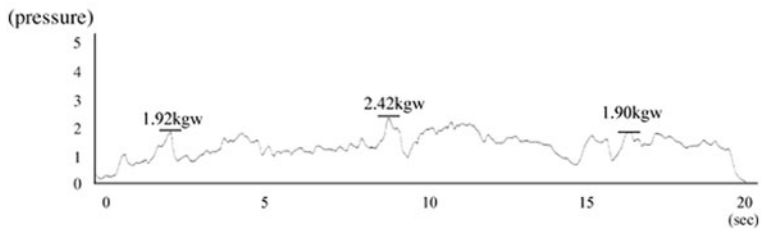


Fig. 8-3 Case 2: Thumb-sucking pressure waves

limited region using a small sensor, the values indicated by the sensor do not include the pressure applied to areas other than the area

targeted. Therefore, a polyethylene bag filling with fluid was used as the pressure sensor¹⁷⁾. The baroreceptor had a thickness of about

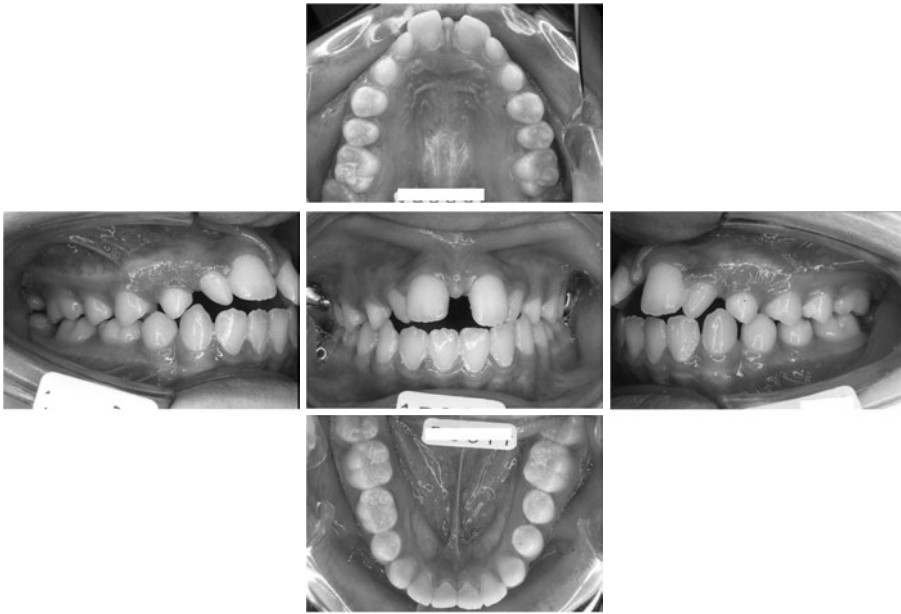


Fig. 9-1 Case 3: Oral photo

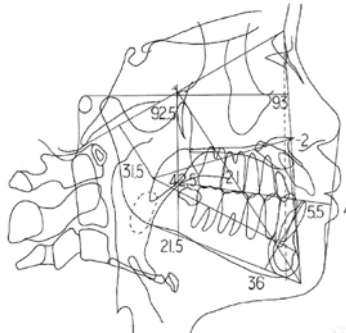


Fig. 9-2 Case 3: Cephalometric analysis

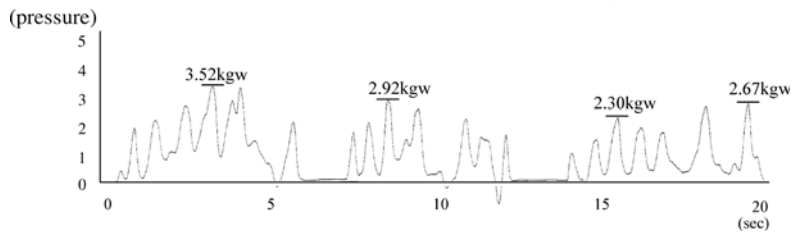


Fig. 9-3 Case 3: Thumb-sucking pressure waves

3 mm. Therefore, it may have registered a pressure higher than the real pressure due to protrusion. Furthermore, thumb-sucking is

often performed unconsciously during the night, so the measurements obtained in this study do not precisely represent the pressures

produced by natural thumb-sucking. However, if pressures can be measured under fixed conditions, the pressure waves associated with thumb-sucking movements can be recorded. If those results are reproducible, the values obtained should be sufficient to allow evaluation of thumb-sucking pressure.

2. Relationship between thumb-sucking and malocclusion

Subtelny and Subtelny¹⁹⁾ studied 34 children with a thumb-sucking habit by cineradiography and classified the habit into the following 4 types according to the positions of the inserted finger and mandibular incisors.

- A: The thumb is inserted deeply, its belly touches the palate, and the mandibular incisors touch the thumb. (50%)
- B: The belly of the thumb is not in contact with the palate. (24%)
- C: The mandibular incisors are not in contact with the thumb. (18%)
- D: The thumb is inserted shallowly, not as far as the first joint. (6%)

When this classification was applied to our subjects, Case 1 was classified as type A, Case 2 as type D and Case 3 as type A.

Subtelny and Subtelny also reported that angle classification was class I in 46% and class II in 54%, that cephalometric analysis showed anterior shift and labial inclination of both the maxillary and mandibular dentition, and that thumb-sucking was a cause of open bite of the incisors and labial inclination of the maxillary incisors. Moreover, they classified thumb-sucking into 2 types according to the positional relationship between the tongue and thumb, and into 3 types according to the degree of mandibular movements during sucking, and evaluated the relationships of thumb-sucking types with malocclusion. As a result, they reported that although labial inclination of the maxillary and mandibular incisors was observed in patients with no or small mandibular movements, the dental axes of the mandibular incisors were upright in those with large mandibular movements.

In this study, also, Cases 1 and 3, classified as type A with deep insertion of the thumb

and a relatively strong sucking pressure, showed malocclusion characterized by vertical open bite, and Case 2, classified as type D with shallow insertion of the thumb and a weak but continuous pressure, showed malocclusion characterized by anterior-posterior open bite. Therefore, the characteristics of thumb-sucking and thumb-sucking pressure are suggested to be related to open bite type, and thumb-sucking pressure measurement may be useful in the assessment of these relationships.

3. Thumb-sucking pressure

Concerning pressure changes in the perioral muscles associated with thumb-sucking, Luffingham¹⁴⁾ measured buccal pressure in the maxillary molar region and suggested that an increase in buccal pressure leads to a decrease in the width of the maxillary dentition. However, he did not measure the pressure in the maxillary incisor region. According to our present measurements, peak pressure during thumb-sucking was 4.52 kgw in Case 1, 2.42 kgw in Case 2, and 3.52 kgw in Case 3. Mishiro *et al.*¹⁶⁾ studied 60 female children aged 7–12 years using a pressure sensor similar to ours on the anterior region of the palate. They reported a maximum tongue pressure of 1.57 kgw in the normal palate group, 1.65 kgw in the maxillary protraction group, and 1.80 kgw in the mandibular protraction group. In our study, maximum pressure during thumb-sucking was clearly larger than tongue pressure in all subjects. During thumb-sucking, pressure on the dentition is believed to have been increased by forces of direct compression by the thumb and biting and negative pressure due to sucking, as well as intrinsic maximum tongue pressure. Thumb-sucking pressure measured in this study far exceeded tongue pressure, causing malocclusion and potential dental migration.

Conclusion

Pressure during thumb-sucking was mea-

sured in 3 female children. The observed pressure waves were associated with the characteristics of thumb-sucking habits. In addition, the characteristics of the thumb-sucking habits and thumb-sucking pressure were related to state of malocclusion. The findings suggest that measurement of thumb-sucking pressure is useful in the analysis of qualitative relationships between thumb-sucking habits and malocclusion.

References

- 1) Abe T, Matsuzaki K, Yakushiji M, Machida Y (1987) A clinical observation on changes in oral-habit incidence. *Shikwa Gakuho* 87:95–103. (in Japanese)
- 2) Abe T, Miyake A, Mishihiro M, Yokota R, Sueishi K, Yamaguchi H (2004) Measurements of the maximal and swallowing tongue pressures at the anterior region of the palate—Case of maxillary protrusion and mandibular prognathism—. *J Tokyo Orthod Soc* 14:3–9. (in Japanese)
- 3) Graber TM (1958) The finger-sucking habit and associated problems. *J Dent Child* 25: 145–151.
- 4) Hukada H (1952) Relationship between malocclusion of deciduous dentures and pernicious habits. *J Jpn Orthod Soc* 12:351–353. (in Japanese)
- 5) Johnson LR (1939) The status of thumb-sucking and finger-sucking. *J Am Dent Assoc* 26:1245–1254.
- 6) Kamiyama K, Mayanagi H, Saitou S, Igarashi K, Tsukada N (1975) Questionnaire on the habits of nursery school children (1) The Japanese Journal of Oral Habits. *Jpn J Ped Dent* 13:36–41. (in Japanese)
- 7) Kamiyama K, Mayanagi H, Saitou S, Igarashi K, Tsukada N (1976) Survey of the oral habits of nursery school children (2) The between oral habits and occlusion of deciduous anterior teeth. *Jpn J Ped Dent* 14:1–5. (in Japanese)
- 8) Kawata T, Nakagawa H, Ohtani S, Kushima F, Ishida N, Takimoto K (1971) Experimental study on abnormal habits and malocclusion—Acquirement of finger habits—. *J Jpn Orthod Soc* 30:18–24. (in Japanese)
- 9) Kawata T, Nakagawa H, Ohtani S, Kushima F, Ishida N, Takimoto K (1972) Experimental study on abnormal habits and malocclusion—Disappearance of finger habits—. *J Jpn Orthod Soc* 31:137–143. (in Japanese)
- 10) Kein ET (1971) The thumb-sucking habit: meaningful or empty? *Am J Orthod* 59: 283–289.
- 11) Kurosu K, Fukuda O, Yoshioka T, Emi Y (1978) A study of the psychosomatic odontology on oral habits—The conditions of the appearance, life environment and its influence on the oral habit of children. *Jpn J Ped Dent* 16:123–136. (in Japanese)
- 12) Larrson E (1972) Dummy- and finger-sucking habits with special attention to their significance for facial growth and occlusion. 4. Effect on facial growth and occlusion. *Sven Tandlak Tidskr* 65:605–634.
- 13) Larrson E (1972) Dummy- and finger-sucking habits with special attention to their significance for facial growth and occlusion. 5. Improvement of malocclusion after termination of the habit. *Swed Dent J* 65:635–642.
- 14) Luffingham J (1970) A study of the buccal forces exerted upon teeth during finger-sucking. *Dent Pract Dent Rec* 21:95–99.
- 15) Mayanagi H, Yamada K, Sakurai S, Chiba K, Kamiyama K (1984) Studies of oral health examination of one and a half year old infants—The relationship between oral habits, dental caries and malocclusion in deciduous dentition. *Jpn J Ped Dent* 22:294–306. (in Japanese)
- 16) Mishihiro M, Miyake A, Abe T, Yokota R, Sueishi K, Yamaguchi H (2004) Measurements of the tongue pressures on the anterior region of the palate in children—About the difference arising from the occlusion and the existence of the tongue habit. *J Tokyo Orthod Soc* 14: 153–162. (in Japanese)
- 17) Miyake A, Abe T, Mishihiro M, Yokota R, Sueishi K, Yamaguchi H, Jinbo Y (2003) Measurements of the maximum and swallowing tongue pressures of the anterior region of the palate. *J Tokyo Orthod Soc* 13:221–230. (in Japanese)
- 18) Popovich F, Thompson GW (1973) Thumb and finger sucking; its relation to malocclusion. *Am J Ortho* 63:148–155.
- 19) Subtelny JD, Subtelny JD (1973) Oral habits—Studies in form, function, and therapy. *Angle Orthod* 43:347–383.
- 20) Takimoto K, Susami R, Nakago T, Iwasaki S, Hamada T (1961) A case of open bite caused by thumb-sucking. *J Japan Orthodontic Society* 20:82–87. (in Japanese)
- 21) Traisman AS, Traisman HS (1958) Thumb and finger sucking: A study of 2,650 infants and children. *J Pediatr* 52:566–572.
- 22) Yokoi K, Yamauchi T, Suzuki Y, Fukuda O, Kurosu K (1986) A clinical observation on oral habits for ten years. Part 1, Appearance and changes in the year. *Jpn J Ped Dent* 24:

- 450–458. (in Japanese)
- 23) Yonezu T, Ohno Y, Ohtawa Y, Machida Y (1984) Change of occlusion and oral habits in children during 1 year and 6 months to 2 years of age. *Jpn J Ped Dent* 22:200–206. (in Japanese)

Reprint requests to:

Dr. Reiko Yokota
Department of Clinical Oral
Health Science,
Tokyo Dental College,
2-9-18 Misaki-cho, Chiyoda-ku,
Tokyo 101-0061, Japan