

Clinical Report

Treatment of Intrabony Periodontal Defects with Enamel Matrix Derivative in Private Practice: A Long-term Retrospective Study

Atsushi Saito^{*,**}, Yoshie Nanbu^{**}, Tomoko Nagahata^{**}
and Satoru Yamada^{***}

* *Division of Conservative Dentistry,
Department of Clinical Oral Health Science, Tokyo Dental College,
2-9-18 Misaki-cho, Chiyoda-ku, Tokyo 101-0061, Japan*

** *Saito Dental Office,
2-11-1 Itsutsubashi, Aoba-ku, Sendai 980-0022, Japan*

*** *Department of Periodontology, Tokyo Dental College,
1-2-2 Masago, Mihama-ku, Chiba 261-8502, Japan*

Received 7 March, 2008/Accepted for publication 18 April, 2008

Abstract

The present study describes treatment of intrabony periodontal defects with enamel matrix derivative (EMD) in private practice. Ten patients with clinical diagnosis of chronic periodontitis were subjected to data analysis. A total of 18 teeth with various osseous defects received regenerative therapy with EMD, and were followed for a minimum of 2 years. Treatment of the intrabony defects with EMD led to a statistically significant improvement in the mean value of probing depth at 1-year when compared with at the baseline ($p < 0.01$). Reduction in probing depth was achieved with minimal recession of the gingival margin, and was maintained over the 2-year observation period with no significant change. Mean values of attachment gain at 1 and 2 years were of clinical significance: 3.39 ± 1.46 mm and 3.22 ± 1.40 mm, respectively. Although one tooth was extracted because of subsequent loss of attachment and bone, most teeth treated have been successfully maintained for 2 to 7 years with no significant signs of disease progression. In conclusion, EMD treatment of intrabony osseous defects yielded clinically favorable responses. The gain in clinical attachment can be longitudinally maintained in a private practice setting. Further controlled studies are needed to elucidate the clinical significance of EMD treatment.

Key words: Periodontal regeneration—Periodontal disease—
Enamel matrix derivative (EMD)—Intrabony defects—
Dental hygiene process of care

Introduction

As the use of dental implants increases, there is a tendency to underestimate the long-

term prognosis of a tooth with a compromised periodontium. This can result in premature extraction of a tooth because of the rationalization that its retention might dam-

age a future implant site, or its inclusion in a prosthesis is too risky¹⁰). Retention of patient teeth remains the utmost priority for periodontists in Japan especially in private general practice settings. With periodontal regenerative therapy, many teeth with unfavorable periodontal forecasts can be converted to teeth with favorable long-term prognoses.

The use of an enamel matrix derivative (EMD) has been proposed as an alternative in periodontal regeneration. EMD is obtained from porcine embryogenesis and is an amelogenin derivative¹¹). Amelogenin is known to play a role in tooth formation, particularly in the formation of acellular cement. There is significant homogeneity between porcine and human enamel proteins, because those proteins have remained essentially unchanged during evolution.^{8,9,11}). Since prospective controlled clinical trials establishing scientific evidence for the clinical efficacy of EMD are limited, the scientific base for the use of EMD in periodontal regenerative therapy has not been firmly established¹⁸). However, since its commercial launch, EMD has been widely used in clinical treatment. Periodontists in private practice should be able to provide further information regarding the efficacy of EMD treatment through long-term follow-up of treated cases.

The present study evaluated longitudinal clinical outcomes of treatment of intrabony defects with EMD in a private practice setting. The analyses of clinical data from 10 patients are presented along with an overview of a representative treatment case.

Methods

1. Subjects

The study subjects were selected from a patient population at a private practice with clinical diagnosis of generalized chronic periodontitis. Among the patients who received periodontal regenerative therapy with EMD, the following criteria were used for inclusion and data analysis in the present study: 1) no serious systemic complications or history of

allergies; 2) periodontal pockets with a probing depth (PD) of ≥ 6 mm; 3) osseous defects estimated to be as at least 4 mm deep and 2 mm wide (largest width); 4) at least 2 years of periodontal supportive therapy. A total of 10 patients (6 females and 4 males) with a mean age of 58.2 years (range; 49 to 74) were subjected to data analysis.

2. Initial periodontal therapy

After systemic and oral assessment, periodontal treatment plans were formulated. Treatment plans included dental hygiene care plans within the concept of the "dental hygiene process of care"^{13,21}) by dental hygienists. Initial therapy consisting of oral hygiene instructions, full-mouth scaling and root planning, and occlusal adjustment (if trauma from occlusion was present) was performed by dental hygienists (YN, TN) and a periodontist (AS).

3. Clinical parameters

At least 4 weeks after the initial periodontal therapy, re-evaluation was performed. The following baseline clinical parameters were recorded prior to the surgery: probing depth (PD); clinical attachment level (CAL: measured from the cemento-enamel junction to the apical depth of the periodontal probe penetration); tooth mobility (TM) and gingival margin. Patient oral hygiene status was evaluated with the plaque control record (PCR)¹⁷). Postoperative re-evaluation was performed at least 3 months after the surgery.

4. Radiographic examination

Intraoral radiographs were obtained using a film holder (CID-2, Hanshin Technical Laboratory, Nishinomiya, Japan) with a paralleling cone technique.

5. Periodontal regenerative therapy

The treatment plan, with alternatives, was presented to the patient. Informed consent to the proposed surgical intervention was obtained from the patient. If other dental pathologies or conditions were present, they were treated prior to or concurrently with the regenerative therapy.

Table 1 Case profiles at baseline (pre-operation)

Case No.	Gender	Age	Systemic Condition	Smoking	Site	PD (mm)	TM	Defect type	PCR (%)
1	F	63	Hypertension Osteoporosis	No	#15	9	2	2-wall	34
					#23	6	2	2-wall	
					#37	7	0	2-wall	
2	F	74		No	#45	10	0	2-wall	14
					#25	6	0	3-wall	
3	F	69		No	#34	7	0	3-wall	18
4	F	53		No	#46	7	0	2-wall	27
					#44	6	0	3-wall	
					#43	6	0	3-wall	
5	F	54	Duodenum ulcer	No	#27	6	0	2-wall class II	23
6	M	56		No	#43	6	0	dehiscence	32
7	M	58	Diabetes Hypertension	No	#16	8	0	2-wall	19
8	F	55		No	#35	9	1	3-wall	28
9	M	51		Yes	#35	9	0	1-wall	23
					#46	9	1	1-wall	
10	M	49		No	#12	6	1	2-wall	26
					#13	7	0	2-wall	
					#23	7	0	3-wall	

The regenerative therapy with EMD was performed by the standard procedure. Briefly, sites were surgically treated, employing a full-thickness periodontal flap (papilla preservation technique) to gain access to the root surface for scaling and root planning. Following debridement, sites were acid-etched with 36% ortho-phosphoric acid for 15 sec. Then EMD solutions (Emdogain[®] or Emdogain[®] Gel; Biora AB, Malmö, Sweden) were applied, in accordance with the instructions. No attempt was made to use bone graft or other supplementary modalities. Interrupted sutures were used, and written postoperative instructions were given to the patients. Patients received an oral antibiotic (typically 300 mg/d of cefdinir) and a non-steroidal anti-inflammatory drug (NSAID) (lornoxicam 4 mg/d) for 3 to 5 days. Patients used a mouthrinse (Listerine[®], Johnson and Johnson, Tokyo, Japan) twice daily. The sutures were removed after 10 to

14 days. After suture removal, patient plaque control with the roll brushing technique utilizing an ultra-soft toothbrush was resumed at the surgically treated sites.

6. Supportive periodontal therapy

Meticulous supragingival professional tooth cleaning was also performed weekly for the first 4 weeks postsurgery. Thereafter, patients were recalled once a month. They received supportive periodontal therapy, consisting mainly of oral hygiene instruction, scaling and subgingival plaque control.

7. Ethical considerations

Written informed consent regarding the use of data for research purposes was obtained from all patients.

8. Statistical analysis

For statistical analysis of the quantitative

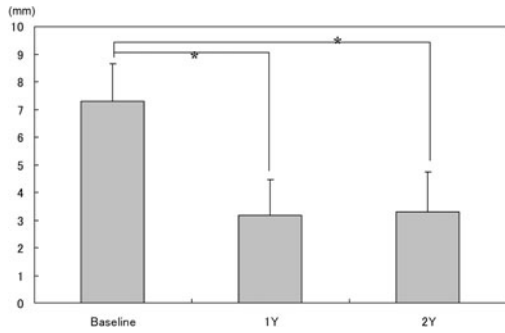


Fig. 1 Change in PD (mean ± SD). (n = 18, * p < 0.01, Wilcoxon matched pairs signed rank test)

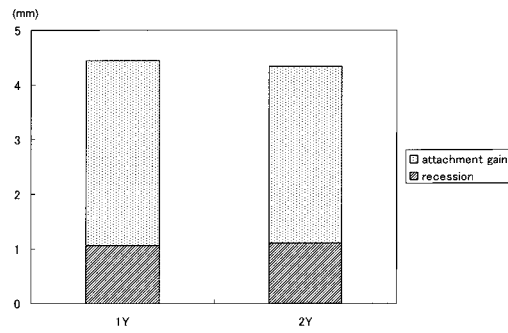


Fig. 2 Contribution of gingival recession and clinical attachment gain in reduction of probing depth achieved by EMD treatment. (n = 18)

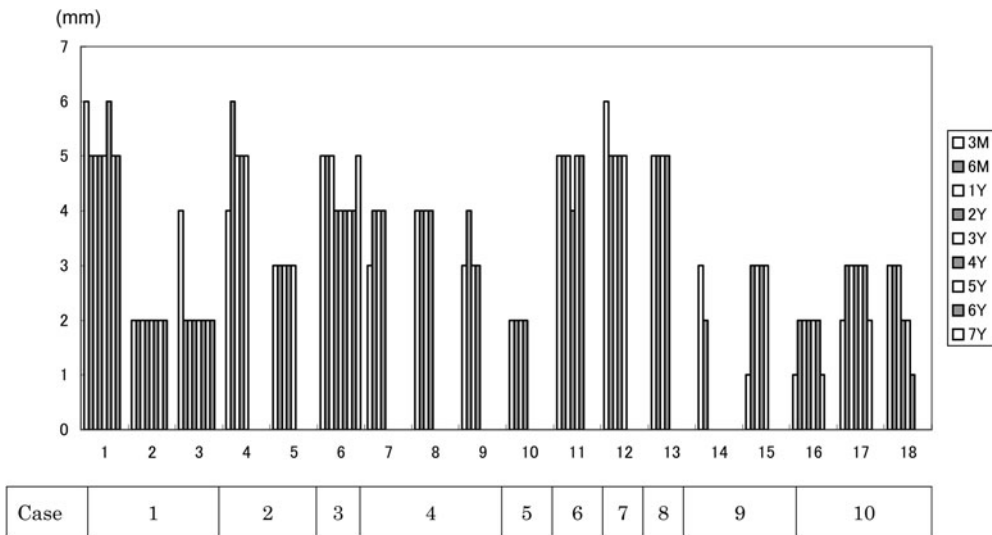


Fig. 3 Changes in clinical attachment gain at treated sites (n = 18 sites or teeth in 10 patients). Treated sites were followed up for up to 7 years postoperatively.

data, a software package (InStat version 3.05 for Windows, GraphPad Software, San Diego, USA) was used.

Results

The summary of baseline data is shown in Table 1. Three subjects had systemic diseases such as hypertension, duodenum ulcer, osteoporosis and diabetes. They were all under the care of physicians, and the disease conditions were well managed. None of the patients

showed any healing complications with the initial periodontal therapies. During the initial periodontal therapy, efforts were made to obtain optimal level of oral hygiene by patient self-care. The oral hygiene instructions aimed to reduce the scores of PCR below 20%. This goal was not always achieved, and dental hygienists implemented individualized professional oral hygiene care as necessary.

A total of 18 teeth received regenerative therapy with EMD and were followed up for at least 2 years.

Post-operative healings were uneventful

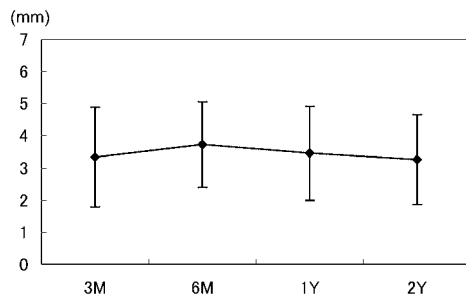


Fig. 4 Change in CAL gain (mean \pm SD). No significant difference in values was observed during 2 year period (n.s. by Kruskal-Wallis with Dunn post test).

in all subjects. Treatment of the intrabony defects with EMD led to a statistically significant improvement in mean value of PD at 1 year compared with at the baseline ($p < 0.01$) (Fig. 1). The reduction in PD was maintained during the 2-year minimum observation period with no significant change.

The reduction in PD was achieved with minimal recession of the gingival margin (Fig. 2).

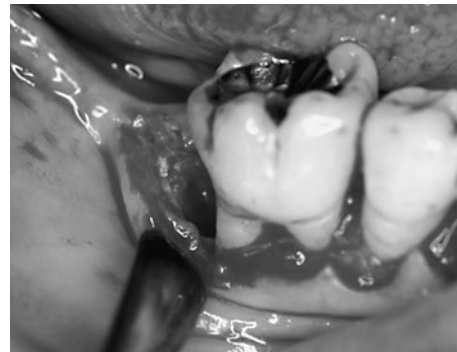Changes in CAL gain per site are shown in Fig. 3. Although one tooth was extracted because of progression of attachment and bone loss (Case no. 9), most teeth were maintained for 2 to 7 years with no significant signs of disease progression. No significant difference in mean values of CAL gain was observed during the 2-year follow-up (Fig. 4). Mean CAL gains in the recorded sites at 1 and 2 years were 3.39 ± 1.46 (range 1 to 5 mm) and 3.22 ± 1.40 (range 0 to 5 mm), respectively.

The clinical and radiographic appearances of a representative case are shown in Fig. 5.

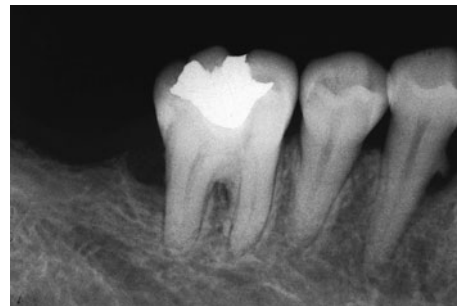No apparent adverse effects were observed as a result of repeated use of EMD in the same subject.

Discussion

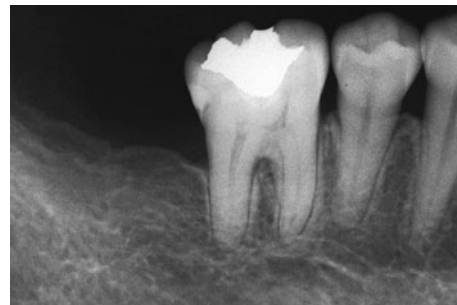The main goal of periodontal therapy is to halt the destruction process and reconstruct lost tissues. Regeneration is understood as the reconstruction of the lost tissues with the



a



b



c

Fig. 5

- a: 53-year old female (Case no. 4). During surgery with EMD for #46. Note the intrabony defect in distal aspect. CAL = 6 mm.
 b: Preoperative radiographic view showing extensive angular bony defect in distal aspect of #46.
 c: Two-year radiographic view showing resolution of the intrabony component of the defect. CAL = 2 mm.

same features and functions they had before. Studies reporting on the effectiveness of EMD in periodontal regeneration are conflicting, and its true value is still unproven.

In the present study, treatment with EMD

resulted in statistically significant ($p < 0.01$) improvement in mean PD value of treated teeth at 1 and 2 years when compared with at baseline (Fig. 1). The observed improvement in PD (approximately 4 mm) was in accordance with the results from a multi-center study of 956 cases in Japan²³.

Mean value for CAL gain 6 months after EMD treatment was 3.61 ± 1.34 mm, which was significantly greater than that observed with bioresorbable membrane therapy (2.2 ± 1.9 mm), as we have previously reported²⁴. Mean CAL gain at 1-year was 3.39 ± 1.46 mm. This result demonstrated greater improvement than was shown by Okuda *et al.*¹⁵, who reported a mean CAL gain of 1.72 ± 1.07 mm in 1 year after the EMD treatment in Japanese patients. This difference may be explained by several factors. In addition to a difference in patient populations, the mean value for baseline PD in the present study subjects (7.28 ± 1.36 mm) was approximately 1 mm deeper than that (6.33 ± 0.91 mm) reported by Okuda *et al.*¹⁵. The CAL gain after regenerative periodontal treatment has been shown to be dependent on the initial PD; that is, the deeper the initial PD, the greater the PD reduction and CAL gain^{5,16}.

The amount of gingival recession in the present study averaged -1.06 mm at 1 year and -1.11 mm at 2 years (Fig. 2). These values are slightly less than the -1.22 mm recession reported by Okuda *et al.*¹⁵. A study by Sculean *et al.*²⁰ demonstrated less recession at sites treated with EMD compared to guided tissue regeneration (GTR) treated sites. The relatively small value for gingival recession found in the present study may further support the added advantage of EMD treatment.

The Cochrane review of 10 published randomized controlled trial studies⁷ showed that 1 year after its application, EMD significantly improved PAL (probing attachment level) (1.2 mm) and PPD (probing pocket depth) reduction (0.8 mm) compared to a placebo or control. However, the high degree of heterogeneity observed among trials suggests that results have to be interpreted with great caution.

In the present study, in most cases, the gained attachment has been maintained without further significant loss. One treated tooth, however, had to be extracted at a 2-year re-evaluation because of disease progression. Careful judgment regarding a favorable or unfavorable prognosis for a tooth is important. Individual tooth prognoses are usually based on clinical evaluations, and these determinations are often intuitive appraisals¹⁰. A more precise method of delineating a quantifiable threshold for tooth removal based on periodontal status needs to be developed.

For successful periodontal regenerative therapy, "local", "behavioral" and "systemic" factors in patients should be considered^{4,12}. In consideration of local factor, the authors would like to emphasize the importance of maintenance care by dental hygienists, in addition to appropriate self-care by each patient. The greatest advantage of the small scale private practice is meticulous individualized dental hygiene care¹⁴. One of the dental hygienists in our clinic (co-author YN) is a dental hygienist certified by the Japanese Society of Periodontology. Dental hygiene care was implemented based on professional expertise in periodontics within the dental hygiene process of care. Collaborative effort between the dental hygienists and periodontist is considered to have contributed to the clinical outcomes of the present subjects.

In regenerative periodontal therapy, a clear tendency towards more favorable results among non-smokers than in smokers has been reported^{3,4}. Prior to any periodontal therapies, smokers were encouraged to quit and were told that the success rates would be lower if they continued this habit during treatment. However, instruction and persuasion do not always succeed, and those who continue to smoke often experience undesirable clinical outcomes. In the present study, the treated tooth of a smoker (case no.9 in Table 1) had to be extracted after 2 years because of further progression of attachment loss. Although evaluation of the risk of smoking is beyond the scope of the present study, the limited experience of this study supports

the alleged negative influence of smoking behavior in regenerative therapy.

Systemic risk assessment is also important. Recently, there have been reports of osteonecrosis of alveolar bone following surgical intervention in patients who receive bisphosphonate^{1,2}. Although one subject in the present study had started receiving oral bisphosphonate therapy after EMD treatment, the postoperative healing has been uneventful. Careful assessment of the systemic condition of the patient should be repeated at every maintenance appointment.

A study by Cortellini and Tonetti⁶ demonstrated a CAL gain of 5.9 ± 1.2 mm at 1 year following EMD treatment, using an evidence-based operative decision tree and microsurgery. As regenerative procedures and materials have been associated with a degree of sensitivity to the skills of the surgeon, continuous development of surgical technique with evidence-based regenerative strategy is necessary to optimize clinical outcomes.

There are limitations to the present study. Since the size of the patient sample was small, no attempts were made to differentiate location of surgical sites or type of defect in data analysis. Type of osseous defect has been shown to be important determinant in EMD treatment²². Clinical outcomes should be evaluated according to the defect type in larger scale studies. Since this was not the prospective case-controlled study, no control (flap surgery only or with placebo) data were available. A standardized reproducible method was not utilized for precise analysis of intraoral radiographs. The evaluation of subgingival microflora was not performed in the subjects of the present study, mainly due to the cost involved. A previous report by our group suggested the efficacy of local drug delivery of minocycline-HCl as an adjunctive modality in periodontal regeneration¹⁹. The effect of antimicrobial agents with EMD treatment is another area that needs to be investigated.

In conclusion, EMD treatment demonstrated long-term clinically favorable responses with intrabony osseous defects. Evaluation of the clinical efficacy of EMD treatment in compar-

son to other treatment modalities is beyond the scope of the present study. Further controlled studies are needed to elucidate the clinical significance of EMD treatment.

Acknowledgements

The authors wish to acknowledge Noboru Saito, DDS, PhD, Saito Dental Office, for his dedication to patient care and work in clinical dentistry.

We would like to thank Adjunct Professor Jeremy Williams, Tokyo Dental College, for his assistance with preparation of this manuscript.

References

- 1) American Association of Oral and Maxillofacial Surgeons (2007) American Association of Oral and Maxillofacial Surgeons position paper on bisphosphonate-related osteonecrosis of the jaws. *J Oral Maxillofac Surg* 65:369–376.
- 2) American Dental Association Council of Scientific Affairs (2006) Dental management of patients receiving oral bisphosphonate therapy: expert panel recommendations. *J Am Dent Assoc* 137:1144–1150 (<http://jada.ada.org>, Accessed Jan. 10, 2008.)
- 3) Becker W, Becker BE (1999) Periodontal regeneration; A contemporary re-evaluation. *Periodontol* 2000 19:104–114.
- 4) Cortellini P, Bowers GM (1995) Periodontal regeneration of intrabony defects: an evidence-based treatment approach. *Int J Periodontics Restorative Dent* 15:128–145.
- 5) Cortellini P, Pini Prato G, Tonetti MS (1993) Periodontal regeneration of human intrabony defects. I. Clinical measures. *J Periodontol* 64:254–260.
- 6) Cortellini P, Tonetti MS (2005) Clinical performance of a regenerative strategy for intrabony defects: scientific evidence and clinical experience. *J Periodontol* 76:341–350.
- 7) Eposito M, Grusovin MG, Coulthard P, Worthington HV (2008) Enamel matrix derivative (Emdogain[®]) for periodontal tissue regeneration in intrabony defects. *The Cochrane Library* [online serial]. Issue 1:1–34. (Accessed March 3, 2008.)
- 8) Gestrelus S, Andersson C, Johansson AC, Person E, Brodin A, Rydhag L, Hammarström

- L (1997) Formation of enamel matrix derivative for surface coating. Kinetics and cell colonization. *J Clin Periodontol* 24:678–684.
- 9) Gestrelus S, Andersson C, Lindstrom D, Hammarström L, Somerman M (1997) In vitro studies on periodontal ligament cells and enamel matrix derivative. *J Clin Periodontol* 24:685–692.
 - 10) Greenstein G, Greenstein B, Cavallaro J (2007) Prerequisite for treatment planning implant dentistry: periodontal prognostication of compromised teeth. *Compendium* 28:436–447.
 - 11) Hammarström L (1997) Enamel matrix, cementum development and regeneration. *J Clin Periodontol* 24:658–668.
 - 12) Machtei EE, Grossi SG, Dunford R, Zambon JJ, Genco RJ (1996) Long-term stability of Class II furcation defects treated with barrier membranes. *J Periodontol* 67:523–527.
 - 13) Mueller-Joseph L, Petersen M (1995) Dental hygiene process: diagnosis and care planning, Delmer Publishers, Albany.
 - 14) Nanbu S, Saito A, Yamada S (2003) The maintenance following surgical periodontal therapy. *J Jpn Soc Periodontol* 45:156. (in Japanese)
 - 15) Okuda K, Momose M, Miyazaki A, Murata M, Yokoyama S, Yonezawa Y, Wolff LF, Yoshie H (2000) Enamel matrix derivative in the treatment of human intrabony osseous defects. *J Periodontol* 71:1821–1828.
 - 16) Okuda K, Murata M, Sugimoto M, Nomura T, Wu C-H, Hara K (1998) Comparison of guided tissue regeneration procedure to conventional flap surgery in treating intrabony and Class II furcation defects, and analysis of factors affecting the prognosis following GTR. *J Jpn Soc Periodontol* 40:358–370. (in Japanese)
 - 17) O'Leary TJ, Drake RB, Naylor JE (1972) The plaque control record. *J Periodontol* 43:38.
 - 18) Rösing CK, Aass AM, Mavropoulos A, Gjermo P (2005) Clinical and radiographic effects of enamel matrix derivative in the treatment of intrabony periodontal defects: a 12-month longitudinal placebo-controlled clinical trial in adult periodontitis patients. *J Periodontol* 76:129–133.
 - 19) Saito A, Hosaka Y, Nakagawa T, Seida K, Yamada S, Okuda K (1994) Locally delivered minocycline and guided tissue regeneration to treat post-juvenile periodontitis. A case report. *J Periodontol* 65:835–839.
 - 20) Sculean A, Donos N, Blaes A, Lauermann M, Reich E, Brex M (1999) Comparison of enamel matrix proteins and bioabsorbable membranes in the treatment of intrabony periodontal defects. A split-mouth study. *J Periodontol* 70:255–262.
 - 21) Shimono M, Sato Y, Saito A, Hosaka M, Cathcart G (2007) Dental hygiene process of care, Ishiyaku Publishers, Tokyo. (in Japanese)
 - 22) Stuart F, Jeffrey L, Robert H, Rruce D (2001) The use of enamel matrix derivative in the treatment of periodontal osseous defects. A clinical decision tree based on biologic principles of regeneration. *Int J Periodontics Restorative Dent* 21:437–449.
 - 23) Sueda T, Hoshino J, Yamamura N (2004) Survey on results of Emdogain® use in multiple dental clinics. *J Jpn Soc Periodontol* 46: 152–160. (in Japanese)
 - 24) Yamanouchi K, Nakagawa T, Seida K, Saito A, Yamada S, Hiwatashi K, Setoguchi T, Chuman M, Sueda T (1994) Clinical study on the effect of absorbable membrane applied to guided tissue regeneration technique. *J Jpn Soc Periodontol* 36:884–894. (in Japanese)

Reprint requests to:

Dr. Atsushi Saito
 Division of Conservative Dentistry,
 Department of Clinical Oral
 Health Science,
 Tokyo Dental College,
 2-9-18 Misaki-cho, Chiyoda-ku,
 Tokyo 101-0061, Japan
 E-mail: atsaito@tdc.ac.jp