

Case Report

Patient in whom Surgery was Selected to Improve Mandible Position after Changing Doctors

Haruyo Miyazaki, Kenji Sueishi*, Masayuki Takano and Takashi Kakizawa

*Division of Orthodontics, Department of Clinical Oral Health Science,
Tokyo Dental College,*

2-9-18 Misakicho, Chiyoda-ku, Tokyo 101-0061, Japan

**Department of Orthodontics, Tokyo Dental College,*

1-2-2 Masago, Mihama-ku, Chiba 261-8502, Japan

Received 4 April, 2008/Accepted for publication 8 October, 2008

Abstract

A patient who visited our department after job relocation was reexamined, and a marked discrepancy was found in mandibular position between centric occlusion and centric relation. Although the patient was originally scheduled to undergo orthodontic treatment only, the results of comprehensive tests indicated that surgery would be needed to resolve this discrepancy. Surgery was performed with the patient's consent, yielding favorable results. Although the entire orthodontic treatment lasted 3 years and 11 months, including treatment prior to transfer, it was clear that long-term use of intermaxillary elastics would not have corrected the discrepancy and that surgery was the right decision.

Key words: Orthodontic surgery—Centric relation—Centric occlusion—Condylar position indicator (CPI)—Transfer case

Introduction

Many orthodontic patients have to change doctors when they relocate. When this occurs, the new doctors reexamine those patients, and new therapeutic options are sometimes selected. Here, a patient who visited our department after job relocation was reexamined, and a marked discrepancy was found in mandibular position between centric occlusion and centric relation. Although the patient was originally scheduled to undergo orthodontic treatment only, she eventually underwent surgery, and favorable results were obtained.

Case

Patient: A woman who was 28 years and 11 months of age at the time of transfer.

Chief complaint: continuation of orthodontic treatment

Family history: no relevant information

Past and current medical history: At the age of 26 years and 9 months, the patient began receiving orthodontic treatment after the upper left and right first premolars, lower right second premolar, and lower left first premolar were extracted due to crowding. Figures 1 and 2 show the medical records

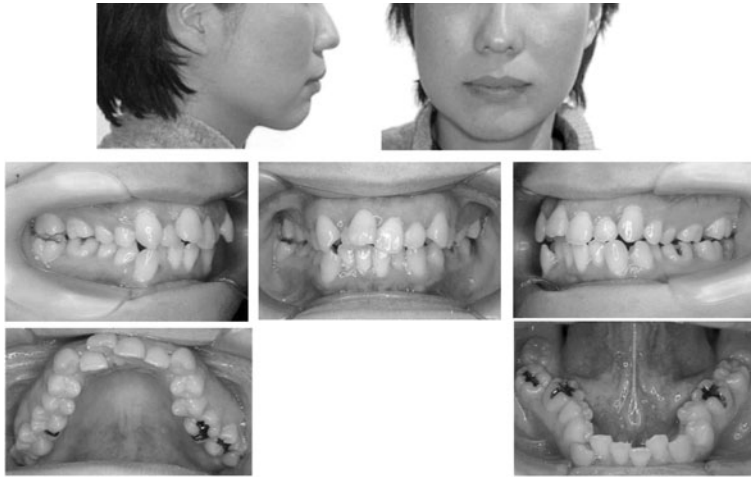


Fig. 1 Facial and intraoral photographs at pre-treatment

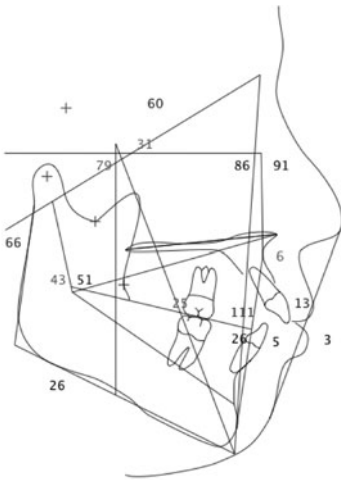


Fig. 2 Cephalometric tracing at pre-treatment

brought in by the patient at the start of orthodontic treatment. The facial profile showed that the upper and lower lips protruded, and the frontal view showed that the right mandibular angle protruded laterally when compared to the left side. The mid line of the upper and lower anterior teeth mostly matched, but the upper and lower dental arches were narrow and crowding was observed. Lingual crossbite was noted between the upper right second molar and lower second molar due to the latter being in the buccal position. Malocclusion was Angle class II on the right side and Angle

class I on the left side; hence extraction of the lower second premolar was selected to correct class II relation on the right side. A lateral cephalogram showed no skeletal abnormality, but the upper anterior teeth inclined labially and overjet was marked. No frontal cephalogram was taken.

Status at time of transfer: Before continuing with orthodontic treatment, data were collected to ascertain the patient's current status (Fig. 3, 4, 5). The referral letter stated that all gaps were closed to achieve ideal arches, and intermaxillary elastics were used to adjust the mid line of the upper and lower dentitions. Although there appeared to be no abnormality in centric occlusion, the mandible had retracted further than normal in centric relation so that full occlusion was not, in fact, achieved. To record this, intraoral photographs were taken of centric relation and centric occlusion, and a cephalogram was taken of centric relation. The patient's bite in centric relation was checked using a metal plate and pattern resin, and the resulting model was mounted using a Panadent articulator (Fig. 6). The patient's bite in centric occlusion was taken using silicone. CO-CR discrepancy was recorded using a Condylar position indicator (CPI), which is part of the Panadent articulator system.

A frontal facial photograph revealed man-

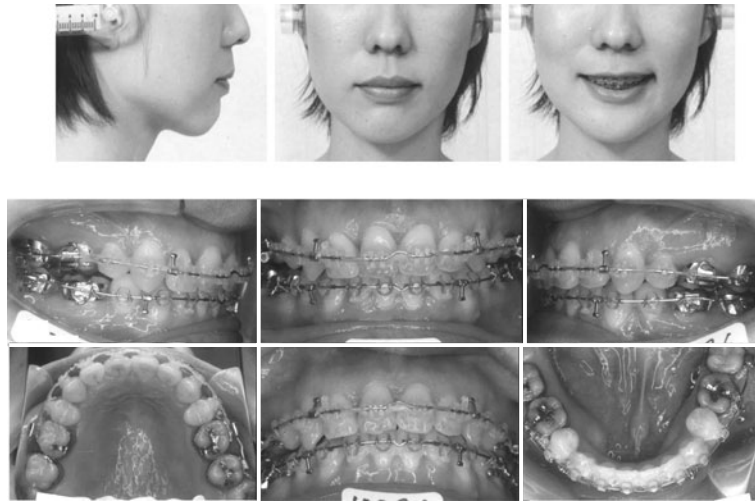

Fig. 3 Facial and intraoral photographs of centric occlusion at under-treatment

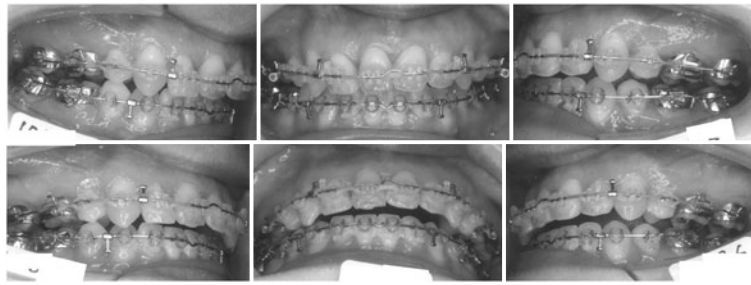

Fig. 4 Intraoral photographs of centric relation at under-treatment

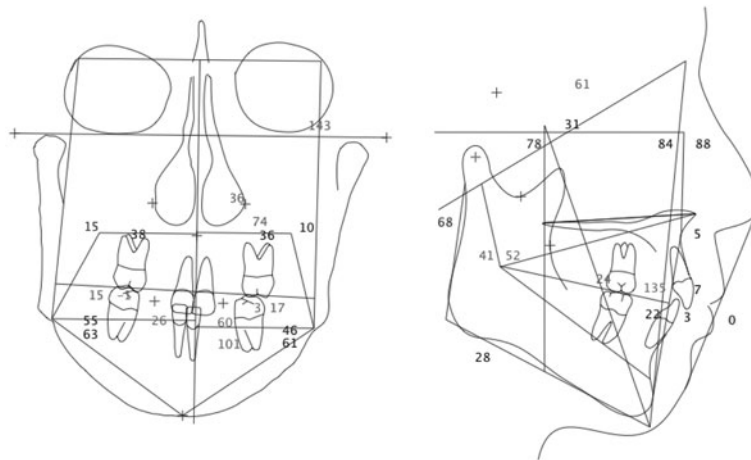


Fig. 5 Cephalometric tracing of centric relation at under-treatment

dibular asymmetry, with retraction of the upper and lower lips. No major problem was evident in her profile (Fig. 3).

Intraoral photographs of centric occlusion (Fig. 3) revealed that overjet was 2.0 mm and overbite was 1.0 mm. The mid line of the upper and lower anterior teeth matched, and intercuspид occlusion was mostly achieved. However, in centric relation (Fig. 4), the mandible was displaced rightward and posteriorly. The right side exhibited severe class II lingual crossbite, while the left side demonstrated

slight class II buccal crossbite.

A frontal cephalogram of centric relation showed that the mandible was displaced to the right, and consequently, the lower anterior teeth were displaced to the right in relation to the upper anterior teeth (Fig. 5). When a lateral cephalogram was overlapped with a cephalogram of centric occlusion at the initiation of treatment, the labiolingual inclina-

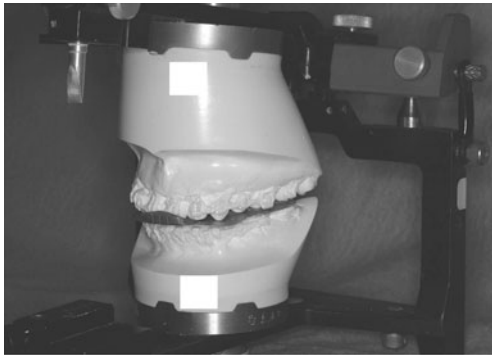


Fig. 6 CR mounting using Panadent articulator

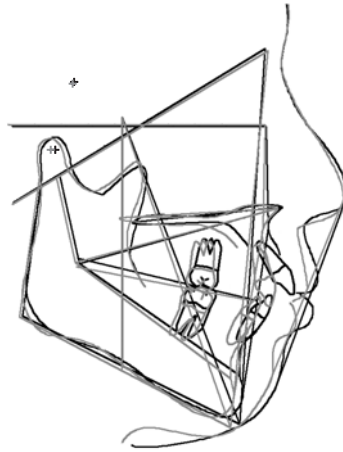


Fig. 7 Superimposition of pre-treatment and under-treatment cephalometric tracing
Black: pre-treatment, Gray: under-treatment.

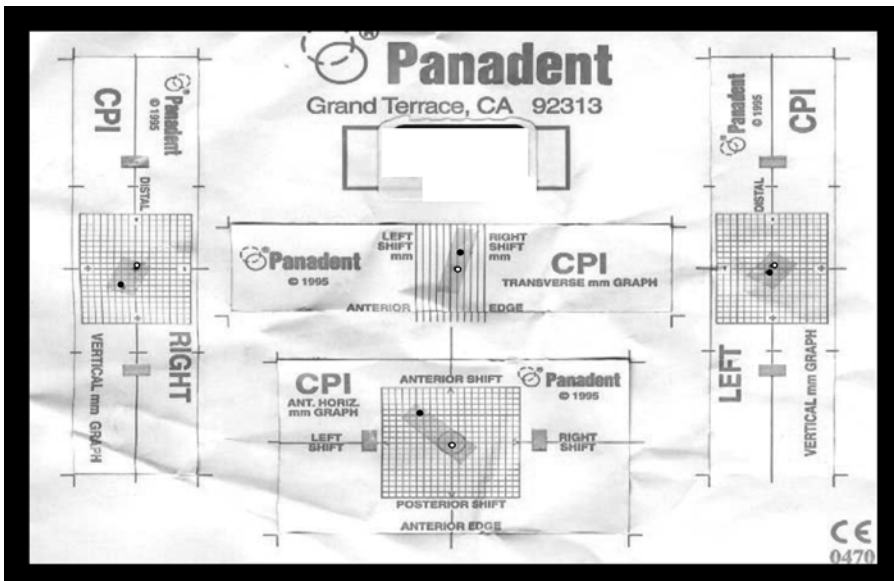


Fig. 8 Condylar position indicator at under-treatment
○: Centric relation, ●: Centric occlusion.

tion of the tooth axes had improved favorably, but slight mandibular retraction was noted (Fig. 7).

CPI showed that the mandible moved from centric relation to centric occlusion, shifting in the left anterior direction, causing the right condylar head to shift 3mm anteriorly and 2mm inferiorly (Fig. 8). Pantomography of the TMJ revealed that the right condylar head was smaller than the left, and was dislocated

from the glenoid cavity in centric occlusion (Fig. 9). Although mandibular position was a little unstable, she had only right side clicking of the TMJ. She had no pain in the TMJ, and no disorder of mandibular movement.

Diagnosis and Treatment Objective

After two years of orthodontic treatment,

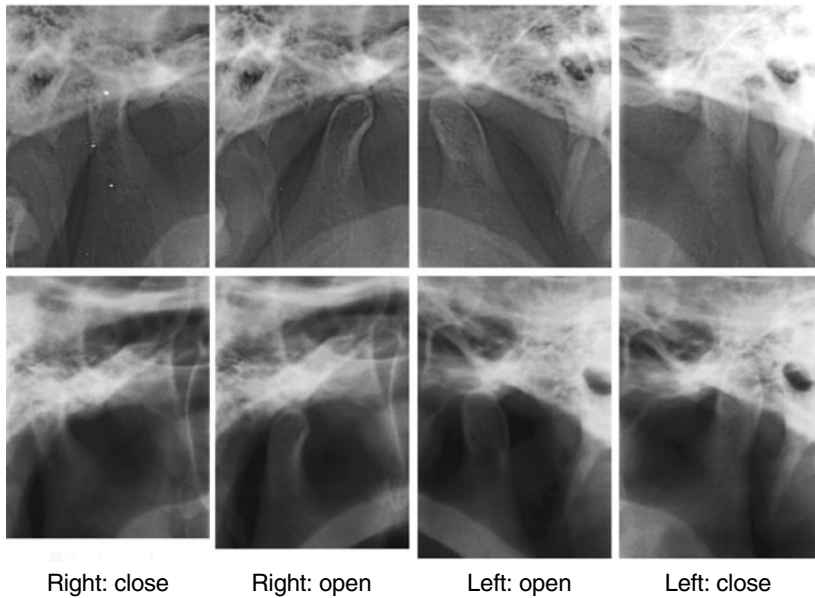


Fig. 9 Pantomography of the TMJ
Upper: under-treatment, Lower: post-treatment.

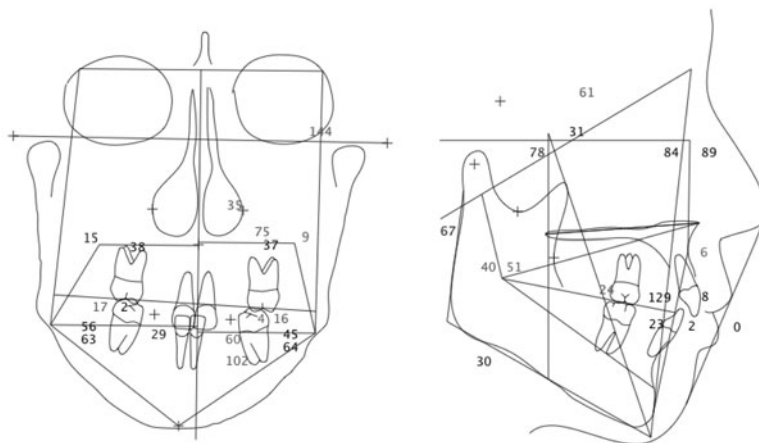


Fig. 10 Cephalometric tracing of centric relation at before-surgery

the patient had ideal arches, but reexamination indicated that mandibular position discrepancy could not be corrected by orthodontic treatment alone. When this was explained to the patient, she agreed to undergo surgical orthodontic treatment. The treatment plan was determined as follows:

- Pre-surgical teeth alignment with edgewise appliance.
- Bilateral sagittal split ramus osteotomy to correct the posterior and lateral shift of the mandible.
- Post-surgical orthodontic treatment with edge-

- wise appliance to achieve proper occlusion.
- Retention using wrap-around type retainers.

Treatment Progress and Results

Figure 10 shows the cephalometric tracing after 5 months of preoperative orthodontic treatment. In such cases, it is necessary to correct the positioning of proximal segments, including the condylar heads, in order to maintain good function with precise seating of the bilateral temporomandibular joint. There-

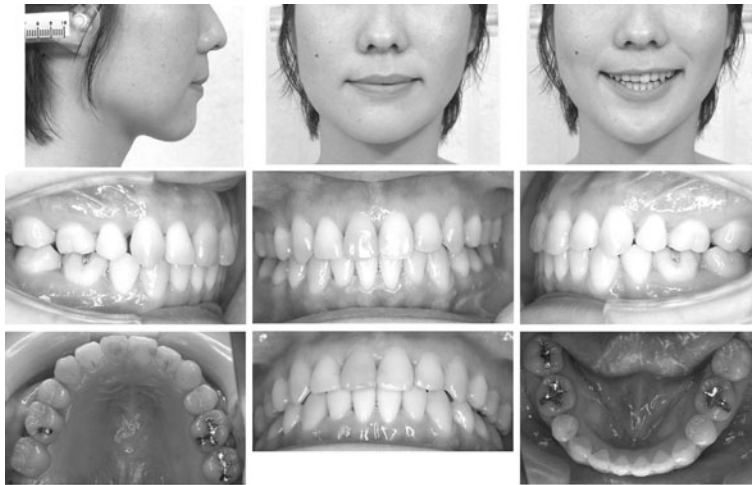

Fig. 11 Facial and intraoral photographs of centric relation at post-treatment

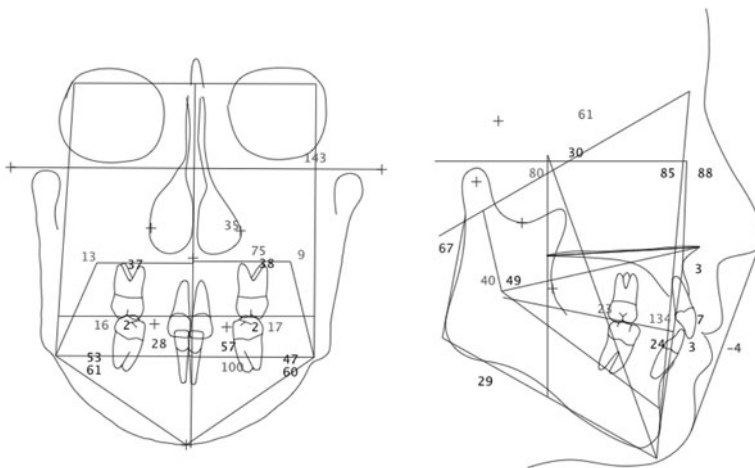


Fig. 12 Cephalometric tracing of centric relation at post-treatment

fore, before bone splitting, we measured the distance between the anterior border of the mandibular ramus and the maxillary canine with a bite plate inserted in the preoperative seating position of the TMJ (centric relation). After bilateral sagittal split ramus osteotomy, we positioned the segments 3 mm anteriorly and 2 mm leftward, and fixed the proximal and distal bone segments with titanium plates. Operating time was 1 hr 28 min, and total hem-

orrhage volume was 142 ml. Inter-maxillary fixation was performed between the upper and lower arch wires for 14 days. When the inter-maxillary fixation wire was removed, mandibular position was stable.

The patient underwent postoperative orthodontic treatment for about one year. She was treated at our department for 1 year and 5 months, and the entire treatment lasted 3 years and 11 months.

Figure 11 shows the patient's face and intra-oral photographs at post-orthodontic treatment. Because surgery moved the mandible anteriorly and leftward, the patient's profile showed an improvement. In the oral cavity, intercuspation was obtained, mid lines matched, and overjet and overbite were appropriate. Figure 12 shows the cephalometric tracing taken at post-treatment. The rightward mandibular position discrepancy had improved, and the mid lines matched. Superimposition of a preoperative lateral cephalogram on a post-treatment lateral cephalogram revealed that the mandible had moved forward (Fig. 13).

As to CPI at post-treatment, centric relation and centric occlusion mostly matched (Fig. 14). Pantomography of the TMJ showed that,

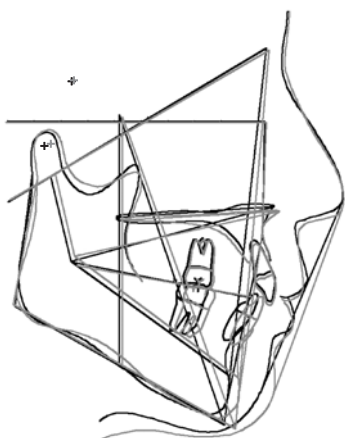


Fig. 13 Superimposition of before-surgery and post-treatment cephalometric tracing
Black: before-surgery, Gray: post-treatment.

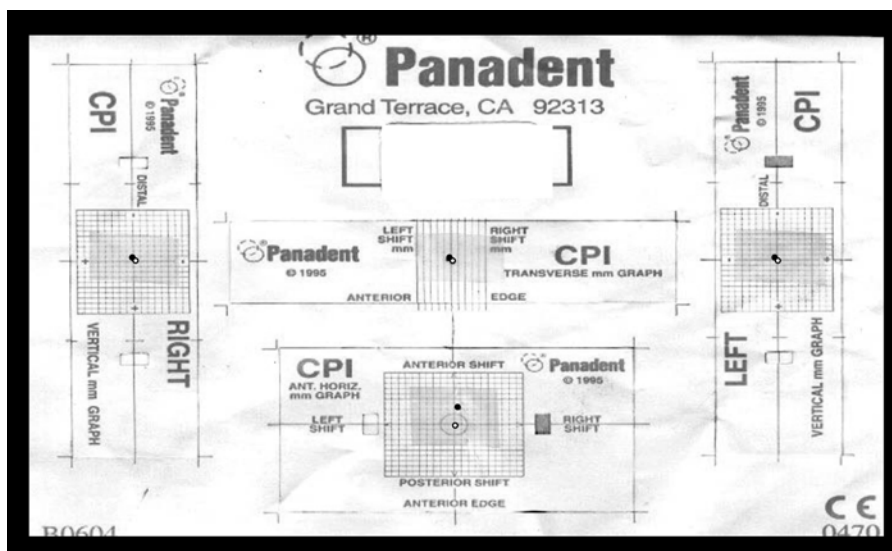


Fig. 14 Condylar position indicator at post-treatment
○: Centric relation, ●: Centric occlusion.

before treatment, the right condylar head was slightly narrower and shorter than the left condylar head and, in relation to the glenoid cavity, the condylar head lay in the antero-inferior direction. However, after treatment, while no morphological changes were seen, both the left and right condylar heads were in the proper location within the glenoid cavity (Fig. 9).

Discussion

Orthodontic treatment is not successful if there is a discrepancy in mandibular position between centric relation and centric occlusion, even when upper and lower teeth match in centric occlusion¹⁾. For orthodontic treatment and diagnosis, paralleling models are generally used. However, in order to record information on mandibular position discrepancy that cannot be ascertained using paralleling models, it is necessary to mount models in centric relation¹⁻⁴⁾. Centric relation is defined as when the condylar head is in close relation with the articular disk and eminence, with the condylar head sitting in the highest position of the temporomandibular fossa, and no deviation to the left or right in the coronal plane⁴⁾.

In the present patient who transferred from another clinic, centric relation was not recorded at the initial visit and no frontal cephalogram was taken, resulting in under-estimation of the aforementioned discrepancy at the temporomandibular joint. When the patient first visited our department, the model was mounted in centric relation using an articulator, CPI analysis was performed, a

frontal cephalogram was taken, and pantomography of the TMJ was performed. The comprehensive diagnosis based on various records showed that surgery would be needed to resolve the mandibular position discrepancy, and surgery was performed with the patient's consent.

Although the entire orthodontic treatment lasted 3 years and 11 months including treatment time prior to transfer, it was clear that long-term use of intermaxillary elastics could not have corrected the discrepancy and that surgery was the right decision.

References

- 1) Motegi E, Koga M, Yatabe K, Sebata M (1988) Color atlas straight wire method. *Shikwa Gakuho* 88:565-567. (in Japanese)
- 2) Roth RH (1981) Functional occlusion for the orthodontist. *J Clin Orthod* 15:32-40, 44-51.
- 3) Roth RH (1985) Treatment mechanics for the straight wire appliance; Orthodontics current principles and techniques, Graber TM, Swain BF, 1st ed., pp.665-671, Mosby, Philadelphia.
- 4) Williamson EH (1985) Occlusal concepts in orthodontic diagnosis and treatment; *New vistas in orthodontics*, Johnston JE ed., pp.122-147, Lea & Febiger, Philadelphia.

Reprint requests to:

Dr. Haruyo Miyazaki
 Division of Orthodontics,
 Department of Clinical Oral
 Health Science,
 Tokyo Dental College,
 2-9-18 Misakicho, Chiyoda-ku,
 Tokyo 101-0061, Japan
 E-mail: miyazaki@tdc.ac.jp