

## Clinical Report

# Survey of Accidental Ingestion and Aspiration at Tokyo Dental College Chiba Hospital

**Ryuichi Hisanaga<sup>1,2)</sup>, Keiko Hagita<sup>1,3)</sup>, Kunihiko Nojima<sup>1,4)</sup>, Akira Katakura<sup>5)</sup>, Kazuki Morinaga<sup>1,6)</sup>, Tatsuya Ichinohe<sup>1,7)</sup>, Reiko Konomi<sup>1,8)</sup>, Toshiyuki Takahashi<sup>1,9)</sup>, Nobuo Takano<sup>1,10)</sup> and Takashi Inoue<sup>1,11)</sup>**

- <sup>1)</sup> *Division of Medical Risk Management, Tokyo Dental College, 1-2-2 Masago, Mihama-ku, Chiba 261-8502, Japan*
- <sup>2)</sup> *Department of Crown and Bridge Prosthodontics, Tokyo Dental College, 1-2-2 Masago, Mihama-ku, Chiba 261-8502, Japan*
- <sup>3)</sup> *Division of Clinical Laboratory, Tokyo Dental College, 1-2-2 Masago, Mihama-ku, Chiba 261-8502, Japan*
- <sup>4)</sup> *Department of Orthodontics, Tokyo Dental College, 1-2-2 Masago, Mihama-ku, Chiba 261-8502, Japan*
- <sup>5)</sup> *Division of Oral and Maxillofacial Surgery, Department of Oral Health Clinical Science, Tokyo Dental College, 2-9-18 Misaki-cho, Chiyoda-ku, Tokyo 101-0061, Japan*
- <sup>6)</sup> *Department of Endodontics and Clinical Cariology, Tokyo Dental College, 1-2-2 Masago, Mihama-ku, Chiba 261-8502, Japan*
- <sup>7)</sup> *Department of Anesthesiology, Tokyo Dental College, 1-2-2 Masago, Mihama-ku, Chiba 261-8502, Japan*
- <sup>8)</sup> *Division of Nursing, Tokyo Dental College, 1-2-2 Masago, Mihama-ku, Chiba 261-8502, Japan*
- <sup>9)</sup> *Office of General Dentistry, Tokyo Dental College, 1-2-2 Masago, Mihama-ku, Chiba 261-8502, Japan*
- <sup>10)</sup> *Department of Oral and Maxillofacial Surgery, Tokyo Dental College, 1-2-2 Masago, Mihama-ku, Chiba 261-8502, Japan*
- <sup>11)</sup> *Department of Clinical Pathophysiology, Tokyo Dental College, 1-2-2 Masago, Mihama-ku, Chiba 261-8502, Japan*

Received 25 December, 2009/Accepted for publication 15 February, 2010

## Abstract

The occurrence of accidental ingestion/aspiration and preventive measures were investigated at Tokyo Dental College Chiba Hospital. In addition, the characteristics of accidents at our hospital were analyzed by surveying the awareness of accidental ingestion/aspiration to utilize the data for prevention. Accidental ingestion accounted for about 30% of accidents that occurred at our hospital in fiscal 2008, but all ingested items were naturally excreted, and no accidental aspiration occurred. Accidental ingestion most frequently occurred when dental restorations were removed. Inlays and crowns were most frequently ingested, and dentists with 5 to less than 10 years of clinical experience tended to be involved in these accidents. According to the results of the questionnaire,

removal of restorations was perceived as the treatment least likely to cause accidental ingestion/aspiration. Moreover, dentists who always took preventive measures against accidental ingestion/aspiration accounted for only 40% or less on average. To avoid accidental ingestion/aspiration, repeated courses and individual instruction for repeaters and the establishment of a surveillance system along with manuals to manage the violation should be emphasized.

**Key words:** Accidental ingestion—Accidental aspiration—  
Medical risk management—Tokyo Dental College Chiba Hospital

## Introduction

Tokyo Dental College Chiba Hospital established the Medical Safety Management Committee and Risk Management Subcommittee in 2000 to prevent medical accidents and take appropriate action in response to them. A medical safety control room was established in 2004, which performs surveys, the collection of information, and analysis concerning medical safety, playing the role of a control center to ensure patients' safety. The control room also prepares manuals on prevention and countermeasures and periodically holds medical safety training classes to strengthen and enrich the safety medical care system. Manuals based on medical safety guidelines have been prepared, and awareness of the problems among workers has gradually been realized.

However, the occurrence of accidents has not been completely prevented. Action in response to accidental ingestion was carried out smoothly, but it still accounts for a large proportion of the annual number of accidents. The ingestion of foreign bodies may induce symptoms of digestive organ injury, and aspiration may cause severe disorders, such as respiratory disorder and pneumonia<sup>2-8,10,11,13,15-19,21-24</sup>. The prevention of accidental ingestion/aspiration may be an urgent task in the dental care field.

In this study, to collect information necessary to prevent ingestion/aspiration accidents, we investigated the occurrence of ingestion/aspiration accidents and preventive measures taken, and analyzed the characteristics of ingestion/aspiration accidents that occurred

at Tokyo Dental College Chiba Hospital by surveying the perception of ingestion/aspiration.

## Methods

Incidents of accidental ingestion/aspiration were investigated based on accidents reported to the Medical Safety Control Room of Tokyo Dental College Chiba Hospital between April 2008 and March 2009. This facility employed 611 workers, including 433 dentists at the time. Accident rate, date of occurrence, age and sex of patient, type, site, conditions of occurrence, course after occurrence, length of clinical experience and occupation of dentists involved were investigated. The average number of patients visiting this hospital, which has 208 dental chairs and 40 beds, is 933.1 people per day.

Length of clinical experience, preventive measures and treatments considered likely to cause accidents were surveyed in 145 dentists by a questionnaire administered at a central location. To survey the length of clinical experience and preventive measures, the pre-code choice method was employed. The obtained data from the questionnaire was divided into five groups based on length of clinical experience because of the equivalent distribution of data in each group for analysis: the dentists chose "less than 1 year, 1 to less than 3 years (1-3), 3-5, 5-10, and 10 years or longer" and "always, mostly, sometimes, and none". For the survey of treatments assumed by dentists to be likely to cause accidental ingestion/aspiration, the free answer method was employed. For summation, the grand total was adopted.

Table 1 Items accidentally ingested

Items accidentally ingested	Number of accidents
Crown	4
Inlay	3
Bracket tube	1
Tooth	1
Transfer coping	1
Tip of broken skaler	1

Table 2 Site of accidental ingestion

Site	Number of accidents
Upper right molar region	3
Lower right molar region	3
Upper right premolar region	1
Lower right premolar region	1
Upper left premolar region	1
Lower left premolar region	1
Upper right frontal tooth region	1

## Results

### 1. Incidences of accidental ingestion and aspiration

Thirty-seven accidents occurred during the survey period, and 11 were accidental ingestions (29.7%). No accidental aspiration occurred. The rate of accidental ingestion in the cumulative number of patients who visited our hospital during the survey period was 0.0041%.

### 2. Date of occurrence of accidental ingestion (Month, Day, Time)

Two cases occurred in July and November and 1 case in January, February, April, May, June, September, and October. Three cases occurred on a Wednesday and a Friday, 2 cases on a Thursday and a Saturday, and 1 case on a Tuesday. Five cases occurred in the morning and 6 cases during the afternoon.

### 3. Age and sex of patients

Four patients were in their thirties, 3 in their fifties, 2 in their seventies, 1 in their sixties and 1 in their teens. Six were men and 5 were women.

### 4. Type of accidentally ingested item

Crowns were the most frequently ingested (4 cases), followed by inlays (3 cases, Table 1).

### 5. Site of accidental ingestion

Accidents most frequently occurred involving the upper and lower right molar regions (3 cases each, Table 2).

Five and 4 cases occurred in the upper and lower jaws, respectively, and 2 and 9 cases

Table 3 Condition at time of ingestion

Condition	Number of accidents
Removal of inlay/crown	3
Attachment of inlay/crown	2
Tooth extraction	2
Removal of orthodontic appliance	1
Impression-taking of implant	1
Scaling	1
Temporary cementation of prosthesis	1

on the left and right sides, respectively. By tooth type, 6, 4, and 1 case occurred in the molar, premolar, and frontal tooth regions, respectively.

### 6. Conditions of accidental ingestion

Accidents most frequently occurred when inlays and crowns were removed (3 cases), followed by the attachment of inlays and crowns and tooth extraction (2 cases each, Table 3).

### 7. Course after accidental ingestion

All 11 patients underwent thoracoabdominal X-ray radiography following the regulations of our hospital, and all ingested items were present in the stomach and intestine. Excretion was confirmed later by secondary thoracoabdominal X-ray radiography in 10 and directly in the feces in one.

### 8. Length of clinical experience of involved dentists

Dentists with 5 to less than 10 years of experience were most frequently involved (5 cases), followed by those with 1–3 and 3–5 years (2

Table 4 Length of clinical experience of dentist

Years	Number of accidents
5–10 years	5
1–3 years	2
3–5 years	2
Less than 1 year	1
10 years or longer	1

Table 5 Occupation of dentist

Occupation	Number of accidents
Resident	4
Student of clinical specialist course	2
Assistant professor	2
Dentist in training	1
Graduate student	1
Lecturer	1

Table 6 Execution of accidental ingestion/aspiration-preventive measures by clinical experience

	Always	Mostly	Sometimes	None
Less than 1 year	31.4	60.0	8.6	0.0
1–3 years	17.1	58.5	24.4	0.0
3–5 years	23.8	61.9	14.3	0.0
5–10 years	38.9	61.1	0.0	0.0
10 years or longer	39.3	57.1	0.0	3.6

(%)

cases each, Table 4).

### 9. Occupations of involved dentists

Residents were the most frequently involved (4 cases), followed by students of clinical specialist courses and assistant professors (2 cases each, Table 5).

### 10. Accidental ingestion/aspiration-preventive measures by length of clinical experience

Dentists who “always” took preventive measures accounted for 31.4% of dentists with less than one year of clinical experience, and it decreased to 17.1% in those with 1–3 years of experience, but then increased to 23.8, 38.9, and 39.3% in those with 3–5, 5–10, and 10 or more years of experience, respectively. Dentists who chose “mostly” accounted for 60.0, 58.5, 61.9, 61.1, and 57.1% in those with less than 1, 1–3, 3–5, 5–10, and 10 or more years of experience, respectively (Table 6), showing that about 60% took preventive measures against accidental ingestion/aspiration in all groups, although not always.

### 11. Treatments assumed to be likely to cause accidental ingestion/aspiration

The attachment of restorations/prostheses

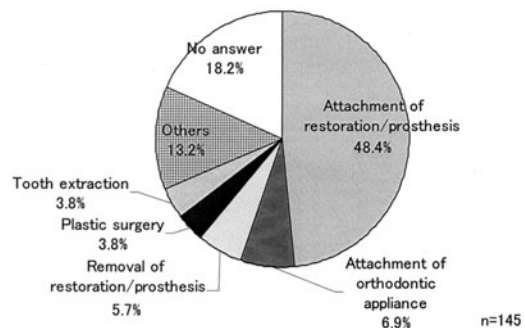


Fig. 1 Treatment assumed by dentists to be likely to cause accidental ingestion/aspiration

was considered to be likely to cause accidental ingestion/aspiration by 48.4% of the dentists, followed by the attachment of orthodontic appliances, considered by 6.9%, and the removal of restorations/prostheses, considered by 5.7% (Fig. 1).

### Discussion

The Tokyo Dental College Chiba Hospital Regulations require a thoracoabdominal X-ray when accidental ingestion/aspiration occurs,

and, accordingly, this was included in our investigation. When all cases of accidents that occurred in fiscal 2008 were investigated, accidental ingestion accounted for approximately 30%. Dental treatment is mostly performed with the patient in a supine position, which makes it more likely that materials or devices will fall into the pharynx in the event of loss of control. The rate of accidental ingestion in the cumulative number of patients who visited our hospital was 0.0041%, similar to that (0.0044%) in the dental clinic of Tokushima University Hospital (mean rate for 8 years until fiscal 2002)<sup>20</sup>. Thus, the incidence at our hospital is not particularly high, but no preventive measures such as placing gauze on the pharynx were taken in any of the 11 cases reported. To thoroughly enforce fail-safe procedures, repeated medical safety training and individual instruction in the prevention of accidental ingestion/aspiration are necessary. Moreover, it is necessary to consider the preventive measures required by analyzing the incidence of reported accidents and near misses. The attachment of knobs when passing dental floss through crowns was initiated as a new preventive measure in fiscal 2009.

There was no tendency toward any particular time of occurrence, suggesting that such accidents could occur at any time. No correlation was observed between age and sex and incidence of ingestion/aspiration.

Inlays and crowns accounted for 63.6% of all ingested items, and these ingestion accidents occurred under various conditions, such as attachment, removal, and temporary cementation. Sufficient attention should be paid whenever handling inlays and crowns. There was no difference in the frequency of ingestion between prostheses of the upper and lower teeth, but those for the right side and molar region accounted for 81.8 and 90.0%, respectively. The incidences of ingesting prostheses of the upper and lower right molar regions were the highest, with 3 cases each, accounting for 54.5% of all cases. The right side of the buccal mucosa is frequently impaired as procedures are usually carried out from the right side of the patient. Since it

is more difficult to treat the molar region than the incisor region, further attention should be paid when treating this region. Further research is needed to clarify the relationship between the incidence of accidental ingestion/aspiration and the posture or dexterity of the clinician involved.

With accidental ingestion, accidents most frequently occurred during the removal of inlays and crowns (3 cases). However, only 5.7% of all dentists surveyed considered that the removal of restorations/prostheses was likely to cause accidental ingestion/aspiration. Moreover, only 3.8% considered that tooth extraction was likely to cause accidents, although 2 cases occurred during tooth extraction. This inconsistency between the perception and the facts is one factor in the increase in accidents occurring during removal of inlays and crowns and tooth extraction, indicating the need to raise awareness with regard to this issue. Two accidents occurred while attaching inlays and crowns. Attachment of restorations/prostheses was considered to be likely to cause accidents by 48.4%, the highest rate, indicating that ingestion/aspiration may occur during attaching inlays and crowns, even if it is carefully performed. The importance of preventive measure should be emphasized. One ingestion accident occurred during scaling due to breakage of the scaler tip, suggesting the need to be aware that medical devices used in the mouth may break, even though they are periodically inspected.

Regarding the course after accidental ingestion, natural excretion was confirmed in all 11 cases. Generally, foreign bodies accidentally ingested into the digestive tract are naturally excreted, but careful observation is necessary because peritonitis, sepsis, and foreign body granuloma formation have been reported as complications resulting from the sharp edges of foreign bodies<sup>1,12</sup>. Long-term (6 weeks) retention of a foreign body in the abdominal region, even though it was eventually naturally excreted, has also been reported<sup>14</sup>. When abdominal symptoms develop or the ingested item is not excreted for a long time, patients should be referred to a digestive organ-specialized

physician in consideration of digestive tract perforation<sup>14)</sup>. Complications of foreign body aspiration into the respiratory organs include lung abscess, lung fistulation, severe pneumonia, and sepsis, being lethal in the worst case scenario. Aspiration is generally judged based on early symptoms such as cough and wheezing, but aspiration into the bronchus is asymptomatic in many cases<sup>9)</sup>. When accidental ingestion/aspiration occurs, it is necessary for the medical doctor to immediately localize the foreign body with a thoracoabdominal X-ray, as specified in the manual of our hospital, based on which course observation or removal has to be selected. Computed tomography may be suitable to localize impression materials, resin, and cement because of their low X-ray absorption<sup>24)</sup>, but this should be decided on by a dental anesthesiologist.

Regarding execution of preventive measures based on length of clinical experience, the rate of dentists always taking measures was the highest (38.9%) in those with 5 to less than 10 years of experience, and 100% of dentists mostly performed them. However, 45.5% of dentists who caused accidental ingestion had 5–10 years of experience, accounting for a large proportion, compared to those with less than 5 years and 10 or more years of experience (9.1–18.2%). Dentists with 5–10 years of experience may have not been able to perform normal preventive measures because they may have a limited time for individual dental treatment as the number of patients they are in charge of increases, or they may have started treating patients with disabilities and various past medical histories that they are not used to. In fact, no preventive measures were taken in all 5 cases including 3 patients with mental retardation, partial paralysis or reflex vomiting. By occupation, residents who exclusively perform treatment accounted for 36.4%, which may have been due to similar reasons.

Approximately 60% of dentists mostly took preventive measures in all groups of clinical experience, whereas only 17.1 and 23.8% of those with 1–3 and 3–5 years of experience, respectively, always took measures. Dentists

in training who had less than one year of experience and who were not used to dental practice could, nonetheless, take sufficient time and were always supervised, resulting in a high rate (31.4%). However, this group became busier and could not spare time to take preventive measures after the 2nd year as the number of patients increased, decreasing the rate. The rate increased to about 40% in dentists with experience of 5 years or longer who may have become able to afford the time to take preventive measures. However, 3.6% of dentists with experience of 10 years or longer took no preventive measures. This may indicate that they were used to practice and had become complacent, which is very dangerous.

The results of this study indicate that repeated courses and individual instruction for repeaters and the establishment of a surveillance system along with the preparation of manuals to manage violations would help decrease accidental ingestion/aspiration.

### Acknowledgements

We wish to thank Prof. Toru Sato for his assistance with the revision of this manuscript.

### References

- 1) Beaumont RH (1987) Retrieval of a swallowed casting 6 weeks after ingestion. A case report. *Oral Surg Oral Med Oral Pathol* 64:287–288.
- 2) Brunello DL, Mandikos MN (1995) A denture swallowed. Case report. *Aust Dent J* 40:349–351.
- 3) Cleator IG, Christie J (1973) An unusual case of swallowed dental plate and perforation of the sigmoid colon. *Br J Surg* 60:163–165.
- 4) Colaizzi FA, Chmielarski JJ, Mortellaro ES Jr (1980) Swallowing of central bearing plate. *J Am Dent Assoc* 100:382–383.
- 5) Cooke LD, Baxter PW (1992) Accidental impaction of partial dental prostheses in upper gastrointestinal tract. *Br Dent J* 172: 451–452.
- 6) Cottrell SG, Hanley JM (2001) Swallowed partial denture. A case report. *Gen Dent* 49:384–385.

- 7) Drinnan A (1967) Dangers of using radiolucent dental materials. *J Am Dent Assoc* 74: 446–450.
- 8) Fort S, Batty GM, Wilkins WE (1989) Prolonged pharyngeal impaction of dentures following stroke. *Stroke* 20:1748–1750.
- 9) Gibbons CL, Woodward RT (1988) The aspirated foreign body: an unusual diagnostic marker. *Br Dent J* 165:294–295.
- 10) Giovannitti JA (1981) Aspiration of a partial denture during an epileptic seizure. *J Am Dent Assoc* 103:895.
- 11) Goodacre CJ (1987) A dislodged and swallowed unilateral removable partial denture. *J Prosthet Dent* 58:124–125.
- 12) Goultschin J, Heling B (1971) Accidental swallowing of an endodontic instrument. *Oral Surg Oral Med Oral Pathol* 32:621–622.
- 13) Govilla CP (1979) Accidental swallowing of an endodontic instrument. *Oral Surg Oral Med Oral Pathol* 47:269–271.
- 14) Grossman LI (1974) *Endodontic practice*, 8th ed., pp. 151–158, Lea & Febiger, Philadelphia.
- 15) Hazelrigg CO (1984) Ingestion of mandibular complete denture. *J Am Dent Assoc* 108:209.
- 16) Jacobs LI (1980) Ingestion of partial denture. *J Am Dent Assoc* 101:801.
- 17) McLaughlin MG, Swayne LC, Caruana V (1989) Computed tomographic detection of a swallowed denture. *Comp Med Imaging Graph* 13:161–163.
- 18) Perenack DM (1980) Ingestion of mandibular complete denture. *J Am Dent Assoc* 101:802.
- 19) Pukkula A, Ruotsalainen EM, Jokinen K, Palva A, Nuorviita J (1988) Long-term presence of a denture fragment in the airway. *J Laryngol Otol* 102:190–193.
- 20) Sugawara C, Takahashi A, Maeda N, Kubo M, Kudoh H, Hosoki H, Iwasaki Y (2007) An investigation of accidental aspiration and swallowing during the dental treatment at Tokushima University Dental Hospital. *Shikoku Dent Res* 19:255–262. (in Japanese)
- 21) Szabo M, Szabo I, Buris L (1972) Abbreviated case report. Foreign bodies of dental origin in the esophagus. *Oral Surg Oral Med Oral Pathol* 34:196–198.
- 22) Teska TP, Smith CC (1991) Swallowed partial denture. *Oral Surg Oral Med Oral Pathol* 72: 756–757.
- 23) Theodore EDP, Gary LR, Beverly JY (1984) Dental prosthesis as an unsuspected foreign body. *Ann Emerg Med* 13:109–111.
- 24) Zissin R, Shapiro-Feinberg M, Rozenman J, Apter S, Smorjick J, Hertz M (2001) CT findings of the chest in adults with aspirated foreign bodies. *Eur Radiol* 11:606–611.

*Reprint requests to:*

Dr. Ryuichi Hisanaga  
Department of Crown and  
Bridge Prosthodontics,  
Tokyo Dental College,  
1-2-2 Masago, Mihama-ku,  
Chiba 261-8502, Japan  
Tel: +81-43-270-3938  
Fax: +81-43-270-3937  
E-mail: hisanaga@tdc.ac.jp