

Evaluation of Platelet-Rich Plasma in Combination with Deproteinized Bovine Bone Mineral in the Rabbit Cranium; A Pilot Study

Y. Soleymani Shayesteh^{1, ✉}, A. Khorsand², P. Motahhary^{3,4}, M. Dehghan⁵,
MA. Shafiee Ardestani⁶

¹Associate Professor, Department of Periodontology, Faculty of Dentistry, Tehran University of Medical Sciences, Tehran, Iran

²Assistant Professor, Department of Periodontology, Faculty of Dentistry, Tehran University of Medical Sciences, Tehran, Iran

³Assistant Professor, Dental Research Centre, Tehran University of Medical Sciences, Tehran, Iran

⁴Assistant Professor, Department of Oral & Maxillofacial Pathology, Faculty of Dentistry, Tehran University of Medical Sciences, Tehran, Iran

⁵Assistant Professor, Department of Veterinary Surgery, Faculty of Veterinary Medicine, Tehran University

⁶Periodontist, Private practice

Abstract:

Statement of Problem: Reconstruction methods are an essential prerequisite for functional rehabilitation of the stomatognathic system. Platelet-rich plasma (PRP) offers a new and potentially useful adjunct to bone substitute materials (e.g. Xenografts) in oral and maxillofacial bone and implant reconstructive surgery.

Purpose: An animal study was carried out to investigate the influence of PRP on the regeneration of non-critical sized bony defects, treated with Deproteinized Bovine Bone Mineral (DBBM).

Materials and Methods: Eight New Zealand white rabbits were included in this randomized, pilot study. Three equal cranial bone defects (3×6 mm) were created and immediately grafted with DBBM and PRP+DBBM; one of them was left unfilled to serve as a control. The defects were evaluated using histologic and histomorphometric analysis at 2, 4, 8 and 12 weeks.

Results: The histomorphometric findings showed a significant increase in bone area and trabecular maturity in experimental defects as compared to the control at 4, 8 and 12 week intervals. A significant increase in bone formation was seen with the addition of PRP to DBBM at 2, 4 and 8 week intervals. At 12 weeks, the level of bone formation was similar between the two groups. There was also a significant increase in the rate of biodegradation of the DBBM particles with the addition of PRP at 2, 4, 8 and 12 weeks. No foreign body reaction and severe inflammation was seen in any of specimens.

Conclusion: Within the limitations of this pilot study, it was concluded that the addition of PRP to Xenogenic bone substitute material in non-critical-sized defects of the rabbit cranium showed a histomorphometric increase in bone formation (until the 8th week of healing) and a greater amount of biomaterial degradation throughout the study period.

Key Words: Bone grafting; Deproteinized Bovine Bone Mineral; Platelet-rich Plasma; Histomorphometry; Trabecular maturity

Journal of Dentistry, Tehran University of Medical Sciences, Tehran, Iran (2005; Vol: 2, No.4)

✉ Corresponding author:

Y. Soleymani Shayesteh,
Department of Periodontology,
Tehran University of medical
sciences, Gods St., Keshavarz
Bulv., Post Code: 14147,
Tehran, Iran.
drshayesteh20@yahoo.com

Received: 25 February 2005

Accepted: 19 October 2005

INTRODUCTION

Autogenous bone grafts from intra- or extra-oral donor sites, known as gold standard, are

used especially to regenerate bony defects in the craniofacial region [1]. The disadvantage of donor morbidity, using autogenous bone,

can be avoided by using bone substitutes.

A variety of degradable or permanent mainly osteoconductive bone substitutes like tricalcium-phosphate or xenogenic hydroxyapatite-ceramics are available [2].

The use of platelet-rich plasma (PRP) offers a potentially useful adjunct to autogenous, allogenic and xenogenic graft material in oral and maxillofacial bone and implant reconstructive surgery. Some authors also suggest that the addition of PRP to osteoconductive grafting materials can potentiate osteoinduction [3]. Clinical trials indicate that the combination of bone graft substitutes and growth factors such as cytokines contained in platelet-rich plasma (PRP) may be suitable to enhance bone density [4,5]. Platelets are very important in the wound healing process. They arrive quickly to the wound site and begin the coagulation process. They release multiple wound-healing growth factors and cytokines, including platelet-derived growth factor (PDGF), transforming growth factors beta 1 and 2 (TGF- β 1 and TGF- β 2), vascular endothelial growth factor (VEGF), platelet-derived endothelial cell growth factor (PDEGF), basic fibroblast growth factor (bFGF), and platelet activating factor-4 (PAF-4) [2,6].

These growth factors are thought to contribute to bone regeneration and increased vascularity, the vital feature of a healing bone graft.

Questions exist whether PRP can be utilized with alloplasts, xenografts, or allograft materials without the incorporation of autogenous donor bone to create a bone graft, comparable to autogenous bone. Results of studies attempting to answer these questions, are conflicting or equivocal [7,8].

Further scientific testing of PRP is obviously necessary. The present study was carried out to evaluate the effectiveness of PRP on bone healing; utilizing Deproteinized Bovine Bone Mineral (DBBM) in rabbit non-critical sized calvarial defects.

MATERIALS AND METHODS

Eight New Zealand white male rabbits between 2.5 and 3 kg were included in this randomized blind pilot study.

Each rabbit was anesthetized with an intramuscular injection of ketamine 10% (40mg/kg) and 5mg/kg of Xylazin 2% (Alafason, Woeden, Holland). Then the fur was shaved over the cranium and prepped and draped in a sterile fashion.

Following a coronal-sagittal approach, the periosteum was dissected and three identical full thickness bony defects (terminated over the Dura mater) were created with a round bur (3×6 mm) in the frontal and parietal bones with a distance of approximately 2mm from the sagittal and coronal sutures. The defects were randomly filled with DBBM (Bio-Oss[®]; Geistlich and Sons, Wolhusen, Switzerland), or DBBM + PRP; A volume of 0.5 ml PRP was available for each defect which was mixed with approximately 30 mg of DBBM particles (particle size=0.25-1mm) in a sterile dish. One defect was left unfilled to serve as a control defect. The wounds were closed with resorbable 4/0 suture (Vicryl. Johnson & Johnson. Somerville. NJ) for periosteal closure and non resorbable 4/0 suture (SURGIPRO[™] Polypropylene Monofilament. Richmond, VA, United States) for the calvarial skin.

The rabbits recovered from anesthesia without complications. They were given postoperative narcotic pain medication (ketoprofen 0.1mg/day) for 3 days and antibiotic (Enrofloxacin 0.6mg/day) for one week, subcutaneously.

PRP samples were prepared using a modification of the Curasan technique [6]. The 6 mL autologous blood drawn from each rabbit was combined with 0.5 mL of anticoagulant citrate dextrose phosphate (ACD-A) to prevent coagulation. The blood was centrifuged at 1,200 rpm (160 g) for 20 minutes to separate the plasma containing the platelets from the red cells. (CLEMENTS

2000, Sydney. Australia) The plasma was drawn off the top, centrifuged for an additional 15 minutes at 2,000 rpm (400 g) to separate the platelets. The platelet poor plasma was separated from the PRP along with the buffy coat. The buffy coat and PRP, approximately 0.5 mL, was resuspended and used within minutes to add to the grafting materials. Platelet counts were performed on each sample, including a peripheral blood count, and PRP count.

Rabbits were euthanized using pentobarbital, 100 mg/kg intravenously at 2, 4, 8 and 12 weeks. There were 2 animals in each group.

The entire cranium was removed with a reciprocating saw, without encroaching on the grafted areas. Specimens were treated with 20% formic acid decalcifying solution for three days. They were then dehydrated with alcohols and embedded in paraffin. Histologic sections were prepared perpendicular to the long axis of each defect in an anterior to posterior direction with a thickness of 5 μ m. Finally, 20 sections from each defect (350 μ m distance between two succeeding sections) were provided. The specimens were prepared in the usual fashion with H&E staining. Histologic evaluation was performed at 40-400X magnifications. The 40X magnification was used for histomorphometric analysis.

400x magnified photomicrographs (Olympus BX 51 – Olympus co., Tokyo, Japan) were used for the assessment of foreign body reaction. The same magnification was also utilized to evaluate the interface between bone and biomaterial particles.

Polarized light microscopy was used to determine the proportion of lamellar and woven trabeculae in each specimen. Concentrically aligned collagen bundles in the bony trabeculae were interpreted as lamellar bone, whereas irregularly oriented collagen fibers in the trabeculae were documented as woven bone.

Histomorphometric analysis of bone and

biomaterial areas were carried out using photomicrographs with a magnification of 40X (Olympus DP12 digital camera – Olympus co., Tokyo, Japan) and a graphic software (Photoshop 8 CS, Adobe Photoshop CS).

Areas including newly regenerated bone were selected according to their similar color properties. The pixel counts of these areas were calculated (same software) and divided by the total pixel number of each photomicrograph. The same procedure was advocated for calculating the histomorphometric area of the remaining biomaterials. Evaluators were blinded to the graft material and time period of each sample. Statistical analysis included Kruskal-Wallis and Dunn procedures for qualitative variables and ANOVA (repeated measure) with Post Hoc for quantitative variables using SPSS software (SPSS for windows.11.5).

RESULTS

Platelet counts confirmed that the PRP preparation technique used in this study produced a source of highly concentrated platelets with the collection efficiency [6] of 34.96%(4.06). The average (standard deviation) peripheral blood platelet count and the average PRP platelet count was 473274 (49067)/mm³ and 1670064 (345548)/mm³, respectively (Fig. 1).

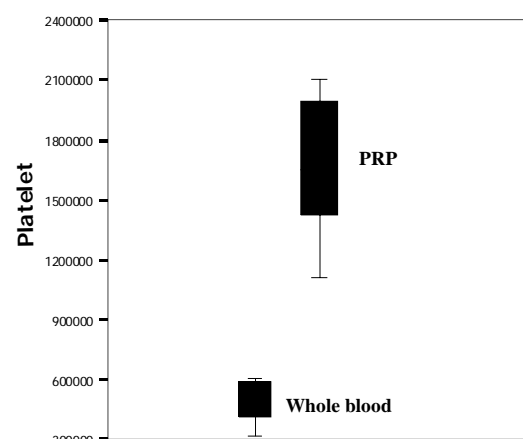


Fig. 1: Changes in platelet count in the process of PRP preparation

Histological evaluation revealed neither foreign body reaction nor severe inflammation in each of the evaluated specimens (Fig. 2). Direct bone-biomaterial contact without intervening connective tissue was observed whenever new bone formation occurred in the DBBM and DBBM+PRP treated groups. The degree of trabecular maturation assessed by polarized light microscopy showed statistically significant differences between DBBM + PRP and DBBM groups with the control group in all time-intervals in the favor of using DBBM particles. Adding PRP caused a slight tendency toward more frequent lamellar trabeculae (Table I), although the differences were not statistically significant ($P > 0.05$) (Table II).

Descriptive statistics of histomorphometric data from all three evaluated groups is presented in Table III.

Figure 3 shows the histomorphometric bone area as a function of time for each grafting material. DBBM and DBBM+PRP showed a statistically significant increase in the amount of regenerated bone over the control sites at 4, 8 and 12 weeks ($P < 0.001$). Adding PRP, also significantly increased the amount of bone area as compared to DBBM alone in all time intervals except for the 12 weeks period. DBBM+PRP constantly showed a greater rate of biomaterial degradation in comparison to DBBM alone. The differences are also statistically significant (Table II).

DISCUSSION

Researchers in oral and maxillofacial surgery continuously strive to improve current bone-grafting techniques and provide a faster and denser bony regenerate. Growth factors are a realistic way to improve and expedite both soft

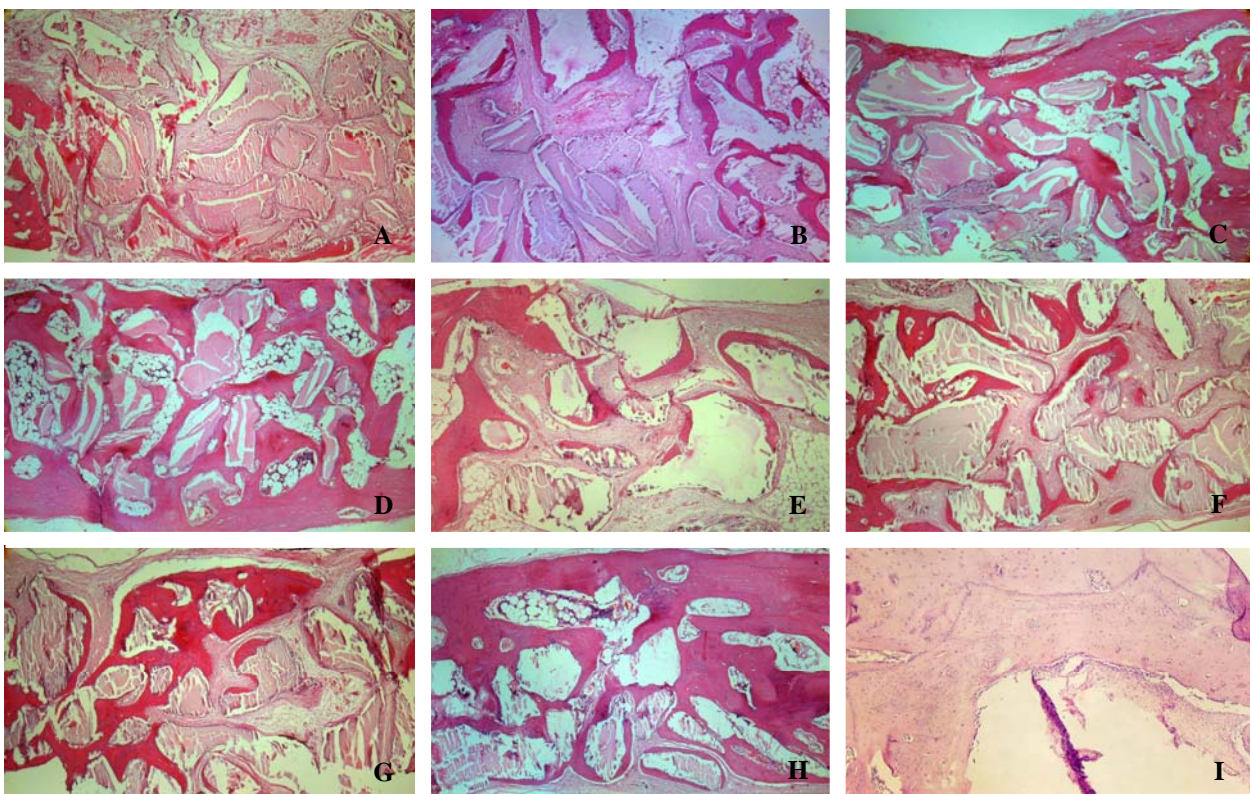


Fig. 2: Photomicrographs of the experimental groups; A, B, C, and D are DBBM group in 2, 4, 8 and 12 weeks study period respectively. E, F, G, and H are PRP + and DBBM group in 2, 4, 8 and 12 weeks study intervals respectively. I: illustrate the control defect at the end of study period (40X, H&E stained).

Table I: Bone regeneration (%) in study groups at different time intervals.

	2 weeks			4 weeks			8 weeks			12 weeks		
	I	II	III	I	II	III	I	II	III	I	II	III
PRP+ Bio-Oss	0	22.5	77.5	22.5	77.5	0	40	60	0	62.5	37.5	0
Bio-Oss	0	17.5	82.5	17.5	82.5	0	37.5	62.5	0	60	40	0
Control	0	0	100	0	55	45	0	80	20	30	70	0

I: lamellar bone; II: lamellar and woven bone; III: woven bone.

tissue and bony wound healing. Platelets contain angiogenic, mitogenic, and vascular growth factors in their granules [2,6]. Platelets have a physiologic store of VEGF, which can be released when they are activated or aggregated by collagen. TGF-β1 and TGF-β2 have been shown to inhibit bone resorption, osteoclast formation, and osteoclast activity, as well as to trigger rapid maturation of collagen

in early wounds [9]. PDGF increases the population of wound healing cells and recruits other angiogenic growth factors to the wound site [2]. It is therefore a reasonable hypothesis that increasing the concentration of platelets in a bone defect may lead to improved, faster healing.

In the present study, the combined effect of using PRP and a Xenograft (Deproteinized Bovine Bone Mineral) in treating non- critical

Table II: Comparison of bone regeneration and remaining biomaterial between different study groups in each interval (* indicates statistical significance).

Time	Variables	Type of bone	Bone (%)	Biomaterial (%)
2 weeks	PRP & Bio-Oss		*	*
	Bio-Oss & Control	*		
	PRP & Control	*		
4 weeks	PRP & Bio-Oss		*	*
	Bio-Oss & Control	*	*	
	PRP & Control	*	*	
8 weeks	PRP & Bio-Oss		*	*
	Bio-Oss & Control	*	*	
	PRP & Control	*	*	
12 weeks	PRP & Bio-Oss			*
	Bio-Oss & Control	*	*	
	PRP & Control	*	*	

Table III: Descriptive statistics of histomorphometric data from all three evaluated groups

Time	Study groups	Biomaterial (%)	Bone (%)
2 weeks	PRP	62.71 (4.98)	9.60 (3.74)
	Bio-Oss	62.27 (4.17)	7.86 (1.42)
	Control	—	7.97 (2.58)
4 weeks	PRP	38.82 (3.53)	24.72 (4.18)
	Bio-Oss	49.05 (4.27)	15.30 (2.65)
	Control	—	11.47 (2.87)
8 weeks	PRP	30.06 (4.02)	37.18 (4.43)
	Bio-Oss	33.04 (4.24)	33.35 (4.25)
	Control	—	19.27 (2.58)
12 weeks	PRP	19.69 (4.19)	58.92 (5.10)
	Bio-Oss	22.79 (4.45)	57.70 (4.74)
	Control	—	26.89 (3.68)

sized rabbit cranial defects were evaluated. Histologic assessment revealed that DBBM is a biocompatible, osteoconductive grafting material with no sign of foreign body reaction and/or severe inflammation in conjunction with its application. Adding PRP to this material did not affect its biocompatibility. These results are in accordance with those of Donos et al [10], Slotte & Lundgren [11], and Berglundh & Lindhe [12].

Microscopic assessment using polarized light showed that trabecular bone maturation (from woven bone to lamellar bone) occurs in all experimental groups (including controls) with increasing time, but the amount of lamellar bone was significantly greater in grafted areas as compared to the controls in all time intervals. Philippart et al [13], Artzi et al [14], and Maiorana et al [15] also showed that lamellar bone formation occurs in areas where PRP and/ or DBBM were used.

Histomorphometric evaluation of the amount of newly regenerated bone and remaining biomaterial particles showed that adding PRP to DBBM caused significant increase in bone formation at 2, 4 and 8 weeks, but the level of bone regeneration had adjusted in the PRP (+) and PRP (-) groups at 12 weeks. These findings are in accordance with Aghaloo et al

[16], Wiltfang et al [18], and Kim et al [3]; but differs from the results of Wiltfang et al [17] and, Fuerst et al [19]. The discrepancies observed in the results of PRP investigations, may be due to differences in study design (animal/ human), collection efficiency of the PRP kit, methods of evaluation (radiography/ histology) and shape, size, and configuration of the evaluated defects.

Another interesting finding was the ability of Xenogenic biomaterial (DBBM) in contributing to physiologic bone remodeling as manifested by continuous reduction in the amount of the histomorphometric area of biomaterial particles between succeeding time intervals. Similar findings were reported by Berglundh & Lindhe [12] and Merckx et al [20]. Additionally, PRP significantly increased the rate of degradation of the biomaterial (DBBM) in all time intervals. It should be mentioned that the sample size was relatively small, consisting of 2 rabbits in each time period of 2, 4, 8, and 12 weeks. On the other hand, a true critical-sized cranial defect in the rabbit model is 15mm [22]. Therefore, three critical-sized defects cannot be created in the rabbit cranium due to the small size of the cranium. We choose a noncritical- sized defect to evaluate the early healing, and the potential ability of PRP to improve this early healing when it was added to Deproteinized xenogenic grafting materials.

Finally, it seems that the need for further investigation on the potential benefits of PRP in combination with various autogenous, allogenic, alloplastic and Xenogenic grafting materials is clearly apparent before making definitive decisions about its application in routine clinical procedures.

CONCLUSION

Considering the limitations of this pilot study, Platelet Rich Plasma added additional benefits by increasing the amount of regenerated bone when Xenogenic bone substitute(Bio-Oss) was

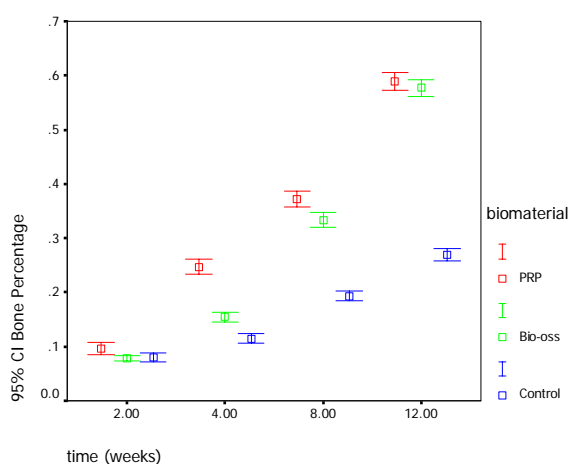


Fig. 3: Histomorphometric evaluation of bone area over the 12 weeks study period.

used in rabbit cranial defects (until the 8 weeks of healing). The rate of biomaterial degradation was also greater in DBBM+PRP group compared to DBBM alone throughout the study period.

ACKNOWLEDGMENT

This study was a research project carried out in Dental Research Center and was supported by a grant from the Research Council of Tehran University of Medical Sciences, Tehran, Iran. The authors also would like to thank Prof. A.A Khoshkhoonejad and Dr. A. Miremadi for their invaluable guidance.

REFERENCES

- 1- Nkenke E, Schultze-Mosgau S, Radespiel-Troger M, Kloss F, Neukam FW. Morbidity of harvesting of chin grafts: a prospective study. *Clin Oral Implants Res* 2001 Oct;12(5):495-502.
- 2- Lynch SE, Genco RJ, Marx RE. Tissue engineering, Applications in maxillofacial surgery and periodontics 1st ed. Quintessence publishing Co; 1999.
- 3- Kim SG, Chung CH, Kim YK, Park JC, Lim SC. Use of particulate dentin-plaster of Paris combination with/without platelet-rich plasma in the treatment of bone defects around implants. *Int J Oral Maxillofac Implants* 2002;17(1):86-94.
- 4- Marx RE, Carlson ER, Eichstaedt RM, Schimmele SR, Strauss JE, Georgeff KR. Platelet-rich plasma: Growth factor enhancement for bone grafts. *Oral Surg Oral Med Oral Pathol Oral Radiol Endod* 1998 Jun;85(6):638-46.
- 5- Kassolis JD, Rosen PS, Reynolds MA. Alveolar ridge and sinus augmentation utilizing platelet-rich plasma in combination with freeze-dried bone allograft: case series. *J Periodontol* 2000 Oct;71(10):1654-61.
- 6- Weibrich G, Kleis WK, Hafner G, Hitzler WE, Wagner W. Comparison of platelet, leukocyte, and growth factor levels in point-of-care platelet-enriched plasma, prepared using a modified Curasan kit, with preparations received from a local blood bank. *Clin Oral Implants Res* 2003 Jun;14(3):357-62.
- 7- Shanaman R, Filstein MR, Danesh-Meyer MJ. Localized ridge augmentation using GBR and platelet-rich plasma: case reports. *Int J Periodontics Restorative Dent* 2001 Aug;21(4):345-55.
- 8- Anitua E. Plasma rich in growth factors: preliminary results of use in the preparation of future sites for implants. *Int J Oral Maxillofac Implants* 1999 Jul-Aug;14(4):529-35.
- 9- Maloney JP, Silliman CC, Ambruso DR, Wang J, Tuder RM, Voelkel NF. In vitro release of vascular endothelial growth factor during platelet aggregation. *Am J Physiol* 1998 Sep;275(3 Pt 2):H1054-61.
- 10- Donos N, Bosshardt D, Lang N, Graziani F, Tonetti M, Karring T, Kostopoulos L. Bone formation by enamel matrix proteins and xenografts: an experimental study in the rat ramus. *Clin Oral Implants Res* 2005 Apr;16(2):140-6.
- 11- Slotte C, Lundgren D. Augmentation of calvarial tissue using non-permeable silicone domes and bovine bone mineral. An experimental study in the rat. *Clin Oral Implants Res* 1999 Dec;10(6):468-76.
- 12- Berglundh T, Lindhe J. Healing around implants placed in bone defects treated with Bio-Oss. An experimental study in the dog. *Clin Oral Implants Res* 1997 Apr;8(2):117-24.
- 13- Philippart P, Basseur M, Hoyaux D, Pochet R. Human recombinant tissue factor, platelet-rich plasma, and tetracycline induce a high-quality human bone graft: a 5-year survey. *Int J Oral Maxillofac Implants* 2003 May-Jun;18(3):411-6.
- 14- Artzi Z, Tal H, Dayan D. Porous bovine bone mineral in healing of human extraction sockets. Part 1: histomorphometric evaluations at 9 months. *J Periodontol* 2000 Jun;71(6):1015-23.
- 15- Maiorana C, Redemagni M, Rabagliati M, Salina S. Treatment of maxillary ridge resorption by sinus augmentation with iliac cancellous bone, anorganic bovine bone, and endosseous implants: a clinical and histologic report. *Int J Oral Maxillofac Implants* 2000 Nov-Dec;15(6):873-8.
- 16- Aghaloo TL, Moy PK, Freymiller EG. Evaluation of platelet-rich plasma in combination

with anorganic bovine bone in the rabbit cranium: a pilot study. *Int J Oral Maxillofac Implants* 2004 Jan-Feb;19(1):59-65.

17- Wiltfang J, Kloss FR, Kessler P, Nkenke E, Schultze-Mosgau S, Zimmermann R, Schlegel KA. Effects of platelet-rich plasma on bone healing in combination with autogenous bone and bone substitutes in critical-size defects. An animal experiment. *Clin Oral Implants Res* 2004 Apr;15(2):187-93.

18- Wiltfang J, Schlegel KA, Schultze-Mosgau S, Nkenke E, Zimmermann R, Kessler P. Sinus floor augmentation with beta-tricalciumphosphate (beta-TCP): does platelet-rich plasma promote its osseous integration and degradation? *Clin Oral Implants Res* 2003 Apr;14(2):213-8.

19- Fuerst G, Gruber R, Tangl S, Sanroman F, Watzek G. Enhanced bone-to-implant contact by

platelet-released growth factors in mandibular cortical bone: a histomorphometric study in minipigs. *Int J Oral Maxillofac Implants* 2003 Sep-Oct;18(5):685-90.

20- Merckx MA, Maltha JC, Freihofer HP. Incorporation of composite bone implants in the facial skeleton. *Clin Oral Implants Res* 2000 Oct;11(5):422-9.

21- Skoglund A, Hising P, Young C. A clinical and histologic examination in humans of the osseous response to implanted natural bone mineral. *Int J Oral Maxillofac Implants* 1997 Mar-Apr;12(2):194-9.

22- Vikjaer D, Blom S, Hjorting-Hansen E, Pinholt EM. Effect of platelet-derived growth factor-BB on bone formation in calvarial defects: an experimental study in rabbits. *Eur J Oral Sci* 1997 Feb;105(1):59-66.

مطالعه پایلوت ارزیابی اثر ترکیب پلاسمای غنی شده از پلاکت و ماده معدنی دپروتئینه استخوان گاو در جمجمه خرگوش

ی. سلیمانی شایسته^۱ - ا. خورسند^۲ - پ. مطهری^۳ - م. دهقان^۴ - م. ا. شفیع اردستانی^۶

^۱ نویسنده مسئول؛ دانشیار گروه آموزشی پرودنتولوژی، دانشکده دندانپزشکی، دانشگاه علوم پزشکی تهران، تهران، ایران
^۲ استادیار گروه آموزشی پرودنتولوژی، دانشکده دندانپزشکی، دانشگاه علوم پزشکی تهران، تهران، ایران
^۳ استادیار، مرکز تحقیقات دندانپزشکی، دانشگاه علوم پزشکی تهران، تهران، ایران
^۴ استادیار گروه آموزشی آسیب‌شناسی دهان فک و صورت، دانشکده دندانپزشکی دانشگاه علوم پزشکی تهران، تهران، ایران
^۵ استادیار گروه آموزشی جراحی، دانشکده دندانپزشکی، دانشگاه تهران، تهران، ایران
^۶ پرودنتیست

چکیده

بیان مسأله: درمان‌های بازسازی از ملزومات اساسی در بازتوانی عملکرد سیستم دهانی - فکی هستند. به نظر می‌رسد پلاسمای غنی شده از پلاکت (PRP) به عنوان یک ماده جدید می‌تواند به طور بالقوه در کنار مواد جایگزین استخوان (مانند Xenografts) در بازسازی استخوان‌های ناحیه فک و صورت و همچنین در درمان ایمپلنت‌های دندانی مفید باشد.

هدف: مطالعه با هدف ارزیابی اثر PRP در بازسازی ضایعات استخوانی با اندازه غیر Critical درمان شده با ماده معدنی دپروتئینه استخوان گاو (DBBM) طراحی گردید.

روش تحقیق: هشت خرگوش سفید نیوزلندی در این مطالعه پایلوت و تصادفی شده وارد شدند. در جمجمه هر خرگوش سه ضایعه با اندازه‌های مساوی (۶×۳ میلی‌متر) ایجاد شد؛ دو ضایعه به وسیله DBBM با یا بدون PRP پر گشته و حفره سوم بدون درمان به عنوان کنترل در نظر گرفته شد. ضایعات پس از دو، چهار، هشت و ۱۲ هفته با استفاده از روش‌های هیستولوژیک و هیستومورفومتریک ارزیابی و مقایسه شدند.

یافته‌ها: آزمایش‌های هیستومورفومتریک نشانگر افزایش معنی‌دار میزان استخوان و بلوغ تراکول‌های استخوانی در دو گروه آزمایش نسبت به گروه کنترل در زمانهای چهار، هشت و ۱۲ هفته بود. در گروه DBBM به همراه PRP در تمامی زمانها میزان تجزیه DBBM سریعتر بود. همچنین در هفته دوازدهم شکل‌گیری استخوان در دو گروه آزمایش با هم مشابه بود. واکنش جسم خارجی و التهاب شدید در هیچ‌کدام از نمونه‌ها مشاهده نشد.

نتیجه‌گیری: با در نظر گرفتن محدودیت‌های این مطالعه می‌توان نتیجه گرفت اضافه کردن PRP به ترکیبات گزینگرافت در ضایعات غیر Critical در جمجمه خرگوش تا هفته هشتم سبب افزایش شکل‌گیری استخوان می‌شود. همچنین این کار باعث تجزیه سریعتر ماده معدنی در تمامی زمانهای مطالعه می‌گردد.

واژه‌های کلیدی: پیوندهای استخوانی؛ ماده معدنی و پروتئینه استخوان گاو؛ پلاسمای غنی از پلاکت؛ هیستومورفومتري

مجله دندانپزشکی دانشگاه علوم پزشکی و خدمات بهداشتی، درمانی تهران (دوره ۲، شماره ۴، سال ۱۳۸۴)