

TRACHEAL AND SUBGLOTTIC PARAGANGLIOMA, A CASE REPORT

K. Khalkhali^{*1}, A. Nadimi-Tehrani¹, N. Yazdani¹ and A. Azizi²

1) Department of Otolaryngology, Imam Khomeini Hospital, School of Medicine, Tehran University of Medical Sciences, Tehran, Iran

2) Department of Pathology, Shahriar Hospital, School of Medicine, Tehran University of Medical Sciences, Tehran, Iran

Abstract- In the head and neck region, tracheal and larynx paragangliomas are much less common and subglottic paragangliomas have been rarely reported. Less than 60 cases with larynx paraganglioma and a few cases with trachea paraganglioma have been reported until now in the literature. This report describes a 28 year old man suffering from progressive dyspnea due to tracheal and subglottal tumor. Histopathology of tumor after surgery showed paraganglioma. Clinical features, histological appearance and differential diagnosis as well as treatment are discussed.

Acta Medica Iranica, 43(5): 377-380; 2005

Key words: Paraganglioma, trachea, larynx

INTRODUCTION

Paragangliomas are neuroendocrine neoplasms which were first described in 1880. Paraganglioma arises from multicentric system of extra adrenal paraganglia cells derived from the neural crest. Paraganglionic tissues have been found in more than 20 anatomic sites. Paragangliomas of larynx and trachea have been reported rarely, with the majority located in the larynx. Only a few cases of tracheal and subglottic paragangliomas have been reported previously. The first case of paraganglioma of larynx was reported in 1953 and there have been less than 60 cases of laryngeal or tracheal paragangliomas documented in the world literature since then (1).

This report describes a 28 year old man with tracheal and subglottic paraganglioma.

Received: 16 Aug. 2004 , Revised: 26 Oct. 2004 , Accepted: 14 Feb. 2005

*** Corresponding Author:**

K. Khalkhali, Department of otolaryngology, Imam Khomeini Hospital, School of Medicine, Tehran University of Medical Sciences, Tehran, Iran
Tel: +98 21 66932626
Fax: +98 21 66932627
E-mail: khalkhalikazem@yahoo.com

CASE REPORT

We report a 28 year old man with progressive dyspnea without hoarseness, dysphagia, cervical mass and neck pain whose symptoms began in February 2000. He was treated for misdiagnosed asthma. The patient was not a cigarette smoker.

Physical examination did not show any abnormalities in larynx and neck. His dyspnea became progressively worse and a tracheostomy was performed in September 2001. At this time lateral radiograph of neck showed a transluminal obstruction above the tracheostomy site (Fig. 1).

Laryngoscopic and bronchoscopic investigations revealed a subglottic tumor mass measured 1 cm in its largest diameter and its bulge occupying all the subglottic space.

Laryngeal mucosa was intact and there was no necrosis in laryngeal mucosa. A biopsy was taken from tumor and biopsy result showed dysplasia and chronic inflammation. After 2 months he presented to Imam Khomeini Hospital. Computed tomography revealed a subglottic mass which had extended into trachea and had resulted in obstruction (Fig. 2).

Tracheal and subglottic paraganglioma

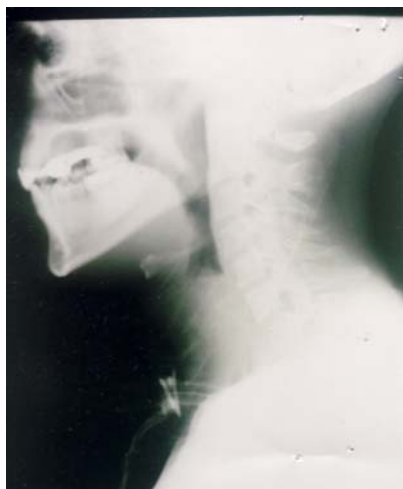

Fig. 1. Lateral radiograph of neck showing a transluminal obstruction above the tracheotomy site.

Laryngoscopy revealed a mass in posterior part of subglottic area below the posterior commissure that extended to the 3rd tracheal ring. Mucosal wall of trachea was intact.

Because of unclear result of previous biopsy another biopsy was done and pathological diagnosis showed paraganglioma. Immunohistochemistry proved the diagnosis as tracheal and subglottic paraganglioma in November 25, 2001. A laryngo fissure was performed and the tumor extending from subglottic area to third tracheal ring was removed completely while the patient was intubated.

Surprisingly the pathological diagnosis showed paraganglioma. After surgery angiography was done to remove other cervical mass lesions. Angiography demonstrated no cervical lesion. Follow up examination 2 years after surgery showed no evidence of residual tumor and evidence of metastatic tumor. We did another biopsy and it was without massive hemorrhage.

Histopathologic finding

First specimen included 3 slices measuring from 0.5 cm to 1 cm. The external surface of slices was smooth and pale. The microscopic examination of the section showed respiratory mucosa cell. Edema and vasodilatation in stromal epithelial cells were normal. There were also several slices with Congo red solution observed between crossed polarities. The section exhibited green birefringence characteristic of amyloid structures.

Second specimens include several pale tan slice measuring from 0.5 cm to 3 cm. The microscopic examination of the section showed an epithelial tumor, with organoid pattern. Some part of this formation was more lined by respiratory epithelial cells. The tumor was composed of nests of epithelioid cells with faintly red to clear cytoplasm and centrally placed round nuclei. Each nest was separated with delicate fibrovascular stroma (6-8).

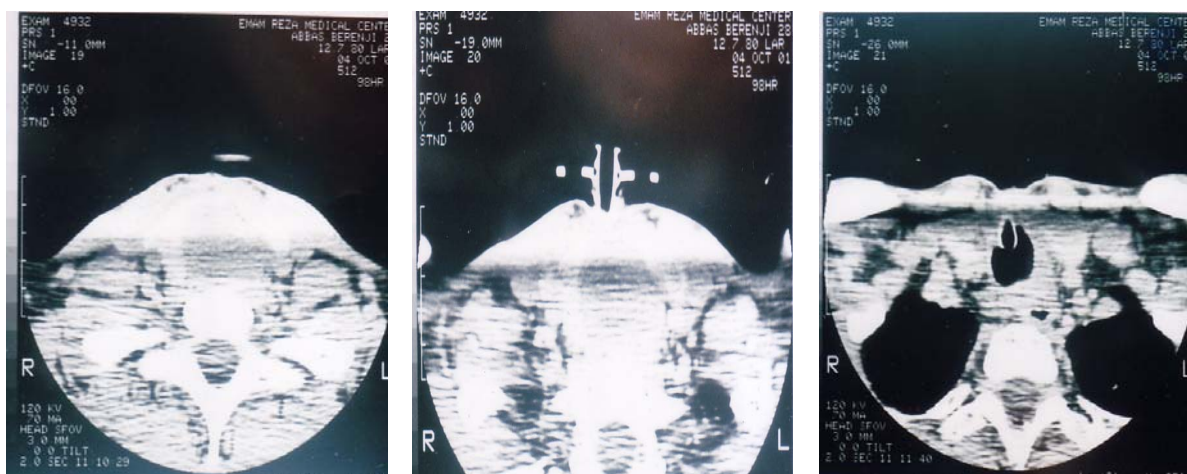


Fig. 2. Different cuts of patient's computed tomography showing a subglottic mass, extending into trachea and resulted in obstruction.

DISCUSSION

Paragangliomas are uncommon neuroendocrine tumors in the head and neck region. The most common locations of paraganglioma within the head and neck are the carotid body at the site of common carotid artery bifurcation, along the course of the vagus nerve, jugular foramen and middle ear. In this region paraganglioma divides into two groups: supra-laryngeal and sub-laryngeal. Paragangliomas are firm rubbery well-capsulated masses composed of nests of epithelioid cells (chief cells) with clear cytoplasm separated by a delicate stroma (Zellballen pattern) (2).

Larynx is one of the rare reported sites of paraganglioma in the head and neck region. Its clinical features are like other laryngeal neoplasms. Hoarseness (most common symptom) dysphagia and dyspnea are common presenting symptoms of laryngeal paraganglioma. Tracheal and subglottic paragangliomas are very rare and their most common symptom is progressive dyspnea. The most common location of paragangliomas in inferior laryngeal space is between cricoid cartilage and first tracheal ring (2, 3).

Paragangliomas are submucosal tumors that occur mainly in the early fifties but may display a variation in age of onset from 8 to 86 years. Incidence is approximately equal for males and females, although reports show greater incidence in women than in men, and it is believed that paragangliomas are the only laryngeal neuroendocrine neoplasm with the female predominance (9). Mitosis, necrosis and vascular invasion are important parameters; histological parameter for charactering malignancy is presence of local invasion of primary tumor and distant metastasis. Metastatic involvements of lung, skull, vertebral bodies and liver have been described. Only 3% of paragangliomas are vagal paraganglioma (4).

Paragangliomas which produce catecholamines are very rare in the head and neck region and occurrence of this type of paragangliomas along the vagus nerve has not been reported yet (3, 6). Neuroendocrine neoplasms of the larynx have been divided into those of epithelial or neural origin, primarily based on light microscopy and supported

by special histochemical studies (9). Angiography is considered to be necessary in patients presented with positive familial history (3, 6, 9).

Differential diagnosis includes carcinoid tumors, granular cell tumors, epithelioid papilloma, squamous cell carcinoma and tumors of salivary glands (1, 9).

Laryngeal and subglottic paragangliomas that cause obstruction and respiratory distress should be treated by surgery. Angiography is a useful investigation for diagnosis of other paraganglioma in affected patient. Before surgery, deep biopsy is necessary for diagnosis. Deep biopsy may cause massive hemorrhage, so surgeon should be ready for surgical exploration. Trachea and subglottic paragangliomas are rare, therefore, there are rare therapeutic strategies for these tumors (3, 7). Some authors have reported endoscopic excision for treatment of small tumors of larynx. In other cases laryngofissure can make the best wide exposure for treatment of tumor. There are different surgical procedures for treatment of these tumors and choice depends on primary location and size of tumor (3, 6, 7, 9). Conservative surgery is therefore, the treatment of choice. Elective neck dissection is not necessary and prognosis is excellent (3, 9).

Since implementation of CO₂ laser surgery into laryngology in 1972 no report of endoscopic laser surgical excision of laryngeal paragangliomas has been published but recently one report about laser removal of paraganglioma has been published (5). Other treatment methods like chemotherapy and radiotherapy are controversial. Radiotherapy is used for decreasing tumor growth. It is also used in cases with incomplete excision of the tumor, recurrence of tumor, metastatic lesions and multiple bilateral lesions. Uses of chemotherapy as a modality for treatment have been reported only in one case, because of inadequate experiments treatment outcomes of chemotherapy are unclear (2, 9).

REFERENCES

1. Wenig BM, Gnepp DR. The spectrum of neuroendocrine carcinomas of the larynx. *Semin Diagn Pathol*. 1989 Nov; 6(4):329-350.

Tracheal and subglottic paraganglioma

2. Googe PB, Ferry JA, Bhan AK, Dickersin GR, Pilch BZ, Goodman M. A comparison of paraganglioma, carcinoid tumor, and small-cell carcinoma of the larynx. *Arch Pathol Lab Med.* 1988 Aug; 112(8):809-815.
3. Pam TES, Gogc Judith Afemy. Paraganglioma of larynx. American Cancer Society; 1998 Dec.
4. Cummings C, Haughey B, Thomas R, Harker L, RobbinsT, Flint P, Schuller D, Richardson M, editors. Cummings' textbook of otolaryngology, head and neck surgery. 4th edition. Mosby;1998.
5. Sesterhenn AM, Folz BJ, Lippert BM, Janig U, Werner JA. Laser surgical treatment of laryngeal paraganglioma. *J Laryngol Otol.* 2003 Aug; 117(8):641-646.
6. Gupta S, Pathak KA, Sanghvi V. Transventricular paraganglioma of the larynx. *Eur Arch Otorhinolaryngol.* 2003 Aug; 260(7):358-360.
7. Wasserman S. Paraganglioma classification pathology and differential diagnosis, *Otolaryngology Clinical North Am.* 2001 May; 127(5): 565-569.
8. Sanders KW, Abreo F, Rivera E, Stucker FJ, Nathan CA. A diagnostic and therapeutic approach to paragangliomas of the larynx. *Arch Otolaryngol Head Neck Surg.* 2001 May; 127(5):565-569.
9. Ferlito A, Barnes L, Rinaldo A, Gnepp DR, Milroy CM. A review of neuroendocrine neoplasms of the larynx: update on diagnosis and treatment. *J Laryngol Otol.* 1998 Sep; 112(9):827-834.