

H. Rokni Yazdi MD¹.
H. Ghanaati MD².

Selective Arterial Embolization in the Treatment of High Flow Priapism: Report of 5 Cases

High flow priapism is a rare entity caused by a pathologic influx from lacerated arteries to the cavernous bodies. Transcatheter embolization of feeding arteries is the treatment of choice. We reviewed a series of 5 patients who underwent transcatheter embolization in our hospital from 2000 to 2004.

The mean age of patients was 32 years; duration of priapism was between one week and a year. All underwent bilateral pudendal artery catheterization with No.5 French Cobra-II catheters. We did not use microcatheters in our patients. Embolized materials were gel-foam, coils and polyvinyl alcohol microspheres. We could follow four of them for 6 to 40 months; one of the patients dropped out from our follow-up study.

All the four patients had completed detumescence after a maximum of two days from embolization; none of them experienced significant complications and all returned to normal sexual function and remained symptom free thereafter (6-40 months).

We noted no difference in complications and duration to restore erectile function and less recurrence rate with embolization of main branch of pudendal artery instead of super-selective embolization of arteriocavernous fistula feeder artery with a microcatheter that is the method of choice for the treatment of high flow priapism, but due to small number of cases it needs further studies to be confirmed.

Key words: high flow priapism, pudendal artery embolization

Introduction

Priapism is characterized by prolonged penile erection unrelated to sexual desire. Two types of priapism are recognized; the more common is called veno-occlusive priapism; the other type, which is a rare entity, is called high flow priapism. Traumatic laceration of penile arteries may lead to high flow priapism caused by a pathologically increased arterial influx to cavernous bodies. The clinical feature is a persistent painless erection with a flaccid glans that develops within hours or days after blunt perineal trauma.¹⁻⁵ Patient's history and physical examination followed by corporeal blood gas analysis and color Doppler ultrasound or arteriogram usually make a diagnosis.⁴

Management of high flow priapism typically includes mechanical, pharmacological, surgical, and radiological.¹⁻⁵ Selective embolization of the cavernous artery, was first described by Wear et al. in 1977.⁶ Materials used for embolization included blood clots, gelatin sponge, bucrylate, polyvinyl alcohol,¹ and coils.^{3,7}

Touge et al. in their review of literature found that the preservation rate of pre-morbid erectile function was 86.1% with embolization; median recovery time after embolization with absorbable material was 60 days and with non-absorbable material, it was 90 days.⁷

We reviewed five patients with high flow priapism who underwent pudendal artery embolization by different embolizing agents, with long term follow up from October 2000 to June 2004 in Imam Khomeini Hospital. Data is sum-

1. Assistant professor, Department of Radiology, Medical Imaging Center, Imam Khomeini Hospital, Tehran University of Medical Sciences, Tehran, Iran.

2. Associate professor, Department of Radiology, Medical Imaging Center, Imam Khomeini Hospital, Tehran University of Medical Sciences, Tehran, Iran.

Corresponding Author:

Hadi Rokni Yazdi

Address: Medical Imaging Center, Imam Khomeini Hospital, Tehran, Iran.

PO Box: 1419733141

Tel: 009821-66438631-3

Fax: 009821-66945117

Mobile: 0098912-1975457

E mail: Hadirokni@yahoo.com

Received February 27, 2005;

Accepted after revision May 7, 2005.

June 2005; 2:167-169

marized in Table 1.

Case 1

A 34-year-old male presented with non-traumatic painless priapism for one year. Physical examination revealed a non-tender penis with approximately 50% rigidity involving only the corpora cavernosa. Initial evaluations at another hospital, including trial of aspiration and irrigation with normal saline and corporo-glandular shunt, had failed. No blood gas studies were obtained. Pelvic arteriography revealed a 2.0×1.5 cm cavity arising from the right cavernosal artery with subsequent filling of the surrounding cavernosal tissues (Figure 1). Selective embolization was offered by a radiologist and after patient consented, selective embolization of the right internal pudendal artery by a No.5 French Cobra-II catheter and gel foam as the embolizing agent was performed. Complete detumescence was noted after 2 days; normal erectile function returned after a week. No complication was noted after 6 months of follow-up.

Case 2

A 33-year-old male developed a painless partial erection 2 days after being struck in the perineum by an iron rod at work. He was admitted to our hospital after a week. Physical examination revealed a non-tender penis with approximately 60% rigidity involving only the corpora cavernosa with some perineal ecchymosis. No blood gas studies were obtained. Pelvic arteriography revealed a 1×1.5 cm cavity arising from both of the cavernosal arteries (Figure 2). Selective embolization was offered by a radiologist and

after patient consented, selective embolization of both internal pudendal arteries by a No.5 French Cobra-II catheter and gel foam as the embolizing agent was performed. Both of the internal pudendal arteries were occluded in their distal parts (Figure 3 and 4). After 2 days complete detumescence was noted. Complete erectile function also returned after 2 months. No complication except one episode of hematospermia in the first ejaculation after trauma was noted in the patient after a 6-month follow-up.

Case 3

A 23-year-old male developed a painless partial erection one week after his perineum was struck against the corner of a swimming pool and was admitted to our hospital after a week. He had a non-tender painless penis with approximately 50% rigidity, only involving the corpora cavernosa in the physical exam. Due to high probability of high flow priapism, a pelvic angiography without any other diagnostic tests was performed. A 1×1 cm cavity arising from the right cavernosal artery was noted in the pelvic angiography (Figure 5). Selective embolization of the right internal pudendal artery by a No.5 French Cobra-II catheter and a soft platinum coil (Cook) as the embolizing agent was performed (Figure 6). Detumescence was noted immediately and after 2 months, complete erectile function was also observed. No complication was noted after 40 months of follow-up.

Case 4

A 35-year-old male developed a painless partial

Table 1. Information summary of five patients with high-flow priapism and pudendal artery embolization.

Patient no.	Age(yr)	History	The Time from trauma to priapism	Duration of priapism	Embolizing material	Unilateral or bilateral pudendal art. embolization	Time to detumescence after embolization	Duration to restoration of erectile function	Erectile function	Follow-up	Complications
1	34	None	-	One year	Gel foam	Unilateral	2 days	1 week	complete	6 months	none
2	33	injury	2 days	1 week	Gel foam	Bilateral	2 days	2 month	complete	6 months	An episode of hematospermia
3	23	injury	1 week	2 weeks	Coil	Unilateral	Immediately	2 month	complete	40 months	none
4	35	injury	1 days	1 week	PVA	Unilateral	In recovery room	1 week	complete	29 months	none
5	35	injury	2 days	1 week	Coil	Unilateral	Immediately	-	-	-	-

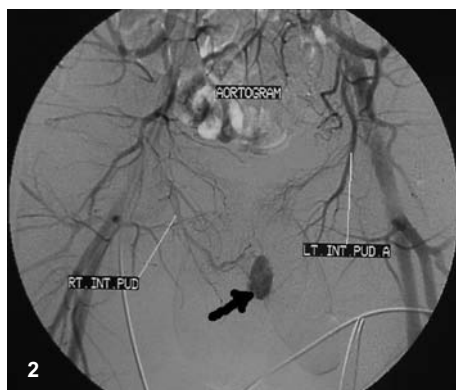
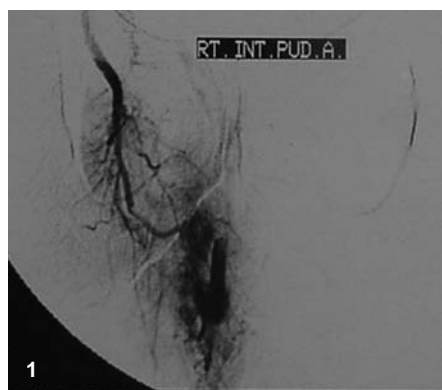


Fig 1. Right internal Pudendal artery injection, shows 2x1.5 cm cavity arising from right cavernosal artery with filling of surrounding cavernosal tissue

Fig 2. Aortogram showed arterio-cavernous fistula (arrow) which proved to have feeding arteries from both internal pudendal arteries in selective catheterization.

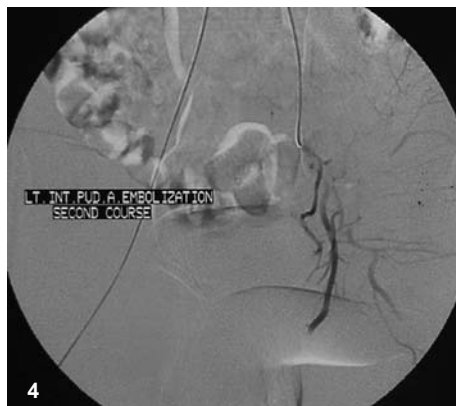
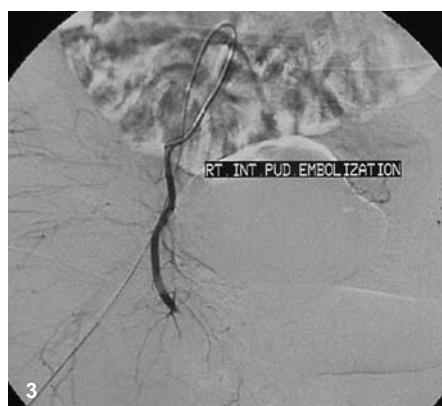
Fig 3,4. Both internal pudendal arteries are embolized with gel foam, no sign of residual arteriovenous fistula noted.

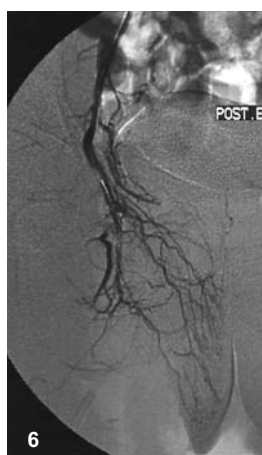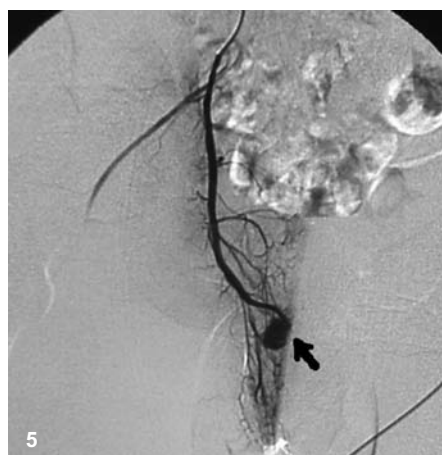


Fig 5. Right internal pudendal artery injection shows arterio-cavernous fistula (arrow)

Fig 6. No residual fistula noted in post coil embolization.

erection one day after blunt trauma to his perineum in an assault. He was admitted to our hospital a week later. Physical examination revealed a non-tender penis with approximately 60% rigidity involving only the corpora cavernosa, and some perineal ecchymosis. Pelvic angiography without any other diagnostic tests was performed and a 1.5x1 cm cavity arising from the left cavernosal artery was noted. In the procedure, the left pudendal artery was occluded in its distal portion with polyvinyl alcohol microspheres (300-500 μ) (Cook), using a No.5 French Cobra-II catheter. No residual cavity was noted post-embolization and complete detumescence was seen in the recovery

room. One week after the procedure, the patient recovered normal sexual function with no complications in the 40-month follow-up.

Case 5

A 35-year-old male presented with partial painless erection 2 days after a blunt perineal injury at work and was admitted to our hospital a week later. Physical examination showed some perineal ecchymosis and a non-tender penis with approximately 60% rigidity only involving the corpora cavernosa. Pelvic angiography without any other diagnostic tests was performed and a 1x1 cm cavity arising from the right

cavernosal artery was noted. After getting the patient's consent, we performed a selective embolization of the right internal pudendal artery with a No.5 French Cobra-II catheter, and a soft platinum coil (cook) as the embolizing agent. No cavity was noted in the post-embolization films. Detumescence was noted immediately, but the patient did not consent to long term follow-up.

Discussion

Priapism arises from an imbalance between the arterial blood supply of the penis and the venous return. Hauri et al. distinguished two variants, namely a non-ischemic high-flow priapism due to abnormalities of the arterial blood supply, and a low-flow priapism due to abnormalities of the venous return. High-flow priapism is a very rare form of priapism.⁷ Reviews of the literature have revealed the transcatheter embolization with autologous clots (Kim et al., 1996), microcoils (Kerlan et al., 1998) or gelatin sponges (Cohen et al. 1996) and P.V.A. (Goktas et al., 1996) of lacerated arterial branch as the most effective therapy with optimal long-term results regarding erectile function in children and adults. It is also known that the success rate in shunt operations (Parent et al. 1993), open surgery (Shapiro and Berger, 1997), and intracavernosal applications of pharmacologic agents (Dewan et al., 1994) is low.³

The aim of therapy is obviously to close the arterial fistula without jeopardizing the erectile function. Complications of embolization of the internal pudendal artery include penile gangrene, persistent impotence, gluteal ischemia, purulent cavernositis, recurrent priapism, perineal abscess, and migration of em-

bolizing agent. We did not use microcatheters for super-selective occlusion of arteriovenous fistula feeder artery but we used a No.5 French Cobra-II catheter for the occlusion of the pudendal artery at its proximal part. We did not note any complications of this embolization procedure in our patients. We also had no recurrences in our patients compared to the study by Ciampalini et al that had 30% recurrence rate with nine cases.⁶ The median recovery time in the review of Touge et al. was 60 days after embolization with absorbable material and 90 days with non-absorbable material. Maximum recovery time in our patients was two months. But due to the small number of patients, further studies are needed to confirm these findings.

References:

1. Goto T, Yagi S, Matsushita S, Uchida Y, Kawahara M, Ohi Y et al. Diagnosis and treatment of priapism: experience with 5 cases. *Urology* 1999; 53:1019-1023.
2. Bertino RE, Castaneda F, Brady TM. Interventional therapy in the treatment of impotence and high-flow priapism. In: Castaneda-Zuniga WR, *Interventional Radiology*; 3rd ed, Baltimore: William & Wilkins 1997; 309-310.
3. Volkmer BG, Nessler T, Kufer R. High flow priapism: a combined interventional approach with angiography and color Doppler. *Ultrasound In Med & Biol.* 2002; 28: 165-169.
4. Ankem MK, Gazi MA, Ferlise VJ. High flow priapism: a novel way of lateralization of the lesion in radiologically unapparent cases. *Urology.* 2001;57:800 iv-800vi
5. Kawakami M, Minogawa T, Inoue H. Successful treatment of arterial priapism with radiological selective transcatheter embolization of the internal pudendal artery. *Urology* 2003; 61: 645xvi-645xvii.
6. Ciampalini S, Savoca G, Buttazzi L. High-flow priapism: treatment and long term follow-up. *Urology* 2002; 59:110-113.
7. Touge H, Watanabe T, Fujinaga T. Post-traumatic high-flow priapism: a case report. *Int J Urol.* 1999; 6:623-626.