

COMPARISON OF THE EFFECTS OF VARICOCELECTOMY ON THE SPERMIOGRAM OF PATIENTS WITH SUBCLINICAL VERSUS CLINICAL VARICOCELE

A. A. Ketabchi^{*1}, M. Ahmadinejad² and M. Ehsan³

1) Department of Urology, No. 2 Hospital, Kerman University of Medical Sciences, Kerman, Iran

2) Department of Molecular Genetics, Medical Research Center, Kerman University of Medical Sciences, Kerman, Iran

3) Department of Radiology, No. 1 Hospital, Kerman University of Medical Sciences, Kerman, Iran

Abstract- Many studies with different results have been conducted regarding varicocelectomy in patients with subclinical varicocele and its effect on semen parameters. This clinical trial was aimed at assessing the effect of varicocelectomy on the spermogram of patients with subclinical varicocele. A total of 142 patients with varicocele (79 clinical and 63 subclinical) took part in the study. Two spermograms were taken from the patients, one before and the other 3 to 6 months after varicocelectomy. Although the spermogram results of the patients with subclinical varicocele did not show a significant change after operation, the spermogram of the patients with clinical varicocele improved significantly ($P < 0.05$). In the patients with subclinical varicocele, bilateral and right varicoceles were more prevalent compared to group with clinical varicocele ($P < 0.05$). In addition, incidence of secondary infertility in the patients with subclinical varicoceles was higher in comparison with the other group ($P < 0.05$). Consideration of the ineffectiveness of operation in patients with subclinical varicoceles and considerable clinical differences between these patients and patients with clinical varicocele, we recommend avoiding surgery in these patients unless no other causes of semen abnormality, such as hormonal abnormality, internal urogenital abnormality or immunological disorders can be found.

Acta Medica Iranica, 43(4): 249-252; 2005

Key words: Clinical varicocele, subclinical varicocele, infertility, spermogram

INTRODUCTION

Varicocele is the dilatation, elongation and abnormal kinking of spermatic veins of the pampiniform plexus of the testis (1). In the first century AD, Celsius, the Greek physician, hinted at this disease for the first time by mentioning testicle atrophy (2). Barwell in 1885, Bennett in 1889, and Macomber in 1929 have mentioned the effect of

varicocele operation on the improvement of semen quality (3).

Varicocele is the most common cause of infertility in men, which can be treated by operation. It is estimated that 15% of men suffer from varicocele (4); it has been reported in 17% of fertile and about 39% of infertile men (5). The most common abnormality in the spermogram of individuals who are suffering from varicocele is a decrease of sperm motility, which can be seen in 90% of patients (6). In addition, abnormality in the shape of sperm cells of these individuals is very common. Currently no acceptable relation between grade of varicocele, pathology of testicles and the

Received: 3 Jan. 2003, Revised: 5 Jan. 2003, Accepted: 20 Dec. 2004

*** Corresponding Author:**

A. A. Ketabchi, Department of Urology, No. 2 Hospital, School of Medicine, Kerman University of Medical Sciences, Kerman, Iran
Tel: +98 341 2115780-8, Fax: +98 341 215803
E-mail: mrketabchi@yahoo.com

Varicolectomy for subclinical varicoceles

spermiogram abnormality is known. Whenever clinical varicocele is undetectable and in the regular scrotal sonography three dilated veins, at least one of which has a diameter of more than three millimeters, are found, the patient is classified as having subclinical varicocele (1, 7). The incidence of single or double-sided subclinical varicocele in idiopathic infertile individuals is 90% and 54%, respectively (6). Subclinical varicocele is detectable by different methods such as color Doppler sonography, regular sonography, scrotal thermography and scrotal scanning (8-10). The most common reason for surgery in clinical varicocele is infertility, as long as the patient's wife has been gynecologically checked and confirmed to be fertile and there is no other reason for infertility (6).

Many studies have been conducted with different results regarding varicolectomy on patients with subclinical varicocele and its effect on semen parameters. In this study, we set out to compare semen parameters of patients with clinical and subclinical varicocele before and after varicolectomy, and determine whether surgery is necessary for patients with subclinical varicocele.

MATERIALS AND METHODS

Our clinical trial was carried out in the urology clinics of the hospitals of Kerman Medical Sciences University from 1996 to 1999. During this period of time all patients with abnormal spermiogram referred to the urology clinics were evaluated and cases with varicocele were included in the study. Clinical varicocele was classified by the Dubin system (11):

Grade I: when the pampiniform veins can be felt while the patient is standing and performing the Valsalva maneuver.

Grade II: when the pampiniform veins are visible while the patient is standing and performing the Valsalva maneuver.

Grade III: when the pampiniform veins are visible while the patient is standing without performing the Valsalva maneuver.

Transscrotal sonography and detecting three dilated veins, at least one of them having a diameter of more than three millimeters, defined subclinical

varicocele. Cases with problems such as recurrence of varicocele after operation or testicular atrophy, which could affect spermiogram, were excluded from the study. Other reasons for exclusion were refusal to undergo spermanalysis, having normal spermiograms and having any underlying disorder with known effect on semen parameters.

Finally, 142 patients (79 with clinical and 63 with subclinical varicocele) were selected. After obtaining informed consent and performing clinical evaluation, for each patient a questionnaire regarding demographic features, marital situation, type of varicocele, genital evaluation and type of infertility (primary or secondary) was filled out. The first spermiogram was taken from the patients before operation; the second spermiogram was taken 3 to 6 months after retroperitoneal varicolectomy (high ligation of the internal spermatic vein). To ensure the accuracy of the study, a single medical technologist performed all laboratory experiments and a single urologist performed all operations. The spermiogram results before and after the operation were compared among individuals of each group. We compared the results of the study using the Epi-6 software, through the *t* test program.

RESULTS

A total of 142 men, suffering from varicocele, were selected. Their mean age was 28.1 ± 4.3 years. The smallest age group belonged to those who were 41 years and older, making up 6.3% of patients with clinical varicocele and 4.7% of patients with subclinical varicocele (Fig. 1). The effected side in the patients is shown in figure 2.

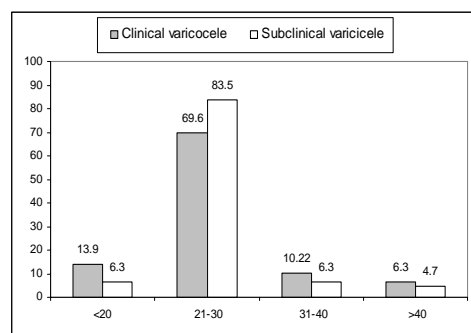


Fig. 1. Age distribution of patients.

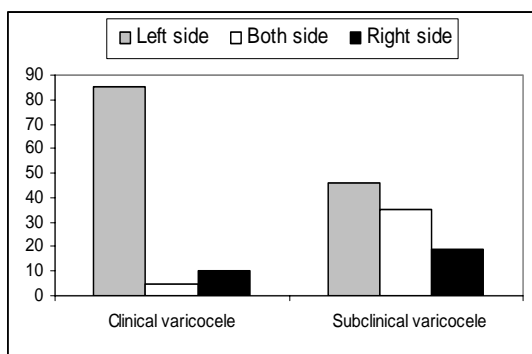


Fig. 2. Side Distribution of varicocele

In patients with clinical varicocele, 18 (23%) had grade I, 37 (47%) had grade II and 24 (24%) had grade III varicocele.

Among the men who were married, the period of time from marriage to the first referral to the urology clinic regarding infertility was 5.2 ± 2.4 years in patients with subclinical and 1.9 ± 2.1 years in patients with clinical varicocele, with a significant P value of < 0.001 . In patients with clinical varicocele, 58.9% had primary and 12.2% had secondary infertility, while the remaining 28.9% were single. Among the patients with subclinical varicocele, 5.6% had primary infertility, 48.2% had secondary infertility and the remaining 46.2% were single.

Comparison of spermiogram parameters before and after varicocelectomy between individuals of each group is shown in table I.

Significant improvements appeared in sperm count and in motility parameters after operation only in the clinical groups.

The main complications after operation in both groups were testicular pain and sensitivity in 13 patients (10 with clinical varicocele and 3 with subclinical symptoms), mild hydrocele in 10 (3 with clinical and 7 subclinical symptoms), testicular atrophy in 2 (both with subclinical varicocele) and recurrence of varicocele in 6 (2 cases in the clinical group and 4 cases in the subclinical group).

DISCUSSION

Although varicocele is an important and common cause of men's infertility, fortunately, clinical varicocele is well treatable, and the best treatment of it is agreed by most researchers to be surgery. The controversial subject is management of subclinical varicoceles. Most of these patients are referred to urology clinics because of infertility after some paraclinical diagnosis such as spermiogram and/or sonogram abnormality. Many different opinions have been stated in various papers regarding the results of surgical operation on patients with subclinical varicocele. For instance, Bsati and Masabni did not have positive results after performing varicocelectomy on patients with subclinical varicocele (4). In contrast, Pierik *et al.* in their

Table 1. Comparing the spermiogram parameters between two group of patients having clinical and subclinical varicocele before and after varicocelectomy*

| Sperm parameters | Groups† | Values before operation | Values after operation | P Value |
|-----------------------------------------|---------|-------------------------|------------------------|----------|
| Sperm count (million per ml) | A-I | 49.85 ± 24.43 | 79.55 ± 18.75 | < 0.05 |
| | A-II | 51.8 ± 34.4 | 70.1 ± 17.3 | < 0.05 |
| | A-III | 44.1 ± 31.4 | 66.35 ± 19.15 | < 0.05 |
| | B | 59.2 ± 15.6 | 63.5 ± 14.8 | NS |
| Percentage of motile sperms | A-I | 53.05 ± 22.95 | 60.95 ± 22.05 | NS |
| | A-II | 46.25 ± 20.75 | 66.4 ± 20.2 | < 0.05 |
| | A-III | 42.6 ± 15.4 | 78.55 ± 13.85 | < 0.05 |
| | B | 60.7 ± 12.1 | 65.4 ± 9.8 | NS |
| Percent of sperm with normal morphology | A-I | 61.85 ± 20.55 | 56.25 ± 12.45 | NS |
| | A-II | 54.85 ± 19.15 | 57.6 ± 19 | NS |
| | A-III | 51.15 ± 20.35 | 55.15 ± 19.85 | NS |
| | B | 39 ± 23.2 | 43 ± 18.9 | NS |

Abbreviation: NS, Non-significant.

* Data are given as mean \pm SD.

†A-I to A-III, patients with clinical varicocele (three grades); B, patients with subclinical varicocele.

Varicolectomy for subclinical varicoceles

research on patients with clinical and subclinical varicocele showed that surgical operation had the same positive results regardless of the type of the disease (10). Unal *et al.* compared two methods of treatment in patients with subclinical varicocele by prescribing clomiphene to one group and performing varicolectomy on another group. They showed that the spermogram parameters improved in both groups, with no significant difference between the two methods of treatment (12). Most of these researchers selected their patients based on infertility and semen abnormality. The last researchers even selected their patients among those who had subclinical varicocele of the left side. In our study, we selected our patients based on the diagnosis of varicocele only, without paying attention to the fertility status and the affected side. This may explain the significant difference of our results with the above researchers.

In our study, bilateral or right sided varicoceles were more common in the subclinical varicocele group compared to the clinical group and baseline spermograms of subclinical patients were less abnormal than those of the patients with clinical varicocele. Even a significant percentage of them had fertility backgrounds (secondary infertility). Considering our results and the results of previous researchers, it can be concluded that underlying mechanism and pathogenesis of left sided subclinical varicoceles and those who had severe spermogram abnormality (same as those who had clinical varicocele) are similar to clinical varicocele, for which surgery may give better results. In our study, most of the patients were affected on the right or both sides; hence, it seems that other mechanisms may have affected their sperm parameters.

Since in our study varicolectomy did not have favorable results in patients with subclinical varicocele, we recommend avoiding surgery in these patients unless no other causes of semen abnormality, such as hormonal abnormality, internal urogenital abnormality or immunological disorders can be found. We hope that further research on the effects of different medical and surgical treatments for idiopathic subclinical varicoceles guide us in

choosing more proper treatment methods in the future.

REFERENCES

1. Granados Loarca EA, Alcahe Gallimidi VR, Escobar Monzon C, Echevarria Solis JC, de Leon Lopez H, Echevarria Reyes J. [The assessment of varicocele by ultrasound]. *Actas Urol Esp.* 1999 Jul-Aug; 23(7):579-582.
2. Pryor JL, Howards SS. Varicocele. *Urol Clin North Am.* 1987 Aug; 14(3):499-513.
3. La Nasa JA Jr, Lewis RW. Varicocele and its surgical management. *Urol Clin North Am.* 1987 Feb; 14(1):127-136.
4. Bsath FA, Masabni R. Effectiveness of varicolectomy in varicoceles diagnosed by physical examination versus Doppler studies. *Fertil Steril.* 1988 Aug;50(2):321-323.
5. Li H, Dubocq F, Jiang Y, Tiguert R, Gheiler EL, Dhabuwala CB. Effect of surgically induced varicocele on testicular blood flow and Sertoli cell function. *Urology.* 1999 Jun;53(6):1258-1262.
6. Rajfer, J; MD Congenital Anomalies of the Testis and Scrotum. pages 2172 - 2209.
7. Zini A, Buckspan M, Berardinucci D, Jarvi K. Loss of left testicular volume in men with clinical left varicocele: correlation with grade of varicocele. *Arch Androl.* 1998 Jul-Aug;41(1):37-41.
8. Gold RH, Ehrlich RM, Samuels B, Dowdy A, Young RT. Scrotal thermography. *Radiology.* 1977 Jan; 122(1):129-132.
9. Paz A, Melloul M. Comparison of radionuclide scrotal blood-pool index versus gonadal venography in the diagnosis of varicocele. *J Nucl Med.* 1998 Jun; 39(6):1069-1074.
10. Pierik FH, Vreeburg JT, Stijnen T, van Rooijen JH, Dohle GR, Lameris JS, Timmers T, Weber RF. Improvement of sperm count and motility after ligation of varicoceles detected with colour Doppler ultrasonography. *Int J Androl.* 1998 Oct;21(5):256-260.
11. Dubin L, Amelar RD. Varicolectomy: 986 cases in a twelve-year study. *Urology.* 1977 Nov; 10(5):446-449.
12. Unal D, Yeni E, Verit A, Karatas OF. Clomiphene citrate versus varicolectomy in treatment of subclinical varicocele: a prospective randomized study. *Int J Urol.* 2001 May; 8(5):227-230.