

A Histochemical Study of the Origin Regions of the Triceps Muscle of the Sparrow (*Passer domesticus*)

Fatime GEYİKOĞLU

Department of Biology, Faculty of Arts and Sciences, Atatürk University, 25240, Erzurum-TURKEY

Abdullah ÖZKARAL

Division of Histology and Embryology, Medical Faculty, Atatürk University, 25240, Erzurum-TURKEY

Received: 25.02.1999

Abstract: The muscle fibers in the origin regions of the triceps muscle of *Passer domesticus* were characterized histochemically on the basis of their myofibrillar adenosine triphosphatase (mATPase) activity after acidic and alkaline preincubations. Muscle fibers were identified as type II (alkaline-stable/acid-labile mATPase activity) and type III (alkaline-stable/acid-stable mATPase activity). The number of type II fibers was higher in the muscle studied (83%) and this was found to be significant.

Key Words: *Passer domesticus*, Aves, Triceps muscle, Histochemistry.

Serçe (*Passer domesticus*) Triceps Kasının Orijin Bölgelerinde Histokimyasal Bir Çalışma

Özet: Serçe triceps kasının orijin bölgelerindeki kas lifleri, asid ve alkaline preinkübasyonlarından sonra uygulanan, miyofibriller adenosin trifosfataz (mATPaz) aktivitesine dayanılarak karakterize edilmiştir. Kas lifleri, tip II (alkaliye-dayanıklı / aside dayanıksız mATPaz aktivitesi) ve tip III (alkaliye-dayanıklı / aside dayanıklı mATPaz aktivitesi) olarak tanımlanmıştır. Çalıştığımız kasta tip II lif sayısının çokluğu (83%) da dikkat çekici bulunmuştur.

Anahtar Sözcükler: Serçe, Kuş, Triceps kası, Histokimya.

Introduction

The characterization of skeletal muscle fiber types is important for functional and progression studies, as fiber type specifications are observed in muscles due to several experimental, ontogenetical and pathological changes (1).

The terminology of fiber types in skeletal muscles is complicated (2). Depending on physiological and morphological differences (3-5), stretching or twitching and tonic fibers are distinguished (6). The relationship between the structure and function of bird muscle fibres became more explicit upon the definition of metabolic differences immuno-histochemically (7) and histochemically (8). Thus, by means of oxidative enzymes, red fibers in the pectoral muscle sparrow (*Passer domesticus*) (9), and red and white fibers in large pectoral muscle, supracoracoid and posterior latissimus dorsi muscles of Japanese quail (*Coturnix coturnix japonica*) were distinguished (10). Through common histochemical methods such as myofibrillar adenosine triphosphatase (8), fast-twitch and slow-tonic fiber types

were discovered (6) in the pectoral muscle of the Emu (*Dromaius novaehollandiae*). Beside these fiber types, an intermediate fiber type was discovered in certain muscles in the pectoral extension of pigeons and fowl (11) as well as in gastrocnemius muscles (12). As the mATPase reaction, pre-treated by acids, contributed to the new classification (13), these fibers were distinguished and named respectively as: fast-twitch glycolytic white and fast-twitch oxidative and glycolytic (red and intermediate) (14), and slow-tonic (2) in the pectoral muscles of birds; and as type I, type II, and type III in the skeleton muscles and superior oblique muscles of mature birds (15), determined by means of mATPase applied after acid and alkaline preincubations (2, 15). While a fast fiber (type II) indicated high mATPase activity after alkaline preincubation, a slow-twitch fiber (type I) showed an opposite reaction (1, 15). As regards slow-tonic fibers (type III), they were found to be resistant to both preincubations (15) and were coloured from a low (11) to medium level (1). In some cases these fibers were dark coloured (2-6). In addition to these histochemical

colouring reactions, many structural and physiological distinctions between tonic and twitch fibers have been reported (16-19) Slow-twitch and slow-tonic fibers were innervated multiplicatively by grape-like motor-ending plaques (1, 8), whereas fast-twitch fibers were innervated by plate-type motor-ending plaques (2,20). Each strengthening stretch was slow and long-term whereas fast-stretch was fast and short-term (5, 18, 19).

The aim of this study was to determine the fiber type composition in the origin area of the sparrow triceps muscle and also to investigate whether or not slow-tonic fibers (2), which have been reported to exist rarely in bird muscles, and slow-twitch fibers, whose existence has been suggested, were present in the muscle studied.

Material and Method

The triceps muscles (of which the origin was on the scapula and humerus and the insertion was on the ulna) of ten sparrows (*Passer domesticus*) (21-23) were removed by means of a dissection microscope and 12-15 μ m thick serial transverse sections were taken at -20°C in cryostat from the origin areas. On these sections, the mATPase method was applied (24) at 25°C (25) at pH 4.25 for 5 minutes (2) and at pH 10.4 for 15 minutes (2,6) after acid and alkaline preincubations at 40°C (25) in order to determine the fiber types. The fiber type and percentage evaluation (15) were determined using a method similar to that recorded by other researchers (26, 27).

Results and Discussion

In this study, two fiber types were distinguished in the origin areas of the sparrow triceps muscle (type II and type III) (Figures 1 and 2).

A similar reaction was observed in the pigeon triceps muscle in preincubations at the same temperatures (24). Therefore, it is reported that the recommended temperatures and pH values serve only as a general guide and the optimum pH and temperature have to be determined by the researcher (24, 28). The results of the present study showed that fibers of type III (slow-tonic) proved resistant to acid and alkaline preincubations. Similar findings were also reported by Sohail and Sickles (1986). Although a dark colouring in these fibers with mATPase applied after acid and alkaline preincubations has been reported (2,6), medium-level colouring reactions similar to those recorded by Hikida (1987) were observed in our studies. At the same time, irresistance of type III fibers to alkaline as in the type I fibers of mammals (2) has been reported, and in mature bird skeleton muscles, fibers reacting in the same way were named slow-twitch fibers (29, 30). Therefore, in our study, the terminology of Sohail and Sickles (1986) was preferred as it distinguishes two fiber types (slow-tonic and slow-twitch) and the term type III is used for fibers that are also resistant to alkaline. However, slow-twitch fibers giving reactions similar to those of mammal type I fibers have not been encountered in the origin areas of sparrow triceps muscles (31). These fibres, whose existence was uncertain (6), were still thought to

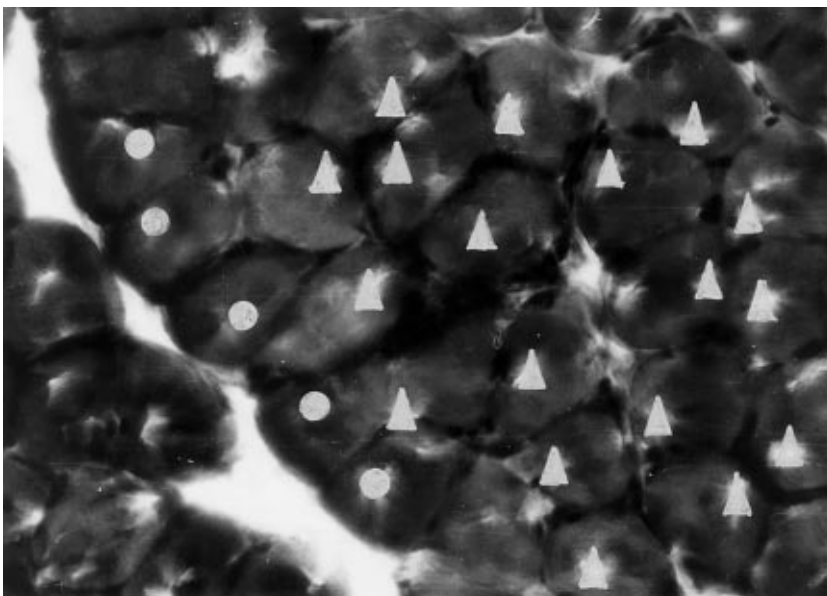


Figure 1. Fiber types on the origin regions of the triceps muscle of the sparrow. Filled circles: type III. Filled triangles: type II. mATPase reaction after alkaline preincubation (at pH 10.4). (x 200).

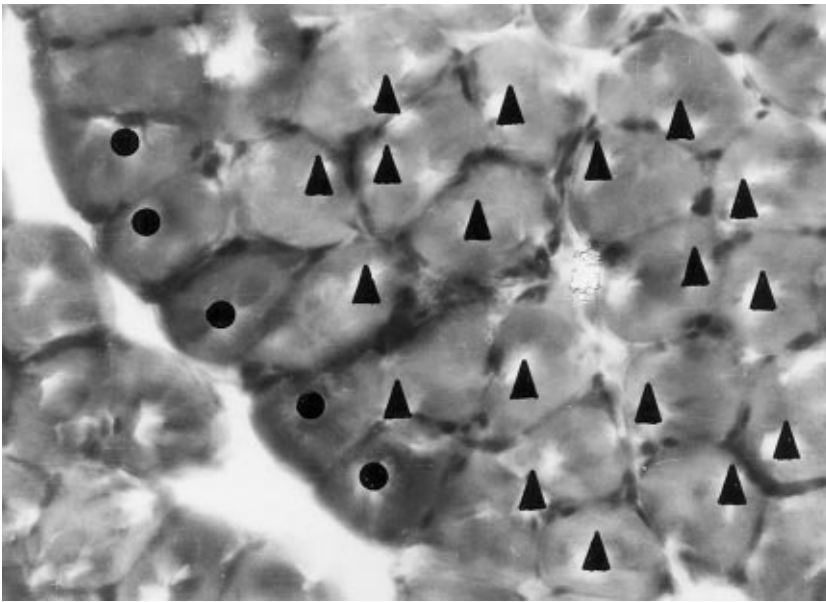


Figure 2. Fiber types on the origin regions of the triceps muscle of the sparrow. Symbols are the same as in Fig.1. mATPase reaction after acid preincubation (at pH 4.25), (x 200).

exist in bird muscles (30, 32, 33) and they have been reported to be more resistant to alkaline than those of mammals (30). In fact, the type III fibers (slow-tonic) we observed in sparrow triceps muscles have not been found in mammal skeleton muscles in general (6). Furthermore, our data showed that these fibers of limited number (17 %) were mainly located around muscle fasciculi. This type has also been reported to exist in small numbers only in deep areas of the pectoral muscles of a few birds (2). When compared with other fiber types, different mATPase reactions in slow-tonic fibers (17) created the impression that they might become specialized for slow and supportive stretches (34-36). Tonic stretches in mammals are also reported to have similar functions (37). A large number of tonic fibers in the pigeon anterior latissimus dorsi muscle reflected postural muscle features (supportive against gravity) (2). Thus, in the sparrow triceps muscle, type III fibers may prove functional in supporting and lifting the shoulders and the wings. However, these fibers have not been detected in the pectoral muscles of many species (2).

Type II fibers are abundant (83 %) in the sparrow triceps muscle. This is consistent with the strength needed for flying, as recorded by Maier (1983). Like the

mammal type II fibers (25), in our study, these fibers were also strongly coloured by mATPase with alkaline preincubation and lightly coloured by acid mATPase with acid preincubation. Although determined in small numbers, fibers coloured to a medium level by alkaline preincubation were detected. However, in bird muscles, type II fibers (fast-twitch glycolytic and fast-twitch oxidative-glycolytic) distinguished by mATPase with alkaline and acid preincubation (pH 4.25 and pH 10.4) (2) were not detected in sparrow triceps muscles studied under the same circumstances, and therefore only type II classification was done (15).

Type III fibers (tonic) (2), reported to exist rarely in bird muscles, were detected in small numbers in the deep regions of the sparrow triceps muscles which we studied. However, slow-tonic fibers, whose existence was uncertain (6), were not discovered. A number of type II fibers may provide strength for the wings during flight. Movements of the wing during the upstroke in birds capable of powered flight are more complex than those of the downstroke (38). In this case, we are of the opinion that further physiological study must be conducted for the clarification of this subject.

References

1. Hikida, R.S., Quantitative Ultrastructure of Histochemically Identified Avian Skeletal Muscle Fiber Types. *Anat-Rec.*, 218, pp 128-135, 1987.
2. Rosser, B.W.C. and George, J.C., The Avian Pectoralis: Histochemical Characterization and Distribution of Muscle Fiber Types. *Can. J. Zool.*, 64, pp.1174-1185, 1985.

3. Hess, A., Vertebrate Slow Muscle Fibers. *Physiol. Rev.*, 50, pp. 40-62, 1970.
4. Hikida, R.S. and Bock, W.J., Analysis of Fiber Types in the Pigeon's Metapatagialis Muscle. 1.Histochemistry, End plates and Ultrastructure. *Tissue Cell*, 6, pp.411-430, 1974.
5. Moore, G., Johnston I.A. and Goldspink, G., The pCa-tension Characteristics of Single Skinned Fibers Isolated from the Anterior and Posterior Latissimus Dorsi Muscles of Chicken. *J. Exp. Biol.*, 105, pp. 411-416, 1983.
6. Rosser, B.W.C. and George, J.C., Some Histochemical Properties of the Fiber Types in the Pectoralis Muscle of an Emu (*Dromaius novaehollandiae*). *Anat. Rec.*, 209, pp. 301-305, 1984.
7. Oishi, Y., Hirotooshi, I., Kokachi, T. and Hisahiro, M., Immunohistochemical Classification of Fiber Types in Rat. Skeletal Muscle. *Nat. Sci.*, 0(46), pp.121-126, 1997.
8. Torella, J.R., Fouces, V., Palomeque, J. and Viscor, G., Innervation Distribution Pattern, Nerve Ending Structure, and Fiber Types in Pigeon Skeletal Muscle. *Anat. Rec.*, 237, pp.178-186, 1993.
9. Cherian, K.M. and George, J.C., Histochemical Demonstration of Dihydropyruvate Dehydrogenase Activity in the Red and White fibres of the Avian Pectoralis. *J. Anim. Morphol. Physiol.*, 13 (1/2), pp.210-213, 1967.
10. Boesiger, B., Comparasion Morphologie, Biometrique et Histochemie des Fibres Musculaires et de Leurs Terminaisons Nerveuss Motrices de Differents Muscles de la Caille Japonaise, *Coturnix coturnix japonica*. *Acta Anat.*, 71 (2), pp.274-310, 1969.
11. Nene, R.V., and George, J.C., A Histophysiological Study of Some Muscles of the Avian Pectoral Appendage. *Pavo Indian J.Ornithol.*, 3 (1), pp. 35-46, 1966.
12. Chandra-Bose, D.A., Cellular Organization and Distribution of Fat and Succinic Dehydrogenase in the Gastrocnemius Muscles of a Few Birds. *Pavo Indian J. Ornithol.*, 5 (1/2), pp.13-18, 1968.
13. Spurway, N.C., Objective Characterization of Cells in terms of Microscopical Parameters: An Example from Muscle Histochemistry. *J. Histochem.*, 13/2, pp.269-317, 1981.
14. Gille, U., Franz-Viktor, S. and Sylvia, K., Posthatching Myofiber Development in the M.Pectoralis of White Pekin Ducks. *Anat. Rec.*, 250(2), pp.154-158, 1998.
15. Sohail, G.S. and Sickles, D.W., Embryonic Differentiation of Fibre Types in Normal, Paralysed and Aneural Avian Superior Oblique Muscle. *J.Embryol. Exp. Morphol.*, 96, pp. 79-97, 1986.
16. Ashmore, C.R., Kikuchi, T. and Doerr, L., Some Observations on the Innervation Patterns of Different Fiber Types of Chick Muscle. *Exp. Neurol.*, 58, pp. 272-284, 1978.
17. Rouaud, T. and Toutant, J.P., Histochemical Properties and Innervation Patterns of Fast and Slow-Tonic Fibre Types of the Anterior Latissimus Dorsi Muscle of the Chick. *J. Histochem.*, 14, pp. 415-428, 1982.
18. Morgan, D.L. and Proske, U., Vertebrate Slow Muscle: Its Structure, Pattern of Innervation and Mechanical Properties. *Physiol. Rev.*, 64, pp.103-169, 1984.
19. Johnston, I.A., Sustained Force Development: Specializations and Variations Among the Vertebrates. *J. Exp. Biol.*, 115, pp. 239-251, 1985.
20. Bourgeois, J.P. and Toutant, M., Innervation of Avian Latissimus Dorsi Muscles and Axonal Outgrowth Pattern in the Posterior Latissimus Dorsi Motor Nerve During Embryonic Development. *J. Comp. Neurol.*, 208, pp. 1-15, 1982.
21. Kuenthal, W., Leitfaden für-das Zoologische Praktikum. Verlag Von Gustow Fischer, Jena, pp. 354, 1931.
22. Hatiboğlu, M.T., Anatomi ve Fizyoloji. Hatiboğlu Basım ve Yayım Ltd. Şti., Ankara, s.283,1998.
23. Grzimek, B., Meise, W., Niethamer, G., Steinbacher, J. and Thenius, E., Grzimekes Tierleben Enzyklopadie des Tierreiches. Kindler Verlag AG, Zürich, pp. 564, 1968.
24. Bancroft, S.D. and Stevens, A., Theory and Practice of Histological Techniques. Churchill Livingstone, Edinburgh (2 nd ed.), pp. 662, 1982.
25. Fouces, V., Torella, J.R., Palameque, J. and Viscor, G., A Histochemical ATPase Method for the Demonstration of the Muscle Capillary Network. *J. Histochem. Cytochem.*, 41/2, pp. 283-289, 1993.
26. Hooper, A.C.B., Length, Diameter and Number of Ageing Skeletal Muscle Fibres. *Gerontology*. pp. 121-126, 1981.
27. Armstrong, R.B. and Phelps, R.O., Muscle Fiber Type of Composition of the Rat Hindlimb. *Am. J. Anat.*, 171, pp. 259-272, 1984.
28. Guth, L. and Samaha, F.J., Procedure for the Histochemical Demonstration of Actomyosin ATPase. *Exp.Neurol.*, 28,pp. 365-367, 1970.
29. Toutant, J.P., Rouaud, T. and Le Douarin, G.H., Histochemical Properties of the Biventer Cervicis Muscle of the Chick: A Relationship between Multiple Innervation and Slow-tonic Fibre Types. *J.Histochem.*, 13, pp.481-493, 1981.
30. Barnard, E.A., Lyles, J.M. and Pizzey, J.a., Fibre Types in Chicken Skeletal Muscles and Their Changes in Muscular Dystrophy. *J.Physiol. (Lond.)*, 331, pp.333-354, 1982.
31. Maier, A., Differences in Muscle Spindle Structure Between Pigeon Muscles Used in Aerial and Terrestrial Locomotion-. *Am. J.Anat.*, 168, pp.27-36, 1983.

32. Pierobon-Bormioli, S., Sartore, S., Vitadello, M. and Sehiaffino, S., "Slow" Myosins in Vertebrate Skeletal Muscle J. Cell Biol., 85, pp. 672-681, 1980.
33. Meyers, R.A., Anatomy and Histochemistry of Spread-Wing Posture in Birds.I.Wing Drying Posture in the Double-Crested Cormorant, *Phalacrocorax auritus* .J.Morphol., 233(1), pp.67-76, 1997.
34. Suzuki, A., Tsuchiya, T. and Tamate, H., Histochemical Properties of Myofiber Types in Thigh Muscles of the Chicken. Acta Histochem. Cytochem., 15, pp. 362-371, 1982.
35. Simpson, S.F., The Distribution of Tonic and Twitch Muscle Fibers in the Avian Wing. Am. Zool., 19, pp.929-934, 1979.
36. Putnam, R.W., Gleeson, T.T. and Bennet, A.F., Histochemical Determination of the Fiber Composition of Locomotory Muscles in a Lizard, *Dipsosaurus dorsalis*. J.Exp. Zool., 214, pp.303-309, 1980.
37. Bennett, D.J., De Serres, S.J. and Stein, R.B., Gain of the Triceps Surae Stretch Reflex in Decerebrate and Spinal Cats During Postural and Locomotor Activities. J. Physiol (Lond),. 496(3), pp. 837-850, 1996.
38. Poore, S.O., Sanchez-Haiman, A. and G.E. Goslow, Jr., Wing Upstroke and the Evolution of Flapping Flight. Nature (London), 387(6635), pp.799-802, 1997.