

Lip Posture Following Debonding of Labial Appliances Based on Conventional Profile Photographs

Yossi Abed^a; Gilad Har-Zion^b; Meir Redlich^c

ABSTRACT

Objective: To assess changes in lip posture following debonding of labial appliances on the basis of a new soft tissue analysis performed by computerized tools with the use of conventional non-standardized profile photographic pictures.

Materials and Methods: Profile photographs of 33 patients were taken just before and just after debonding of labial brackets. Pictures were examined twice through custom-made analysis in which Viewbox software was used. The validity of this new analysis was assessed in a preliminary study. A reference line was constructed between the center of the tragus and the outer canthus. The point where this elongated line intersected with the profile was coined nasion-modified and served as the vertex point for angles used to evaluate the prominence of the lips. The final position of the lines was determined when they were tangent to the appropriate landmarks. Analysis of variance (ANOVA) and *t*-tests for paired differences were used.

Results: The reproducibility of this photoanalysis was confirmed in the preliminary study, in that no significant differences were found between measurements ($P < .05$). No statistically significant differences were noted in lip posture between pre-debonding and post-debonding pictures ($P < .05$).

Conclusions: In keeping with the design of this study, soft tissue profile photoanalysis showed that the presence of bonded labial appliances had no effect on lip posture. (*Angle Orthod.* 2009;79;)

KEY WORDS: Photographs; Profile; Lip posture; Analysis

INTRODUCTION

During the past decade, great concern has been drawn toward facial esthetics as one of the major goals of orthodontic treatment.¹⁻³ Consequently, evaluation of proportional facial features is a prerequisite for achieving pleasant facial esthetics. Cephalometric analyses of soft tissues are among the most accurate and reproducible tools for evaluating the profile.⁴⁻⁷ Pro-

file assessment is based on both linear and angular measurements performed on the radiographic image. Norms of desirable esthetic profiles have been established for various populations.⁸⁻¹² Several studies have described profile changes when various orthodontic treatments or orthognathic procedures were completed.¹³⁻¹⁷

The use of cephalometrics is critical in the diagnosis of dental and skeletal malocclusion; it also is used for soft tissue profile analysis. The soft tissue facial profile can be assessed by means of standardized photographic records as well.¹⁸⁻²³ This method requires accurate standardization of the photographic setup; only when this is provided can both angular and linear measurements be calculated.

Establishing a reproducible soft tissue profile analysis based on conventional dental photographs is difficult because it is important to achieve standardization for pictures taken under different photographic conditions. However, conventional nonstandardized photographs of a soft tissue profile offer several advantages, such as no radiation (compared with soft tissue radiograms), availability (performed in-house without the

^a Clinical Instructor, Department of Orthodontics, Hadassah Faculty of Dental Medicine, Hebrew University, Jerusalem, Israel.

^b Teacher in Orthodontics, Department of Orthodontics, Hadassah Faculty of Dental Medicine, Hebrew University, Jerusalem, Israel.

^c Senior Lecturer, Department of Orthodontics, Hadassah Faculty of Dental Medicine, Hebrew University, Jerusalem, Israel.

Corresponding author: Meir Redlich, Department of Orthodontics, Hadassah Faculty of Dental Medicine, Hebrew University, P.O.B. 12272, Jerusalem, Israel 91120 (e-mail: mredlich@zahav.net.il)

Accepted: April 2008. Submitted: March 2008.

© 2009 by The EH Angle Education and Research Foundation, Inc.

need for specific photographic equipment), low expense (the use of standard cameras), and versatility (open and closed lips, semiprofile, and smiling).

To the best of our knowledge, the possible effect of increased lip posture caused by labial attachment had never been investigated. Nevertheless, it is stated that one advantage of lingual orthodontics is that that the brackets do not affect lip posture as labial appliances do.²⁴

Thus, the first aim of this study was to establish an accurate and reproducible photoanalysis of soft tissue profile based on conventional profile photographs. The second purpose of this experiment was to compare upper lip posture before and immediately after debonding of labial appliances, so as to evaluate the effects of bonded labial appliances on lip posture.

MATERIALS AND METHODS

Establishing the Photoanalysis

Facial clinical profile photographs of nine teenagers (five males and four females) undergoing orthodontic treatment with labial appliance Mini Diamond Roth prescription 0.022-inch slot width (Ormco, Orange, Calif) were used. Each patient was photographed twice with a 30-minute interval between pictures. At each time point, two sets of consecutive photographs were taken, and the best picture of the two was chosen.

All photographs were taken with a digital camera (Olympus 620L, Olympus America Inc, Center Valley, Pa) with the high-quality option under nonstandard conditions (the camera was not mounted on a tripod but was hand held by the photographer; the distance from camera to patient was not measured; no special requirements were applied for the head position). The only criterion was that patients were instructed to keep their teeth and lips in light contact. The technical details were as follows: resolution of 144 pixels/inch (DPI) in a true color mode (RGB—24 bits), working size of the file of 3840 kb, picture dimensions of 7.11 w/8.89 h inches (18.06/22.58 cm); the pictures were saved in JPG format with a compression ratio of 19.2 (file size, 200 kb). All pictures were viewed on full screen (1024 × 768 pixels) without distinguishing pixelization.

All pictures were examined by custom-made analysis (photoanalysis model) with the use of commercial cephalometric software (Viewbox, dHal Software, Kifissia, Greece), version 3.0.0.10.²⁵

The following landmarks were identified on the profile photographs (Figure 1):

1. Center of tragus.
2. Outer canthus (lateral intereyelid junction).

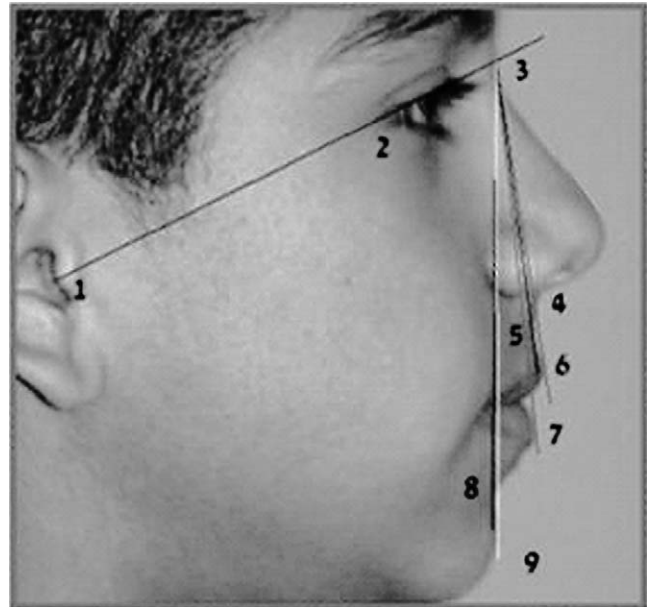


Figure 1. Landmarks and angles created by the moving lines (for details, see Materials and Methods section).

These two points were used to construct the reference line (tragus–canthus line).

3. Nasion-modified: the point where the elongated reference line intersects with the profile
4. Subnasale
5. A': soft A point
6. Upper lip: the most prominent point of the upper lip—modified vermilion
7. Lower lip: the most prominent point of the lower lip—modified vermilion
8. B': soft B point
9. Pog': soft pogonion

Enlargement up to three times was applied to the photographs, if needed to assist with landmark identification.

Angular Measurements

Lines were constructed between identified lower facial landmarks (points 4–9) and the nasion-modified point. These lines were elongated and were moved by a computerized measuring tool of moving lines until they were tangent to the desired point. The angle that was created between these lines and the reference line at the nasion-modified point was measured. All measurements were angular for the purpose of overcoming possible size differences in the photographs. All measurements were performed twice, with a 45-day interval between measurements intended to overcome the memory effect of the operator.

Angular measurements between consecutive photographs and between the averages of two time points

Table 1. Differences Between Two Sets of Photographs With 0 Time Interval^a

| | Upper Vermilion | Lower Vermilion | Sub-Nasale | A Point | B Point | Pogonion |
|-------|-----------------|-----------------|--------------|--------------|--------------|--------------|
| T-0 | 77.47 ± 0.81 | 74.64 ± 0.85 | 77.14 ± 1.05 | 75.73 ± 0.9 | 68.32 ± 0.89 | 69.14 ± 0.9 |
| T-0' | 77.08 ± 0.91 | 74.49 ± 1.02 | 77.07 ± 0.93 | 75.6 ± 0.96 | 68.41 ± 0.99 | 69.23 ± 0.96 |
| T-30 | 77.64 ± 1.05 | 74.61 ± 1.00 | 77.39 ± 1.25 | 75.94 ± 1.07 | 68.31 ± 1.09 | 69.19 ± 1.05 |
| T-30' | 77.26 ± 0.95 | 74.68 ± 0.96 | 77.12 ± 1.1 | 75.65 ± 0.92 | 68.39 ± 1.05 | 69.09 ± 1.04 |
| P* | .09 | .93 | .26 | .37 | .44 | .96 |

^a n = 18; T-0 vs T-0' and T-30 vs T-30' (Wilcoxon rank-sum for paired differences). * P > .05 NS.

were compared. The comparison was statistically analyzed by means of one-way analysis of variance (ANOVA) and the Wilcoxon rank-sum test for paired differences.

Effect of Labial Appliances on Lip Prominence

Facial clinical profile photographs of 33 teenagers (27 males and 6 females) taken at the end of treatment were used. All patients were treated with the straight-wire labial technique (Mini Diamond Roth prescription, 0.022-inch slot width, Ormco, Orange, Calif), and treatment was completed in a Class I normocclusion.

Photographs

All patients had two photographic pictures taken before debonding and two taken immediately after debonding and underwent cleaning of the teeth (which took about 30 minutes); the best picture of the two was chosen. Photographs were taken under nonstandard conditions. Landmark identification and angular measurements on pre-debonding and post-debonding photographs were calculated and compared. These measurements were repeated after 45 days. A t-test for paired differences was used (P < .05).

RESULTS

Establishing the Photoanalysis

No significant differences were found in all six angular measurements between the two consecutive photographs (T-0/T-0', T-30/T-30') (Table 1; Figure 2).

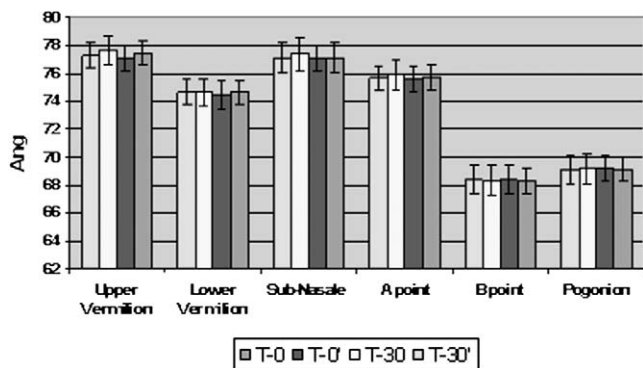


Figure 2. Comparison of angles between photographs with 0 time interval (n = 18; T-0 vs T-0' and T-30 vs T-30').

- T-0 (initial measurements)
- T-0' (measurements of the same picture after 45 days)
- T-30 (initial measurements of picture after 30 minutes)
- T-30' (measurements of the 30-minute picture after 45 days)

Comparison of average angular measurements in photographs at the two time points (T-0 + T-0' vs T-30 + T-30') showed no significant differences between them (Table 2).

Effects of Labial Appliances on Lip Prominence

The two angular measurements describing lip prominence (upper vermilion and lower vermilion) showed no differences before and after debonding (Table 3; Figure 3).

- T-0 (pre-debonding measurement)
- T-0' (pre-debonding measurements of the same picture after 45 days)
- T-30 (immediately after debonding measurements)
- T-30' (debonding measurements of the same picture after 45 days)

No differences were found between the other four angular measurements before and after debonding (Table 3; Figure 3). The sub-nasale angle showed a large variation in measurements before and after debonding, although this variation was not statistically significant.

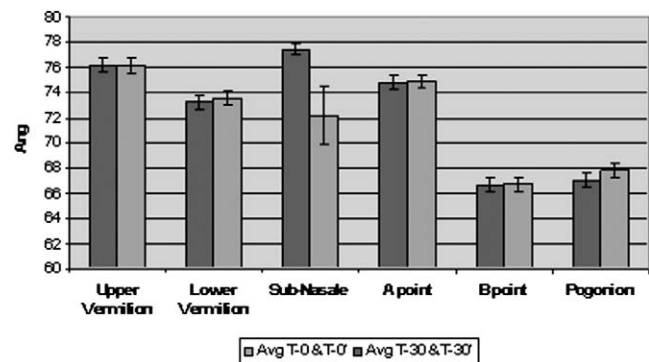


Figure 3. Comparison of angles between pre-debonding and post-debonding (n = 33; average T-0 and T-0' vs T-30 and T-30').

Table 2. Comparison of Photographs With 30-Minute Intervals Without Treatment^a

| | Upper Vermilion | Lower Vermilion | Sub-Nasale | A Point | B Point | Pogonion |
|--|-----------------|-----------------|--------------|-------------|--------------|--------------|
| Avg T-0 and T-0' | 77.27 ± 0.84 | 74.57 ± 0.92 | 77.1 ± 0.97 | 75.67 ± 0.2 | 68.37 ± 0.93 | 69.19 ± 0.92 |
| Avg T-30 and T-30' | 77.45 ± 1.00 | 74.65 ± 0.97 | 77.26 ± 1.16 | 75.8 ± 0.99 | 68.35 ± 1.07 | 69.14 ± 1.04 |
| <i>P</i> * (T-30 and T-30') – (T-0 and T-0') | .47 | .44 | .55 | .59 | .22 | .51 |

^a n = 9; T-30 vs T-0 (Wilcoxon rank-sum for paired differences). * *P* > .05 NS.

DISCUSSION

A new soft tissue profile photoanalysis is described in the present study. This method, performed with Viewbox software, can provide supplementary data and should not replace common soft tissue cephalometric measurements.

It is important to emphasize that the analysis is based on the major finding that all angular measurements formed from the various landmarks were accurate and reproducible at different time points of photography. These findings also suggest that identification of anatomic landmarks is easy, and that probably no significant errors occurred in the vertical or the horizontal plane. However, the angle created by sub-nasale showed large variation, most probably because of the fact that this point is located on a more horizontal envelope of error.²⁶

This study focused on angular changes as they correspond to postural changes in the lips, but it is possible to assess other tissues, such as nose and chin, by constructing the relevant angular planes. It will be of great interest to compare this profile photoanalysis with corresponding cephalometric landmarks, and furthermore, to evaluate the effects of different treatment modalities, age changes, various ethnic populations, and so forth, on soft tissue photographic profiles.

The advantages of a photographic image over a radiographic one are obvious, and it is suggested that the ability of this soft tissue photoanalysis to substitute corresponding cephalometric measurements must be the topic of comprehensive comparative studies. In the meantime, this type of photoanalysis may be used as an additional clinical tool.

Results of photoanalysis showed that labial appliances bonded on the upper anterior teeth do not affect lip prominence. Patients who participated in this study were not subdivided according to lip thickness or dimensions of the brackets because at this stage of the research, we were interested in lip posture of the same

patient with and without brackets. Obviously, comparisons between all possible variants are required.

The notion that lingual orthodontics is superior to the labial technique in terms of lip prominence is rejected, given the results of the present work. Orthodontists can be certain that lip posture at the end of treatment prior to debonding will not change in the short range following removal of appliances. Thus, the orthodontist can reassure the patient that no reclining sinking of the lips will occur after removal of the braces. An additional study undertaken to examine the long-term effects of labial bracket removal on lip position is in progress.

This study presented one application of simple soft tissue photoanalysis. In the future, it might be feasible to extend the use of these computer-processed photographic principles to other photoanalyses.

CONCLUSIONS

- Angular measurements used in this photoanalysis were validated as reproducible.
- In keeping with the design of this study, bonded labial appliances had no significant effect on lip prominence in the short term after debonding.

REFERENCES

1. Arnett GW, Bergman RT. Facial keys to orthodontic diagnosis and treatment planning—Part II. *Am J Orthod Dentofacial Orthop.* 1993;103:395–411.
2. Arnett GW, Bergman RT. Facial keys to orthodontic diagnosis and treatment planning. Part I. *Am J Orthod Dentofacial Orthop.* 1993;103:299–312.
3. Arnett GW, Gunson MJ. Facial planning for orthodontists and oral surgeons. *Am J Orthod Dentofacial Orthop.* 2004;126:290–295.
4. Bishara SE, Hession TJ, Peterson LC. Longitudinal soft-tissue profile changes: a study of three analyses. *Am J Orthod.* 1985;88:209–223.
5. Hillesund E, Fjeld D, Zachrisson BU. Reliability of soft-tissue profile in cephalometrics. *Am J Orthod.* 1978;74:537–550.
6. Holdaway RA. A soft-tissue cephalometric analysis and its

Table 3. Comparison of Photographs With 30-Minute Intervals Before and After Debonding^a

| | Upper Vermilion | Lower Vermilion | Sub-Nasale | A Point | B Point | Pogonion |
|--|-----------------|-----------------|-------------|--------------|--------------|--------------|
| Avg T-0 and T-0' | 76.23 ± 0.62 | 73.53 ± 0.56 | 72.2 ± 2.34 | 74.98 ± 0.53 | 66.8 ± 0.57 | 67.85 ± 0.6 |
| Avg T-30 and T-30' | 76.23 ± 0.61 | 73.27 ± 0.56 | 77.2 ± 0.5 | 74.87 ± 0.53 | 66.74 ± 0.54 | 67.06 ± 0.57 |
| <i>P</i> * (T-30 and T-30') – (T-0 and T-0') | .78 | .32 | .35 | .67 | .76 | .55 |

^a n = 33; T-30 vs T-0 (*t*-test for paired differences). * *P* > .05 NS.

- use in orthodontic treatment planning. Part I. *Am J Orthod.* 1983;84:1–28.
7. Kocadereli I. Changes in soft tissue profile after orthodontic treatment with and without extractions. *Am J Orthod Dentofacial Orthop.* 2002;122:67–72.
 8. Alcalde RE, Jinno T, Orsini MG, Sasaki A, Sugiyama RM, Matsumura T. Soft tissue cephalometric norms in Japanese adults. *Am J Orthod Dentofacial Orthop.* 2000;118:84–89.
 9. Hwang HS, Kim WS, McNamara JA Jr. Ethnic differences in the soft tissue profile of Korean and European-American adults with normal occlusions and well-balanced faces. *Angle Orthod.* 2002;72:72–80.
 10. Mantzikos T. Esthetic soft tissue profile preferences among the Japanese population. *Am J Orthod Dentofacial Orthop.* 1998;114:1–7.
 11. Polk MS Jr, Farman AG, Yancey JA, Gholston LR, Johnson BE, Regennitter FJ. Soft tissue profile: a survey of African-American preference. *Am J Orthod Dentofacial Orthop.* 1995;108:90–101.
 12. Sutter RE Jr, Turley PK. Soft tissue evaluation of contemporary Caucasian and African American female facial profiles. *Angle Orthod.* 1998;68:487–496.
 13. Attarzadeh F, Adenwalla ST. Soft-tissue profile changes concurrent with the orthodontic treatment. *Int J Orthod.* 1990;28:9–16.
 14. Koch R, Gonzales A, Witt E. Profile and soft tissue changes during and after orthodontic treatment. *Eur J Orthod.* 1979;1:193–199.
 15. Lavelle CL, Carvalho RS. An evaluation of the changes in soft-tissue profile form induced by orthodontic therapy. *Am J Orthod Dentofacial Orthop.* 1989;96:467–476.
 16. Legan HL, Burstone CJ. Soft tissue cephalometric analysis for orthognathic surgery. *J Oral Surg.* 1980;38:744–751.
 17. Talass MF, Talass L, Baker RC. Soft-tissue profile changes resulting from retraction of maxillary incisors. *Am J Orthod Dentofacial Orthop.* 1987;91:385–394.
 18. Fernandez-Riveiro P, Smyth-Chamosa E, Suarez-Quintanilla D, Suarez-Cunqueiro M. Angular photogrammetric analysis of the soft tissue facial profile. *Eur J Orthod.* 2003;25:393–399.
 19. Fernandez-Riveiro P, Suarez-Quintanilla D, Smyth-Chamosa E, Suarez-Cunqueiro M. Linear photogrammetric analysis of the soft tissue facial profile. *Am J Orthod Dentofacial Orthop.* 2002;122:59–66.
 20. Ferrario VF, Sforza C, Miani A, Tartaglia G. Craniofacial morphometry by photographic evaluations. *Am J Orthod Dentofacial Orthop.* 1993;103:327–337.
 21. Dimaggio FR, Ciusa V, Sforza C, Ferrario VF. Photographic soft-tissue profile analysis in children at 6 years of age. *Am J Orthod Dentofacial Orthop.* 2007;132:475–480.
 22. Benson PE, Richmond S. A critical appraisal of measurement of the soft tissue outline using photographs and video. *Eur J Orthod.* 1997;19:397–409.
 23. Bearn DR, Sandy JR, Shaw WC. Photogrammetric assessment of the soft tissue profile in unilateral cleft lip and palate. *Cleft Palate Craniofac J.* 2002;39:597–603.
 24. Creekmore T. Lingual orthodontics—its renaissance. *Am J Orthod Dentofacial Orthop.* 1989;96:120–137.
 25. Halazonetis DJ. Computer-assisted cephalometric analysis. *Am J Orthod Dentofacial Orthop.* 1994;105:517–521.
 26. Baumrind S, Frantz RC. The reliability of head film measurements. 2. Conventional angular and linear measures. *Am J Orthod.* 1971;60:505–517.