

## Influence of Radiographic Position of Ectopic Canines on the Duration of Orthodontic Treatment

Padhraig S. Fleming<sup>a</sup>; Paul Scott<sup>a</sup>; Negan Heidari<sup>b</sup>; Andrew T. DiBiase<sup>c</sup>

### ABSTRACT

**Objective:** To investigate the influence of radiographic position of palatally impacted canines on the length of treatment for orthodontic alignment.

**Materials and Methods:** Treatment records of 45 consecutive successfully treated patients (36 unilateral, 9 bilateral) with ectopic palatal canines treated with surgical exposure and orthodontic traction were analyzed. The sample was based on orthodontic referrals over a 3-year period in Kent and Canterbury Hospital, UK. The duration of treatment was related to radiographic parameters including the height of the impacted canine, angulation of the long axis to the upper midline, mesiodistal position of the canine tip relative to the midline and adjacent incisors, and the antero-posterior position of the canine root apex.

**Results:** Using multiple stepwise regression analysis, the horizontal position of the canine crown relative to adjacent teeth and maxillary dental midline showed a statistically significant correlation with the duration of treatment ( $P = .042$ ), explaining 7.7% of the overall variance. However, treatment duration was found to be independent of the initial canine angulation ( $P = .915$ ), vertical height ( $P = .065$ ), and position of the canine apex ( $P = .937$ ).

**Conclusions:** Accurate prediction of treatment duration for orthodontic alignment of palatally impacted maxillary canines is difficult. However, the mesiodistal position of the canine may be a useful predictor of treatment duration. (*Angle Orthod.* 2009;79;442–446.)

**KEY WORDS:** Treatment duration; Impaction; Canine; Orthodontics

### INTRODUCTION

The maxillary canine is second only to the mandibular third molar in its frequency of impaction with a reported incidence of 0.8% to 2.8%<sup>1,2</sup> and a female predilection, with most impacted canines palatal to the arch<sup>3</sup>.

Surgical exposure and orthodontic traction is the preferred approach for management of palatally impacted canines in compliant, motivated patients, with

good dental health, where interceptive measures are inappropriate.<sup>4</sup> The position of the impacted canine gauged radiographically is instrumental to the orthodontist's decision to both expose and orthodontically align, or to remove the impacted maxillary canine.<sup>5</sup> A grading system to determine the severity of palatal impaction of canines based on radiographic location has been proposed,<sup>6</sup> with high canines having severely transposed roots considered most unfavorable. Four main radiographic predictors believed to correlate with prognosis for exposure and alignment of ectopic canines have been described.<sup>7</sup> These considerations include angulation of the canine long axis to the midline, vertical position of the canine crown from the occlusal plane, anteroposterior position of the canine root apex relative to the midline, and the degree of overlap of the adjacent incisor by the canine crown tip.

However, there is little evidence linking the duration of orthodontic mechanical eruption of the impacted palatal canine to these influential radiographic predictors. Stewart et al,<sup>8</sup> in a retrospective study, suggested alignment of canines positioned 14 mm or more above the occlusal plane to take longer than those in a more

---

<sup>a</sup> Resident in Orthodontics, Kent and Canterbury Hospital, Canterbury, Kent, UK and Royal London Dental Institute, London, UK.

<sup>b</sup> Senior House Officer, Kent and Canterbury Hospital, Canterbury, Kent, UK.

<sup>c</sup> Consultant in Orthodontics, Kent and Canterbury Hospital, Canterbury, Kent, UK.

Corresponding author: Mr Andrew DiBiase, Kent and Canterbury Hospital, Orthodontics, Ethelbert Rd, Canterbury, Kent CT1 3NG, UK.

(e-mail: Andrew.dibiase@ekht.nhs.uk)

Accepted: June 2008. Submitted: April 2008.

© 2009 by The EH Angle Education and Research Foundation, Inc.

favorable vertical position. Furthermore, Zucatti et al<sup>9</sup> reported a strong association between the number of visits and increasing age, vertical height, and mesial displacement of the cusp tip. However, that study involved a heterogeneous sample treated by multiple operators.

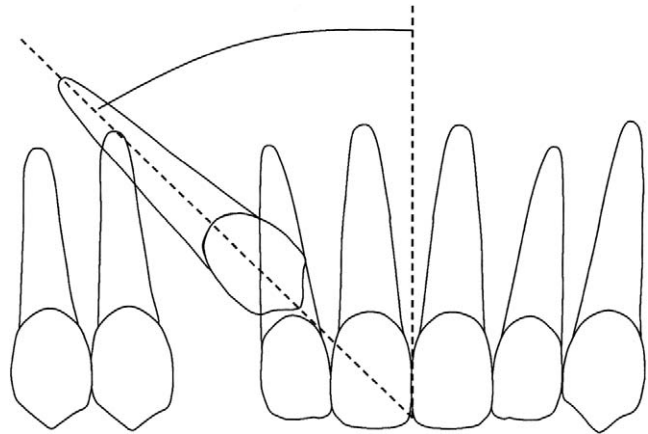
The aim of this research was to investigate further the relationship of these radiographic predictors to duration of orthodontic treatment.

## MATERIALS AND METHODS

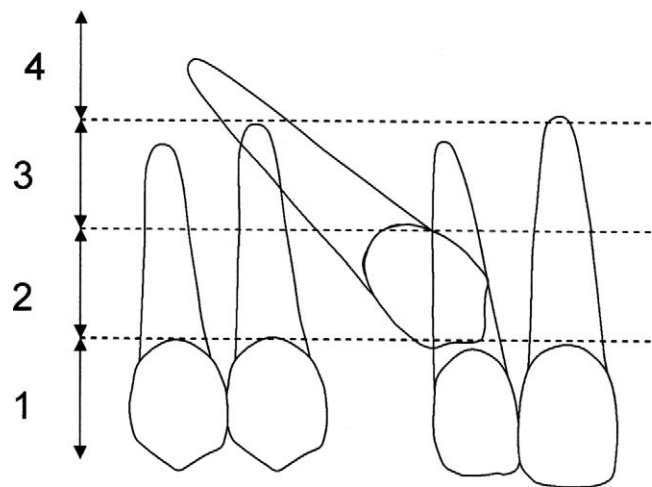
The clinical notes and panoramic and intraoral radiographs of consecutively, successfully completed subjects having surgical exposure of palatal maxillary canines and subsequent orthodontic alignment between 1999 and 2002 were obtained. The inclusion criteria were the presence of one or two palatally impacted canines requiring surgical exposure and mechanical orthodontic eruption; well-aligned arches or the presence of mild crowding requiring nonextraction-based treatment with orthodontic treatment directed primarily at aligning the canine; and the availability of adequate records including complete diagnostic records and treatment notes with pretreatment panoramic radiographs.

The exclusion criteria were undocumented clinical appointments; patients over 18 years of age; craniofacial syndromes including cleft lip and palate; hypodontia of associated maxillary lateral incisors; the requirement for secondary surgical procedures to reexpose canines; repeated histories of broken appliances and failed appointments. Patients having panoramic radiographs with significant distortion precluding identification of anatomic landmarks in the anterior maxilla were also excluded from the study. The quality of radiographs was assessed by one operator (Mr DiBiase).

Participants included in the trial followed a similar treatment protocol. They all were treated in one orthodontic department undergoing surgical exposure of the canine and placement of a preadjusted edgewise appliance with 0.022 × 0.028 inch slot (3M Unitek, Monrovia, Calif) to align the teeth and recreate space for the ectopic canine. They all had elastomeric traction to bring the canine into correct alignment using 0.018-inch stainless steel as the working archwire. For the purpose of the investigation, the duration of treatment was taken as the period from the date of surgical exposure to correct alignment in the arch with a 0.019 × 0.025 inch stainless steel wire, which had been in place for 1 month.<sup>10</sup> In bilateral cases, both teeth were exposed at the same time, and simultaneous traction was applied. Alignment of the more rapidly aligned canine was considered complete 8 weeks following initial



**Figure 1.** Angulation of the canine long axis to the upper midline. Two lines were extrapolated from the midline and the impacted canine, the angle between them was measured and grouped: Grade 1: 0°–15°; Grade 2: 16°–30°; Grade 3: ≥31°.



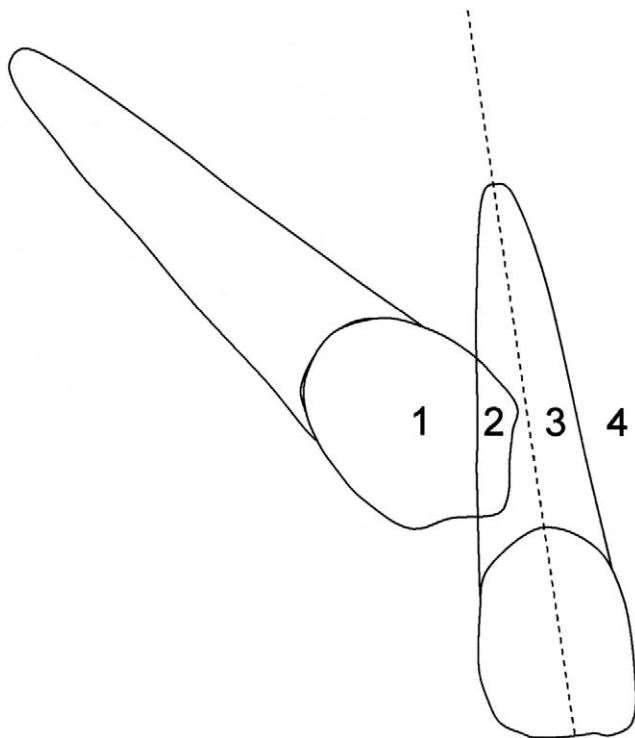
**Figure 2.** Depth of impaction of canine relative to root of incisor. Grade 1: Below the level of the cemento-enamel junction (CEJ). Grade 2: Above the CEJ, but less than halfway up the root. Grade 3: More than half way up the root, but less than the full root length. Grade 4: Above the full length of the root.

complete engagement of a 0.018-inch stainless steel wire. The following radiographic variables were assessed based on the pretreatment panoramic view:

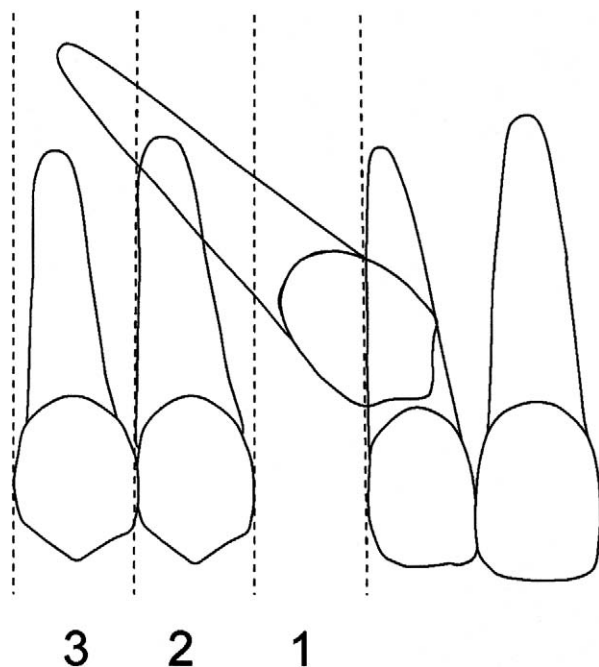
- Angulation of the canine to the midline in degrees (Figure 1).
- Vertical distance from the occlusal plane (Figure 2).
- Mesiodistal position of canine tip (Figure 3).
- Position of canine root apex anteroposteriorly (Figure 4).

## Statistical Methods

Demographic and radiographic data was assessed with conventional descriptive statistics. The influence



**Figure 3.** Mesiodistal position of the canine tip. Grade 1: No horizontal overlap. Grade 2: Less than half the root width. Grade 3: More than half, but less than the whole root width. Grade 4: Complete overlap of root width or more.



**Figure 4.** Position of the canine apex relative to the adjacent teeth. Grade 1: Above the region of the canine position. Grade 2: Above the upper first premolar region. Grade 3: Above the upper second premolar region.

**Table 1.** Intraexaminer Reliability for Measurement of Radiographs at a 4-Week Interval

Variable	Difference		95% CI	r
	T1-T2	SD		
Angulation	1.11	2.83	-0.26, 2.48	.99
Height	-0.26	1.37	-0.92, 0.40	.92
Midline	-0.11	1.24	-0.70, 0.49	.97

of radiographic predictors on treatment duration was investigated using a stepwise regression analysis. All data analysis was performed with the Statistical Package for Social Sciences (SPSS Inc, version 13.0, Chicago, Ill) with a prespecified level of statistical significance of  $P < .05$ .

**RESULTS**

**Intraexaminer Reliability**

Radiographic variables were measured twice by a single operator (Mr DiBiase) on 20 radiographs at a 4-week interval. The weighted kappa values (k) ranged from 0.92 to 0.99, showing good intraexaminer agreement for both angular and linear measurements (Table 1).

The sample included 45 patients with 54 palatal ectopic canines; 36 subjects (80%) were female. The age at the time of surgical exposure ranged from 12.42 to 18 years with a mean of 14.81 years (SD 2.83). The descriptive clinical characteristics for the study group are shown in Table 2. Most subjects had a Class I malocclusion (52%), with 13% having a Class II division 1 incisor relationship, 9% Class II division 2, and 26% Class III. Overall, mean treatment duration was over 26.31 months (SD 9.31).

In the stepwise multiple regression (Table 3), treatment duration was entered as the dependent variable. Graded horizontal position explained 7.7% of the variance in treatment duration ( $P = .042$ ,  $R^2 = .077$ ). No further predictors were found with age ( $P = .614$ ), angulation ( $P = .915$ ), vertical position ( $P = .065$ ), location of the root apex ( $P = .0937$ ), and type of exposure not associated with duration of treatment ( $P = .781$ ).

**DISCUSSION**

Factors implicated in increasing the duration of orthodontic treatment include the number of failed appointments, the number of treatment phases, poor compliance in terms of maintenance of oral hygiene and headgear cooperation, Class II molar relationship, treatment involving extraction of teeth, pretreatment sagittal skeletal discrepancy, and age at the start of treatment.<sup>11-13</sup> As this study was retrospective in design, all of these factors were difficult to control com-

**Table 2.** Clinical Characteristics of the Study Population

Clinical Characteristic	Number	Percentage of Total	Mean Treatment Duration, Months
<b>Incisor relationship</b>			
Class I	28	51.9	25.9
Class II division 1	7	12.9	22.6
Class II division 2	5	9.3	30.2
Class III	14	25.9	27.7
<b>Canine position</b>			
Angulation to midline 0–15°	3	5.6	27.7
Angulation to midline 15–30°	23	42.6	24.4
Angulation to midline >31°	28	51.9	27.8
Height below cemento-enamel junction (CEJ)	0	0	—
Height between CEJ and ½ root	10	18.5	30.7
Height above ½ adjacent root length	44	81.5	25.3
Height above adjacent root	0	0	—
No overlap	2	3.7	23
Overlap of <½ root width	10	18.5	24.5
Overlap of >½ root width	14	25.9	23.1
Complete overlap of root	28	51.9	28.8
Apex above canine position	2	3.7	34
Apex above first premolar	47	87	26
Apex above second premolar	5	9.3	26.4
<b>Type of surgical exposure</b>			
Open	42	77.8	26.4
Closed	12	22.2	26

**Table 3.** Stepwise Regression Analysis of Treatment Duration

Variable	T Ratio	Partial Correlation	P Value
Age	-0.11	-0.015	.614
Canine angulation	-0.08	-0.011	.915
Canine height	-0.28	-0.04	.065
Mesiodistal position of canine tip	-0.87	-0.12	.042
Position of apex	1.88	0.26	.937
Type of exposure	0.51	0.07	.781

pletely. However, the influence of factors likely to affect treatment duration was kept to a minimum; all subjects were treated without extraction, those with poor compliance and who failed multiple appointments were excluded from the analysis. Treatment proceeded in one phase and correction of a Class II molar relationship was not attempted in any subject. Therefore, it is considered that duration of treatment accurately reflected the time taken to align the maxillary canine. In the current study, treatment time for alignment of the impacted canine was 26.3 months; this treatment duration is similar to previous reports of 28.8 months<sup>10</sup> and 25.8 months.<sup>8</sup> Orthodontic treatment duration to address impacted canines is correlated with increasing age.<sup>9</sup> In particular, mechanical eruption of palatal canines in patients over 30 years of age has a less favorable prognosis<sup>14</sup>; consequently, a low upper age threshold of 18 years was used to eliminate this confounding factor in the current study. Increasing age

was also found to have no influence on treatment duration in the stepwise regression analysis.

The reliability of panoramic radiographs in the anterior maxilla is limited; narrowing of the focal trough ensures apices and associated structures appear out of focus or even invisible.<sup>15</sup> Overestimation of the angulation of the misplaced canine and of the distance of the tooth from the midline is typical of panoramic views<sup>16</sup> with distortions in the horizontal plane tending to be nonlinear.<sup>17</sup> However, while the advent of three-dimensional radiographic techniques in dentistry and orthoradial intraoral radiographs may allow more precise localization of the impacted canine in the future, panoramic views continue to be used to assess the location of impacted canines.<sup>5</sup> Therefore, panoramic radiographs were used to assess canine position horizontally and vertically in this retrospective study. However, position was related to adjacent teeth rather than being given absolute measurements; this approach contrasts with previous reports.<sup>8</sup>

Interpretation of panoramic radiographic information has been used to decide as to whether to extract an impacted canine or attempt orthodontic alignment.<sup>5</sup> As angulation to the midline increases so does the preference for removal rather than alignment; however, the findings from the current study fail to support this rationale.

Stewart et al.,<sup>8</sup> in a retrospective study performed in three centers based on analysis of panoramic radio-

graphs, detected a threshold height of 14 mm from the tip of the impacted canine to the occlusal plane; above this level, treatment duration increased from 24 to 31 months. In the current study, concerns relating to the validity of direct measurement of vertical canine position on the panoramic film ensured the height of the displaced canine tip was considered in terms of its position relative to the adjacent tooth. Canines impacted more than halfway above the adjacent tooth took almost 6 months longer to correct (30.7 vs 25.3 months). However, the study was of inadequate power to detect a statistically significant effect ( $P = .065$ ).

Using the regression analysis, the degree of overlap of adjacent incisors in this study was the only variable to show a statistically significant relationship with the duration of treatment explaining 7.7% of the variance in treatment duration. This finding confirms the association between more treatment visits and mesial displacement of impacted canines highlighted by Zuccati et al.<sup>9</sup> Consequently, a radiographic finding of significant horizontal displacement of an impacted palatal canine may alert the clinician to the likelihood of an extended duration of orthodontic treatment. This knowledge may also be helpful for patients to make an informed treatment choice.

## CONCLUSIONS

- The mesiodistal position of the impacted canine is related to overall treatment duration ( $P = .042$ ). In the current study, this factor explained 7.7% of the observed variance.
- In the present study, treatment duration for correction of palatally impacted canines could not be related to the sagittal position of the canine apex, horizontal position, or angulation of the canine long axis to the midline.
- Further prospective research is required to investigate other variables that could affect treatment duration, including the type of surgical procedure and the type of mechanics used to align ectopic canines.

## REFERENCES

1. Thilander B, Myrberg N. The prevalence of malocclusion in Swedish schoolchildren. *Scand J Dent Res*. 1973;81:12–21.
2. Ericson S, Kurol J. Radiographic assessment of maxillary canine eruption in children with clinical signs of eruption disturbance. *Eur J Orthod*. 1986;8:133–140.
3. Ericson S, Kurol J. Resorption of incisors after ectopic eruption of maxillary canines: a CT study. *Angle Orthod*. 2000;70:415–423.
4. McSherry PF. The ectopic maxillary canine: a review. *Br J Orthod*. 1998;25:209–216.
5. Stivaros N, Mandall N. Radiographic factors affecting the management of impacted upper permanent canines. *J Orthod*. 2000;27:169–173.
6. Becker A. *The orthodontic treatment of impacted teeth*. 2nd ed. London, UK: Martin Dunitz Publishers; 2007:19–140.
7. Ericson S, Kurol J. Radiographic examination of ectopically erupting maxillary canines. *Am J Orthod Dentofacial Orthop*. 1987;91:483–492.
8. Stewart JA, Heo G, Glover KE, Williamson PC, Lam EW, Major PW. Factors that relate to treatment duration for patients with palatally impacted maxillary canines. *Am J Orthod Dentofacial Orthop*. 2001;119:216–225.
9. Zuccati G, Ghobadlu J, Nieri M, Clauser C. Factors associated with the duration of forced eruption of impacted maxillary canines: a retrospective study. *Am J Orthod Dentofacial Orthop*. 2006;130:349–356.
10. Iramaneerat S, Cunningham SJ, Horrocks EN. The effect of two alternative methods of canine exposure upon subsequent duration of orthodontic treatment. *Int J Paediatr Dent*. 1998;8:123–129.
11. Beckwith FR, Ackerman RJ, Cobb CM, Tira DE. An evaluation of factors affecting duration of orthodontic treatment. *Am J Orthod Dentofacial Orthop*. 1998;115:439–447.
12. Skidmore KJ, Brook KJ, Thomson WM, Harding WJ. Factors influencing treatment time in orthodontic patients. *Am J Orthod Dentofacial Orthop*. 2006;129:230–238.
13. Fink DF, Smith RJ. The duration of orthodontic treatment. *Am J Orthod Dentofacial Orthop*. 1992;102:45–51.
14. Becker A, Chaushu S. Success rate and duration of orthodontic treatment for adult patients with palatally impacted maxillary canines. *Am J Orthod Dentofacial Orthop*. 2003;124:509–514.
15. Leach HA, Ireland AJ, Whaites EJ. Radiographic diagnosis of root resorption in relation to orthodontics. *Br Dent J*. 2001;190:16–22.
16. Coupland MA. Localisation of misplaced maxillary canines, orthopantomograph and P.A. skull views compared. *Br J Orthod*. 1984;11:27–32.
17. Tronje G, Welander U, McDavid WD, Morris CR. Image distortion in rotational panoramic tomography. III. Inclined objects. *Acta Radiol Diagn (Stockh)*. 1981;22(5):585–592.