

## Maxillary Incisor Proclination Effect on the Position of Point A in Class II division 2 Malocclusion

Kazem S. Al-Nimri<sup>a</sup>; Abdalla M. Hazza<sup>a,b</sup>; Rami M. Al-Omari<sup>c</sup>

### ABSTRACT

**Objective:** To test the hypothesis that the magnitude of alteration in the position of point A is not associated with proclination of the upper incisors in Class II division 2 malocclusion.

**Materials and Methods:** Cephalometric films were taken for 30 Class II division 2 patients (8 males and 22 females; average age, 18.3 years) before and after upper incisor proclination. The total change in the position of point A was measured by superimposing the pretreatment and postproclination lateral cephalograms on the sella-nasion line at the sella. To determine the local effect of alveolar bone remodeling associated with upper incisor proclination on the position of point A, postproclination tracing of the maxilla was superimposed on the pretreatment tracing according to the Bolton template of maxillary superimposition.

**Results:** The total vertical displacement in Point A position was downward by 0.84 mm ( $P = .002$ ), and the total horizontal displacement was forward by 0.45 mm ( $P = .054$ ). Assessment of local changes in point A revealed that the position of point A had moved backward by 0.60 mm ( $P = .001$ ). No significant change was observed in the value of the sella-nasion–point A angle (SNA).

**Conclusion:** The hypothesis is rejected. The position of point A is affected by local bone remodeling associated with proclination of the upper incisor in Class II division 2 malocclusion, but this minor change does not significantly affect the SNA angle. (*Angle Orthod.* 2009;79:880–884.)

**KEY WORDS:** Point A; Upper incisor inclination; Class II division 2; SNA angle

### INTRODUCTION

To determine the sagittal denture base relationship, Riedal<sup>1</sup> recommended the use of sella-nasion–point A (SNA), sella-nasion–point B (SNB), and ANB angles. The ANB angle has been recognized as a skeletal sagittal discrepancy indicator and has become the most commonly used measurement. However, this angle varies according to the extension and inclination of the anterior cranial base.<sup>2–4</sup> It also varies according to

patient age, the vertical and anteroposterior (AP) position of the nasion,<sup>5,6</sup> the upward or downward rotation of the jaws, and the degree of facial prognathism.<sup>7</sup>

To overcome these shortcomings, many linear measurements have been proposed to determine the actual AP relationship of the jaws: (1) the distance between perpendiculars drawn from the sella-nasion line to points A and B,<sup>8</sup> (2) the distance between perpendiculars drawn from the occlusal plane to points A and B (Wits appraisal),<sup>2</sup> (3) the AP dysplasia indicator,<sup>9</sup> (4) the distance between perpendiculars drawn from the Frankfort plane to points A and B,<sup>10,11</sup> (5) the distance between perpendiculars drawn from the palatal plane to points A and B,<sup>12</sup> and (6) the distance between perpendiculars drawn from the bisector of the maxillo-mandibular plane angle to points A and B.<sup>13,14</sup> Nevertheless, these measurements still use point A as a reference point for the AP position of the maxilla. The position of point A is believed to be affected by alveolar bone remodeling associated with orthodontic tooth movement of the upper incisors.<sup>15</sup> Erverdi<sup>16</sup> reported that there is a significant correlation between the axial inclination of the upper incisors and the position of point A. Arvysts<sup>17,18</sup> presented two cases of nonextrac-

<sup>a</sup> Associate Professor, Department of Orthodontics, School of Dentistry, Jordan University of Science and Technology, Irbid, Jordan.

<sup>b</sup> Associate Professor, Department of Maxillo-facial radiology, School of Dentistry, Jordan University of Science and Technology, Irbid, Jordan.

<sup>c</sup> Graduate MS student, Department of Orthodontics, School of Dentistry, Jordan University of Science and Technology, Irbid, Jordan.

Corresponding author: Dr Kazem S Al-Nimri, Department of Orthodontics, School of Dentistry, Jordan University of Science and Technology, JUST PO Box 3030 Irbid, Irbid 22110 Jordan (e-mail: kazemnimri@hotmail.com)

Accepted: October 2008. Submitted: August 2008.

© 2009 by The EH Angle Education and Research Foundation, Inc.

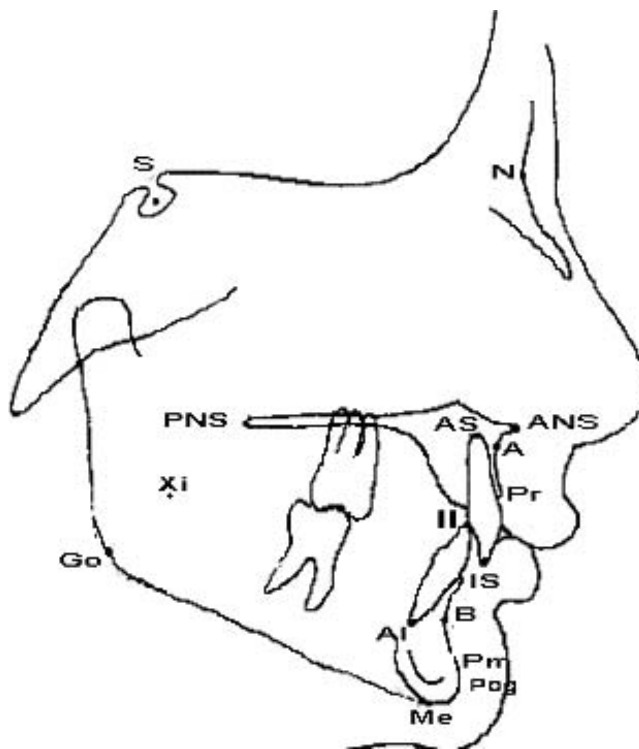
tion treatment of severe Class II division 2 malocclusion; at the end of treatment, he noticed that the SNA angle was reduced. He explained this minor change as an effect of the maxillary incisor root torque. During examination of pretreatment and posttreatment cephalometric data on Class II division 2 malocclusion, Cleall and BeGole<sup>19</sup> noted that the SNA angle was reduced, and the SNB angle was slightly increased.

In Class II division 2, the maxillary incisors are retroclined. During orthodontic treatment, the inclination of the maxillary incisors should be corrected. If the position of point A is affected by the inclination of the maxillary incisors, this should be considered in the diagnosis of the AP skeletal relationship. The aim of this study is to determine the magnitude of alterations in the position of point A associated with proclination of the upper incisors in Class II division 2 malocclusion.

## MATERIALS AND METHODS

Thirty subjects (8 males and 22 females) were selected from the patient list at the orthodontic clinic in the Teaching Dental Center of the Jordan University of Science and Technology. All cases were diagnosed with Class II division 2 malocclusion according to the British standard institute classification, which defines Class II division 2 malocclusion as that malocclusion in which the permanent mandibular incisors occlude posterior to the cingulum plateau of the retroclined permanent maxillary incisors.<sup>20</sup> The average age of the sample was  $18.2 \pm 3.8$  years, with a range from 13 to 25 years.

After permission was received from the institutional review board comity in Jordan, this study was launched by exposing the pretreatment lateral cephalogram for all subjects. Orthodontic treatment was started thereafter by bonding a straight wire orthodontic appliance (Roth prescription, slot size  $0.022 \times 0.028$  inch) to the upper arch only. At this stage, no treatment was performed in the lower arch. No lace-backs or cinch back bends were placed in the upper archwire to allow for upper incisor proclination. If more proclination was required, this was accomplished by placing labial crown torque in the working archwire. Orthodontic treatment was continued in the upper arch only until sufficient proclination of the upper incisors was achieved to establish an overjet of at least 4 mm. A midtreatment lateral cephalogram was taken to confirm sufficient upper incisor proclination. An angle equal to or greater than 108 degrees between the long axis of the upper central incisors and the maxillary plane indicated sufficient proclination. At this stage, the lower arch was bonded and the orthodontic treatment was continued. No headgear or functional appliances were used before or simultaneously with use of the fixed orthodontic appliance.

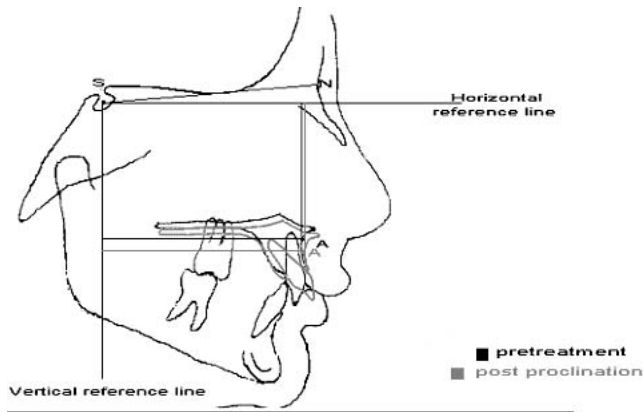


**Figure 1.** Cephalometric landmarks: Sella (S): The center of the pituitary fossa of the sphenoid bone. Nasion (N): The most anterior point of the frontonasal suture in the median plane. Anterior nasal spine (ANS): The tip of the median anterior bony process of the maxilla. Posterior nasal spine (PNS): The tip of the posterior nasal spine. Apical superius (AS): Root apex of the most prominent upper incisor. Incision superius (IS): The tip of the crown of the most prominent upper incisor. Prosthion (Pr): The most anterior-inferior point on the alveolar portion of the premaxilla, in the median plane, between the upper central incisors. Point A (A): A midline point located at the deepest point on the curve extending from ANS to Pr. Gonion (Go): The most inferior-posterior point at the angle of the mandible.

All cephalometric films used in this study were taken with the same x-ray machine (Orthophos Plus, Bensheim, Germany). Pretreatment lateral cephalometric films and postproclination lateral cephalometric films were traced by the same investigator by hand on acetate tracing paper, and 10 cephalometric landmarks were identified (Figure 1).

The following parameters were used in this study:

- Age
- Treatment duration: Time between pretreatment and postproclination lateral cephalograms
- Maxillary incisor angle to maxillary plane (Ui-Max): Angle formed by the intersection of the long axis of the maxillary incisor with the anterior nasal spine–posterior nasal spine line
- SNA angle: Angle formed by the intersection of the nasion-sella and the nasion–point A lines
- Maxillary-mandibular plane angle (MM angle): Angle formed by the intersection of the anterior nasal



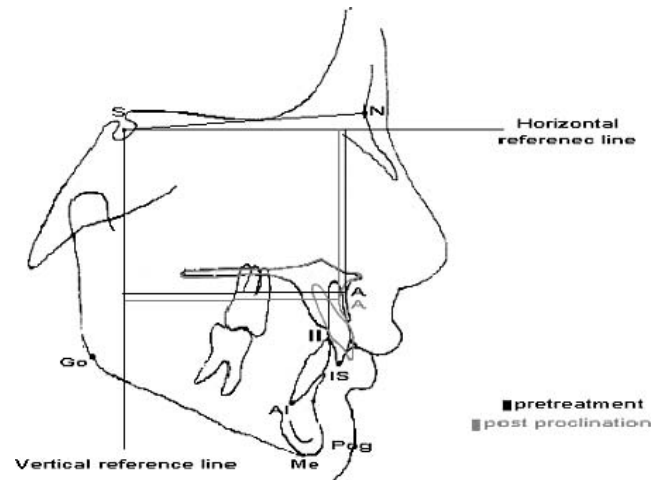
**Figure 2.** Total horizontal and vertical movement of point A. Superimposition on sella-nasion (SN) line at the sella (S).

spine–posterior nasal spine and the menton-gonion lines

- Change in Ui-Max: Change in the angle formed by the intersection of the long axis of the maxillary incisor and the anterior nasal spine–posterior nasal spine line between pretreatment and postproclination lateral cephalograms

The total change in the position of point A was measured by superimposing the pretreatment and postproclination lateral cephalograms on the sella-nasion (SN) line at the sella. On this superimposition, a horizontal line passing through the sella, 7 degrees from the SN line, was drawn to form a horizontal reference line. A line perpendicular to the horizontal reference line passing through the sella formed the vertical reference line (Figure 2). To determine the total horizontal displacement of point A relative to the cranial base, perpendicular lines were drawn from pretreatment point A and postproclination point A to the horizontal reference line. The distance between these two lines determined the anteroposterior component of the change in position of point A. To determine the total vertical displacement in the position of point A relative to the cranial base, two perpendicular lines were drawn from the pretreatment point A and the postproclination point A to the vertical reference line. The distance between the two lines revealed the vertical component of the change in position of point A.

The total change in position of point A was divided into skeletal change that resulted from growth (movement of the maxilla relative to the anterior cranial base) and local change that occurred in response to alveolar bone remodeling associated with orthodontic tooth movement of the upper incisors. To determine the local effect of alveolar bone remodeling associated with upper incisor proclination on the position of point A, the postproclination tracing of the maxilla was superimposed on the pretreatment tracing according to



**Figure 3.** Local horizontal and vertical movement of point A. Superimposition on anterior vault of the maxilla.

the Bolton template of maxillary superimposition,<sup>21</sup> using the anterior palatal contour (Figure 3). The anteroposterior and vertical components of local changes in the position of point A were determined using the same horizontal and vertical reference lines described above. All measurements were carried out with a gauge to the nearest 0.1 mm.

To calculate systematic and random errors, 10 cephalograms were retraced, and cephalometric landmarks were identified. Systematic error was not statistically significant. The random measurement error was calculated according to Dahlberg's double determination method.<sup>22</sup> For angular and linear cephalometric measurements, the error varied between 0.22 and 1.01 degrees and 0.16 and 0.38 mm, respectively.

### Statistical Analysis

Means and standard deviations were calculated for all variables using the Statistical Package for the Social Sciences (SPSS) for Windows (SPSS Inc, Chicago, Ill, USA). The change in point A was determined by using a one-sample Student's *t*-test. To examine the relationship between the change in position of point A and the remaining parameters, stepwise multiple regression analysis was performed, using the change in position of point A as a dependent variable and the remaining parameters as independent variables. *P* values less than .05 were considered significant.

### RESULTS

The average treatment duration was  $6.2 \pm 1.1$  months. Treatment changes are shown in Table 1. The total change in the position of point A was in a downward and forward direction. Total vertical displacement was 0.84 mm ( $P = .002$ ), and total hori-

**Table 1.** Treatment Changes

Variable	Treatment Change	Standard Deviation	Significance
SNA (degrees)	-0.12	0.5	.265
Ui to Max (degrees)	14**	7.1	.000
MM angle (degrees)	1**	1.9	.000
Total vertical displacement of point A (mm)	0.84*	1.1	.002
Total horizontal displacement of point A (mm)	0.45	1.1	.054
Local vertical displacement of point A (mm)	0.25	0.9	.154
Local horizontal displacement of point A (mm)	-0.60*	0.7	.001

\*  $P < .01$ ; \*\*  $P < .001$ .

zontal displacement was 0.45 mm ( $P = .054$ ). Assessment of local changes in point A revealed that the position of point A had moved mainly backward. The 0.25 mm local vertical displacement was not statistically significant ( $P = .154$ ), but the local horizontal displacement, which measured -0.6 mm, was statistically significant ( $P = .001$ ).

Results of the multiple regression analysis are shown in Table 2. Multiple regression analysis extracted one predictor for the change in position of Point A. This variable was the change in the upper incisor inclination relative to the maxillary plane ( $R^2 = 0.25$ ).

## DISCUSSION

The aim of this study was to investigate whether the position of point A is affected by local bone remodeling associated with proclination of the upper incisors in Class II division 2 malocclusion. Point A has different definitions.<sup>23</sup> In this study, Downs' definition was used because it is the most commonly used definition during tracing and cephalometric analysis.<sup>24</sup> Changes in the position of point A were divided into skeletal changes, which result from movement of the maxilla relative to the anterior cranial base (growth), and local changes, which are caused by local bone remodeling associated with orthodontic proclination of the upper anterior teeth. To study facial growth, Proffit<sup>21</sup> suggested that the most useful approach is to superimpose on the SN line, registering the template over the patient's tracing at the nasion rather than the sella if there is a difference in cranial base length. Houston<sup>25</sup> found that this line undergoes little change from growth or remodeling after about 6 years of age, when the sphenoethmoidal synchondrosis fuses; he also mentioned that unfortunately, the nasion does not in fact lie on the anterior cranial base but at the outer limit of the frontonasal suture, which does remodel with growth. Thus, an incorrect impression of the way the face has grown will be obtained if serial radiographs

**Table 2.** Multiple Regression Analysis of Change in the Position of Point A in Response to Alveolar Bone Remodeling

Independent Variable	Partial Correlation <sup>a</sup>	Significance
Age (years)	-0.171	.434
Treatment time (months)	-0.177	.419
Pretreatment Ui to Max (°)	-0.065	.769
Pretreatment SNA (°)	0.153	.485
Change in Ui to Max (°)	-0.504*	.012

<sup>a</sup> Minus sign indicates backward effect of point A.

\*  $P < .05$ .

Ui: Long axis of maxillary incisors; Max: Maxillary plan

are related to one another by means of this line with registration at the nasion. He suggested that superimposition on the SN line with registration at the sella usually yields a reliable picture of overall facial growth.

In this study, the total change in the position of point A was investigated by superimposing the pretreatment and postproclination cephalograms on the SN line at the sella. From the SN line, horizontal and vertical reference lines were drawn. The horizontal reference line was drawn 7 degrees at the SN line to simulate natural head position, and the vertical reference line was drawn from the sella perpendicular to the horizontal reference line.<sup>26</sup>

To differentiate local changes in the position of point A from total changes, superimposition on maxillary structures was performed. Unfortunately, the maxilla is subjected to extensive periosteal remodeling, and no really satisfactory stable sites are available for superimposition.<sup>25</sup>

Bjork and Skieller<sup>27</sup> studied movements of metallic implants inserted as markers in the jaws of children and found that the anterior surface of the zygomatic process of the maxilla undergoes little periosteal remodeling with growth. This structure is not always easily seen on a lateral radiograph.<sup>25</sup> During this study, it was not always possible to determine the anterior contour of the zygomatic process. Therefore, the Bolton template of maxillary superimposition based primarily on the anterior palatal contour was used instead.

Total changes in the position of point A, relative to the cranial base, were in a forward and downward direction; point A moved 0.46 mm anteriorly and 0.84 mm in a downward direction (Table 1). These findings are coincident with those of Bjork and Skieller,<sup>28</sup> who found that the maxilla grows downward, forward, and outward during childhood.

Local changes in the position of point A associated with proclination of the upper incisors during the first phase of treatment of Class II division 2 were downward by 0.25 mm, although this change was not statistically significant ( $P = .15$ ), and backward by 0.60 mm; this change was statistically significant ( $P < .001$ ). Mills<sup>29</sup> surprisingly found that there is no bone

deposition on the anterior aspect of the maxilla during growth. Proffit<sup>21</sup> showed that the maxilla grows downward and forward as bone is added in the tuberosity area posteriorly and at the posterior and superior sutures, with the anterior surfaces resorbing at the same time. It could be suggested that in this study, the local change in the position of point A resulted from both bone resorption associated with normal growth and bone remodeling associated with orthodontic tooth movement. Nevertheless because of the short period between the two cephalograms taken in this study (mean, 6.2 months), one can argue that the main part of this change was due to bone remodeling.

The results of this research are in agreement with those of Erverdi<sup>16</sup> and Arvysts.<sup>17,18</sup> Findings also are consistent with the suggestion of Nanda<sup>15</sup> that "it is important to remember that point A is affected by dental-alveolar movement."

Cleall and BeGole<sup>19</sup> reported that, during the examination of cephalometric data before and after treatment of Class II division 2 malocclusion, the SNA angle was reduced by a mean of 1.6 degrees. Results of our study show that, despite bone remodeling, the SNA angle actually did not significantly change during treatment (Table 1); this contradicts the findings of Cleall and BeGole,<sup>19</sup> who applied extraoral traction to correct the molar relationship "when necessary."

The results of multiple regression analysis revealed that there will be more backward movement in the position of point A as upper incisor proclination increases. This finding is explained by the fact that the greater the proclination in the upper incisors, the greater is the posterior movement of the root apices of the upper incisors, and, consequently, the greater is the bone remodeling.

## CONCLUSION

- The position of point A is affected by local bone remodeling associated with proclination of the upper incisor in Class II division 2 malocclusion, but this minor change does not significantly affect the value of the SNA angle.

## REFERENCES

1. Riedal RA. Esthetics and its relation to orthodontic therapy. *Angle Orthod.* 1950;20:168-178.
2. Jacobson A. The Wits appraisal of the jaw disharmony. *Am J Orthod.* 1975;67:125-138.
3. Jacobson A. Application of "Wits" appraisal. *Am J Orthod.* 1976;70:179-189.
4. Jacobson A. Update on the "Wits" appraisal. *Angle Orthod.* 1988;58:205-219.
5. Nanda RS. Growth changes in skeletal-facial profile and their significance in orthodontic diagnosis. *Am J Orthod.* 1971;59:501-513.
6. Binder RC. The geometry of cephalometrics. *J Clin Orthod.* 1979;13:258-263.
7. Oktay H. A comparison of ANB, WITS, AF-BF, and APDI measurements. *Am J Orthod Dentofacial Orthop.* 1991;99:122-128.
8. Taylor CM. Changes in the relationship of nasion, point A and point B and the effect on ANB. *Am J Orthod.* 1969;56:143-163.
9. Kim YH, Vietas JJ. Anteroposterior dysplasia indicator (an adjunct to cephalometric differential diagnosis). *Am J Orthod.* 1978;73:619-633.
10. Chang H. Assessment of anteroposterior jaw relationship. *Am J Orthod Dentofacial Orthop.* 1987;92:117-122.
11. McNamara JA. A method of cephalometric evaluation. *Am J Orthod.* 1984;86:449-469.
12. Nanda RS, Merrill RM. Cephalometric assessment of sagittal relationship between maxilla and mandible. *Am J Orthod Dentofacial Orthop.* 1994;105:328-344.
13. Hall-Scott J. The maxillary-mandibular planes angle (MM degree) bisector (a new reference plane for anteroposterior measurement of dental bases). *Am J Orthod Dentofacial Orthop.* 1994;105:583-501.
14. Ferrario VF, Serrao G, Cuisa V, Morini M, Sforza C. Cephalometric and in vivo measurements of maxillomandibular anteroposterior discrepancies. *Angle Orthod.* 2002;72:579-584.
15. Nanda R. *Biomechanics and Esthetic Strategies in Clinical Orthodontics.* UK: Elsevier; 2004:38-73.
16. Erverdi N. A cephalometric study of changes in point A under the influence of upper incisor inclination. *J Nihon University School of Dentistry.* 1991;33:160-165.
17. Arvysts MG. Nonextraction treatment of severe Class II division 2 malocclusion: part 1. *Am J Orthod Dentofacial Orthop.* 1990;97:510-521.
18. Arvysts MG. Nonextraction treatment of severe Class II division 2 malocclusion: part 2. *Am J Orthod Dentofacial Orthop.* 1991;99:74-84.
19. Cleall JF, BeGole EA. Diagnosis and treatment of Class II division 2 malocclusion. *Angle Orthod.* 1982;52:38-60.
20. British Standards Institute. *British Standard Incisor Classification. Glossary of Dental Terms.* BS 4492. London, UK: British Standard Institute; 1983.
21. Proffit WR. *Contemporary Orthodontics.* 2nd ed. St Louis, Mo: Mosby Year Book Inc; 1993:33-34, 174-175.
22. Dahlberg G. *Statistical Methods for Medical and Biological Students.* London, UK: George Allen and Unwin Ltd; 1940.
23. Kalafa JA, Kronman JH. A critical evaluation of cephalometric Point A and proposal of a more significant landmark. *Angle Orthod.* 1968;38:225-230.
24. Downs WB. Variations in facial relationships: their significance in treatment and prognosis. *Am J Orthod.* 1948;34:812-840.
25. Houston W, Tulley J, Stephans CD. *A Textbook of Orthodontics.* 2nd ed. Bristol, UK: Wright; 1992:95-116.
26. Macdonald KE, Kapust AJ, Turley PK. Cephalometric changes after the correction of Class III malocclusion with maxillary expansion/facemask therapy. *Am J Orthod Dentofacial Orthop.* 1999;116:13-24.
27. Bjork A, Skieller V. Growth of the maxilla in three dimensions as revealed radiographically by the implant method. *Br J Orthod.* 1979;4:53-64.
28. Bjork A, Skieller V. Facial development and tooth eruption: an implant study at the age of puberty. *Am J Orthod.* 1972;62:338-383.
29. Mills JR. A clinical look at facial growth. *Br J Orthod.* 1983;10:58-71.