

Case Report

Face and Neck Dermatitis from a Stainless Steel Orthodontic Appliance

Minna Ehrnrooth^a; Heidi Kerosuo^b

ABSTRACT

Although nickel is the most common cause of contact allergy, nickel-containing orthodontic appliances seldom cause adverse reactions that result in discontinuation of treatment. We report on an eruption of dermatitis in the face and neck of an adult female patient after placement of a rapid maxillary expansion appliance (RME). Because the patient suspected nickel allergy, her tolerance to the appliance material was tested intraorally before treatment by cementing bands on four teeth for a week. No visible adverse reactions were seen during the test. One week after cementation of the RME appliance, the patient reported strong itching of the face and a red rash. Clinical examination showed itchy papular erythema on the face and neck. No intraoral reactions or symptoms were present. The RME appliance was removed, and symptoms disappeared in 4 to 5 days. The patient was referred for a nickel patch test, which gave a strong positive result. Adverse patient reactions of potential allergic origin should be diagnosed carefully, and their possible impact on further treatment should be evaluated accordingly. (*Angle Orthod.* 2009;79:1194–1196.)

KEY WORDS: Nickel allergy; Orthodontics

INTRODUCTION

Fixed orthodontic appliances generally are made of stainless steel containing 8% to 12% nickel. Biodegradation of these appliances takes place during the course of treatment, and small quantities of metal ions, including nickel, are released into the oral cavity.¹ Potential induction of nickel sensitization and elicitation of an allergic reaction by nickel leaching from the orthodontic appliances have been matters of general concern and the topic of several studies.^{2–4}

Of all skin sensitizers, nickel is considered the number one cause of contact allergy, especially in women in industrialized countries. According to patch test–verified data, this condition affects approximately 10% to 30% of females and 1% to 3% of males, depending on age and population groups.^{5–7} Given the high prevalence of nickel allergy, visible adverse reactions to metallic orthodontic appliances are detected surpris-

ingly infrequently (in 0.2% to 0.4% of patients), and studies have shown that most patients who are known to be nickel sensitive can be treated with nickel-containing orthodontic appliances without hypersensitivity reactions.^{2,4,8}

Evidence shows that the elicitation threshold of a nickel-allergic reaction varies among individuals and individually over time.^{9–11} Elicitation of this reaction depends on the conditions under which nickel exposure occurs and is affected by such factors as hapten concentration on the contact area, open or occluded exposure, the presence of an irritant, and individual degree of contact allergy.^{9,10}

CASE REPORT

A 34-year-old woman was referred to the oral clinic of Vaasa Central Hospital in western Finland because of symptoms of temporomandibular joint (TMJ) disorder and occlusal disorder. The occlusal diagnosis included bilateral cross-bite involving second premolars and first and second molars on both sides, as well as severe crowding of the mandibular incisors. Mild crowding of the maxillary incisors was also present. Angle's classification was super Class I, with tendency toward Class III. In the functional analysis, clicking of the left TMJ during opening and considerable tenderness of the main masticatory muscles on palpation and during biting were discovered. The medical history included hay fever with antihistamine medication, suspected nickel allergy, and regular smoking.

^a Employee Orthodontist, Oral Clinic, Vaasa Central Hospital, Vaasa, Finland.

^b Professor, Institute of Dentistry, University of Turku, Finland; Institute of Clinical Dentistry/Faculty of Medicine, University of Tromsø, Tromsø, Norway.

Corresponding author: Dr Heidi Kerosuo, Faculty of Medicine, Institute of Clinical Dentistry, University of Tromsø, N-9037 Tromsø, Norway
(e-mail: heidi.kerosuo@uit.no)

Accepted: January 2009. Submitted: September 2008.

© 2009 by The EH Angle Education and Research Foundation, Inc.

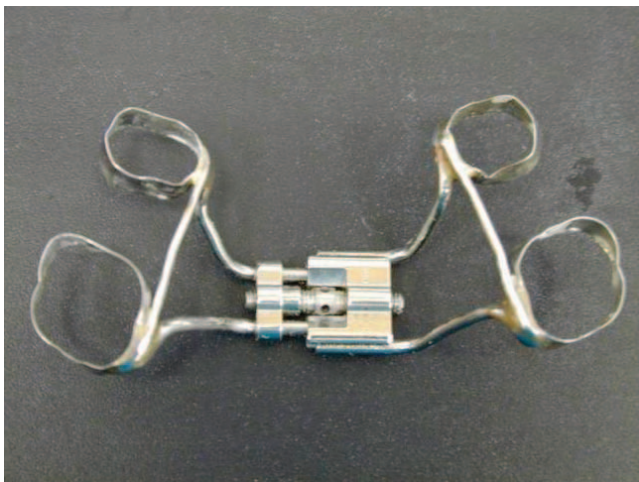


Figure 1. Rapid maxillary expansion appliance (RME).

The treatment plan consisted of rapid maxillary expansion followed by combined surgical and orthodontic treatment with the use of fixed appliances. Orthodontic treatment was started in January with surgically assisted rapid maxillary expansion (RME). The RME appliance consisted of a stainless steel expansion screw Hyrax II (Dentaurum 1.000 SS; 1.003 SS/remanium; 1.002 SS, nickel content 8% to 10%; Dentaurum, Ispringen, Germany) and four bands (Trimline 18/8 SS; Ormco Corp, Orange, Calif), which were soldered to the arms of the screw in the laboratory (Figure 1). Before the appliance was inserted, the patient's eventual allergic response to the appliance material was tested by fixing four identical stainless steel orthodontic bands to the patient's upper molars and premolars for 7 days. No adverse reactions were detected during the test period.

One week after cementation of the RME appliance, the patient awoke at night to heavy itching on the face and detected a red rash with tiny papules on the chin, cheeks, and neck. She also reported symptoms in the eyes and described them as similar to those caused by birch pollen. Clinical examination on the same day showed itchy papular erythema, which covered the skin from the cheeks to the chest (Figure 2). No intra-oral objective or subjective symptoms were present. The RME appliance was removed, and symptoms disappeared in 4 to 5 days. Two weeks later, the patient experienced a similar type of reaction with itchy rash and vesicles extending far from the contact site, caused by her old imitation-jewelry necklace, the wearing of which she had previously tolerated. The patient declined further orthodontic treatment because of the hypersensitivity reactions.

Patch tests for metals were performed at the dermatology clinic of the central hospital with 5% nickel sulphate (TROLAB E003 nickel sulphate 6 H₂O in

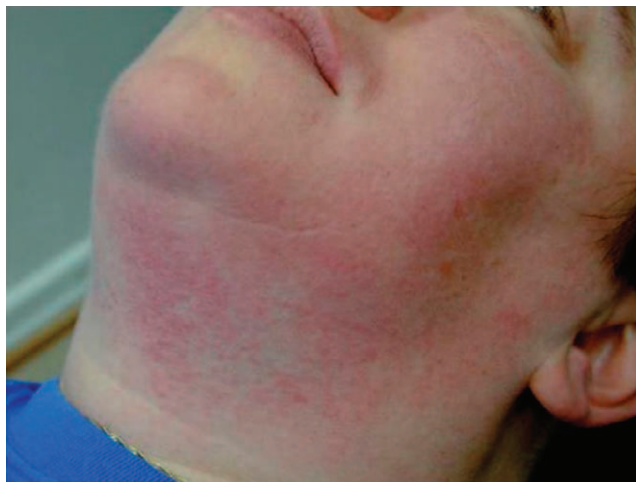

Figure 2. Allergic reaction on the skin caused by wearing the rapid maxillary expansion appliance (RME).

white petrolatum), 1% cobalt chloride, and 1% palladium chloride. Test results were read on the four and seventh days after placement of the patches. The patient showed a strong positive (++) reaction to both nickel and cobalt, and palladium showed positive (+).

DISCUSSION

Although nickel is a common contact allergen, strong hypersensitivity reactions to appliances, leading to discontinuation of treatment, are infrequent in orthodontics.^{2,4,8} The clinically common precaution of testing the sensitivity of the patient before providing actual treatment by fixing a few bands/brackets on the teeth for a period of time⁸ was not effective enough to elicit a hypersensitivity reaction to the appliance material in our patient. Possible explanations could be the considerably smaller total amount of metal in the test compared with that in the real appliance, the relatively short exposure time, and the absence of mechanical irritation from smooth bands.⁹⁻¹¹ Regular smoking recently has been suggested to play a role in contact allergic reactions as well, although the mechanisms are not known.¹²

When two metals come in contact, corrosion of the less precious metal is increased. Silver soldering has been shown to increase nickel release from stainless steel arch wires.¹³ The RME appliance, because it is made of stainless steel and includes several silver-soldering seams, may have leaked nickel to an extent that exceeded the individual threshold of our patient. Whether the allergic reaction would have occurred similarly to that seen with standard fixed appliances can only be speculated upon. As to orthodontic brackets and arch wires, gold-plated devices are available in the market and may be an option for nickel-allergic patients in selected cases, whereas individual gold

plating of the RME appliance is not considered a realistic option.

It may seem surprising that no reactions were found close to the appliance intraorally. However, several studies have reported that hypersensitivity reactions from orthodontic appliances manifest more often on the skin than in the oral mucosa.^{2,8} Salivary flow is likely to reduce the concentration of nickel ions released from appliances on the oral mucosa, and thus the provocation threshold may not be exceeded. Moreover, the immunology of the oral mucosa may differ from that of the skin, because the oral mucosa is potentially less reactive than the skin to contact allergens such as nickel.¹⁰

According to current evidence, orthodontic treatment does not increase the risk of nickel allergy; neither has nickel allergy been shown to be an obstacle to treatment with fixed appliances made of stainless steel.^{14,15} Yet, although most nickel-allergic patients can be treated without discomfort, individual variation exists, and orthodontic treatment occasionally may even aggravate the existing allergy, as may have happened in our patient.^{4,8,15,16} Hence, all reactions of potentially allergic origin should be sought carefully and diagnosed with patch testing, and their impact on the treatment plan should be evaluated accordingly.

REFERENCES

1. Eliades T, Athanasiou AE. In vivo aging of orthodontic alloys: implications for corrosion potential, nickel release, and biocompatibility. *Angle Orthod.* 2002;72:222–237.
2. Jacobsen N, Hensten-Pettersen A. Changes in occupational health problems and adverse patient reactions in orthodontics from 1987 to 2000. *Eur J Orthod.* 2003;25:591–598.
3. Genelhu MC, Marigo M, Alves-Oliveira LF, Malaquias LC, Gomez RS. Characterization of nickel-induced allergic contact stomatitis associated with fixed orthodontic appliances. *Am J Orthod Dentofacial Orthop.* 2005;128:378–381.
4. Schuster G, Reichle R, Bauer RR, Schopf PM. Allergies induced by orthodontic alloys: incidence and impact on treatment. *J Orofac Orthop.* 2004;65:154–157.
5. Mortz CG, Lauritsen JM, Bindslev-Jensen C, Andersen KE. Nickel sensitization in adolescents and association with ear piercing, use of dental braces and hand eczema. *Acta Derm Venereol.* 2002;82:359–364.
6. Mattila L, Kilpeläinen M, Terho EO, Koskenvuo M, Helenius H, Kalimo K. Prevalence of nickel allergy among Finnish university students in 1995. *Contact Dermatitis.* 2001;44:218–223.
7. Meding B. Epidemiology of nickel allergy. *J Environ Monit.* 2003;5:188–189.
8. Kerosuo H, Dahl JE. Adverse patient reactions during orthodontic treatment with fixed appliances. *Am J Orthod Dentofacial Orthop.* 2007;132:789–795.
9. Menné T. Quantitative aspects of nickel dermatitis: sensitization and eliciting threshold concentrations. *Sci Total Environ.* 1994;148:275–281.
10. Fisher LA, Menné T, Johansen JD. Experimental nickel elicitation thresholds—a review focusing on occluded nickel exposure. *Contact Dermatitis.* 2005;52:57–64.
11. Emmett EA, Risby TH, Jiang L, Ng SK, Feinman S. Allergic contact dermatitis to nickel: bioavailability from consumer products and provocation threshold. *J Am Acad Dermatol.* 1988;19:314–322.
12. Linneberg A, Nielsen NH, Menné T, Madsen F, Jorgensen T. Smoking might be a risk for contact allergy. *J Allergy Clin Immunol.* 2003;111:980–984.
13. Berge M, Gjerdet MR, Erichsen ES. Corrosion of silver soldered orthodontic wires. *Acta Odontol Scand.* 1982;40:75–79.
14. Jensen CS, Lisby S, Baadsgaard O, Byrialsen K, Menné T. Release of nickel ions from stainless steel alloys used in dental braces and their patch test reactivity in nickel-sensitive individuals. *Contact Dermatitis.* 2003;48:300–304.
15. Kerosuo H, Kullaa A, Kerosuo E, Kanerva L, Hensten-Pettersen A. Nickel allergy in adolescents in relation to orthodontic treatment and piercing of ears. *Am J Orthod Dentofacial Orthop.* 1996;109:148–154.
16. Schultz JC, Connelly E, Glesne L, Warchaw EM. Cutaneous and oral eruption from oral exposure to nickel in dental braces. *Dermatitis.* 2004;15:154–157.