

# Case Report: Churg-Strauss Syndrome in an 8-Year-Old Girl

Sara Kashef,<sup>1</sup> Soheila Alyasin,<sup>1</sup> Mojgan Kiani,<sup>1</sup> Reza Amin,<sup>1</sup> and Abdolvahab Alborzi<sup>2</sup>

<sup>1</sup>Department of Immunology and Allergy, Nemazee Hospital,

<sup>2</sup>Department of Pediatric Infectious diseases, Nemazee Hospital, Shiraz University of Medical Sciences,  
Shiraz, Iran

## ABSTRACT

Churg-Strauss Syndrome (CSS) is a small vessel granulomatous vasculitis that characteristically affects the middle age group and is extremely rare in children. We describe an 8-year-old girl with a prolonged history of cough and eosinophilia that initially was labelled as pulmonary tuberculosis, but after complementary assays, associated with skin biopsy, eosinophilic fibrinoid vasculitis, CSS was eventually diagnosed. In this case, due to her young age and more prevalence of infectious lung diseases in our area, there was a few months delay for correct diagnosis and treatment. After meeting the CSS criteria the appropriate treatment was started and her condition improved.

**Keywords:** Childhood, Churg-Strauss Syndrome (CSS), Eosinophilia

## INTRODUCTION

Vasculitis or blood vessel wall inflammation is the most difficult rheumatologic disease to be classified during childhood.<sup>1</sup> It can be presented as a prominent sign of a few syndromes or may be part of connective tissue disorders.<sup>1,2</sup> The onset of less common vasculitis in children (such as Churg-Strauss Syndrome) is slow, over weeks to months, thus making difficulty in diagnosis.

Churg- Strauss Syndrome is an uncommon vasculitis in children. The etiology is unknown,<sup>1,3,4</sup> but CSS overlaps clinically and also pathologically with many systemic, allergic and infectious diseases. In this report we reviewed the medical course of an-8-year old girl with CSS which had an overlap with infectious diseases.

## CASE REPORT

In April 2002, an-8-year- old girl was admitted with chief complaints of fever, cough and night sweating of 2 months duration. She was referred from a health center with the impression of pulmonary tuberculosis. At local health center, some investigations had been done for her, such as: cell blood count (CBC), erythrocyte

sedimentation rate (ESR), sputum smear and culture, PPD-test, and chest x-Ray (CXR). The results were in normal limits for CBC and differentials, and negative in sputum smear for tuberculosis. She had 11mm induration on PPD-test, and some pulmonary infiltrations. Then she was treated with anti-tuberculosis drugs (Isoniazid +Rifampin) due to the high prevalence of tuberculosis (TB) in that area for two months with a significant improvement. Her problems had flared up in a few days before her first admission in our hospital (Nemazee Hospital).

In her past history, she had been hospitalized at 7-month of age for pneumonia. She had also experienced recurrent upper respiratory infections. In her family history she had a grand mother with asthma.

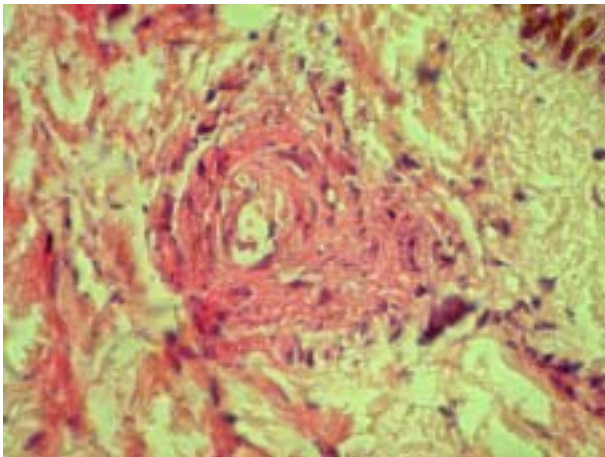
Physical examination revealed a well developed undernourished child with no significant respiratory distress or cyanosis. Chest auscultation showed wheezing and rales bilaterally. Heart sounds were normal, and no organomegaly was detected. Her white blood cell count was 26800 cell/mm,<sup>3</sup> with 15% neutrophil, 11% lymphocytes, 71% Eosinophils and her hemoglobin was 12.4 g/dL. ESR was 41 mm/h, and the chest x-Ray showed consolidation at right upper lobe with air-bronchogram. In addition, the CT scan reported a necrotizing pneumonia at right upper lobe without mediastinal lymphad-

enopathy. The bronchial lavage was negative for mycobacterium TB. In the hospital course, she had developed maculopapular skin rashes on the frontal and postauricular areas. She was assessed for her eosinophilia too.

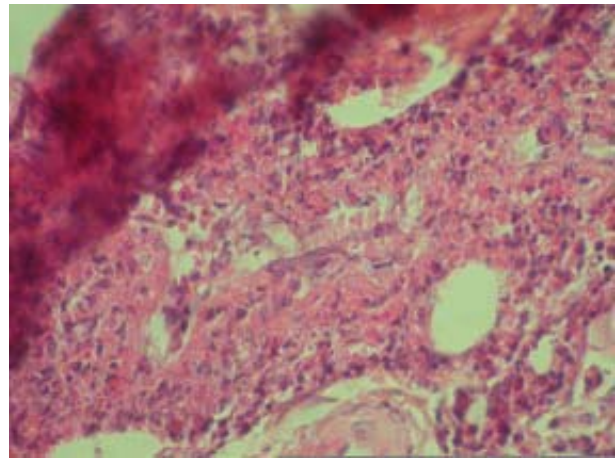
The bone marrow aspiration showed a mild hypercellularity and marked eosinophilia. Stool exam was unremarkable. She was diagnosed as a case of idiopathic eosinophilia and prednisolone was added to her anti-TB drug regimen. She left the hospital with a considerable improvement.

20 days later, she came back again with cough, respiratory distress and maculo-papular rashes appearing on her face and extremities. In contrast to previous admission, she had also hepatosplenomegaly. Her white blood cell count was 21600 cell/mm<sup>3</sup> with a 30% eosinophil count. At this stage, a vasculitic syndrome, was suggested due to simultaneous presentation of respiratory distress, skin rash, organomegaly and leukocytosis with severe eosinophilia.

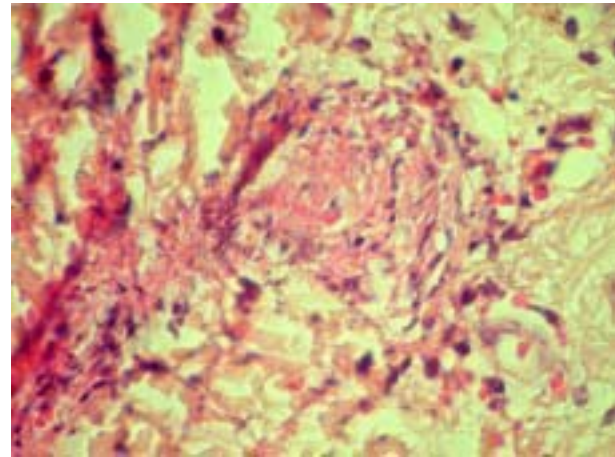
A skin biopsy and determination of IgE level was recommended. Her skin biopsy revealed fibrinoid necrosis and leukocytoclastic vasculitis with frequent eosinophil infiltration consistent with CSS but other vasculitis syndromes such as Wegner granulomatosis and polyarthritis nodosa were also considered (Figures 1,2,3). Her IgE level was 1250 Iu/ml. In addition paranasal sinus CT scan was undertaken which showed bilateral maxillary sinus haziness. As four criteria existed for CSS, cyclophosphamide (500 mg/m<sup>2</sup>, IV) was started due to a progressive pulmonary disease. She showed a dramatic response to the immuo suppressive therapy and left the hospital with significant improvement. However the family could not keep a heading at OPD clinic and she



**Figure 1.** The signs of vasculitis in a supradermal vessel. Eosinophils infiltration is present at the muscular layer of vessel wall. Thrombosis also exists but has not occluded the lumen.



**Figure 2.** Occluded vessel by thrombosis on the base of vasculitis is seen in dermis. The endothelium was elevated due to inflammatory eosinophil infiltration.



**Figure 3.** Inflammation on subepiderma, many inflammatory cells (prominently eosinophils) present in derma.

had frequent flares of disease due to discontinuing the medication.

### DISCUSSION

Churg-Strauss Syndrome is a small vessel vasculitis which was first described in 1951. Churg and Strauss presented this syndrome with severe asthma, fever, eosinophilia and vasculitis in various organs. ACR then classified it by seven criteria.<sup>1,5,6</sup>

The diagnosis was based on the presence of four or more criteria, and was confirmed by lung, renal or skin biopsy. This syndrome is very unusual in children and is mostly seen in the third to five decades of life in adults.<sup>1,2,5</sup>

The literature since 1951 demonstrated only 10 patients who were described by Louthrenoo et al, and in 2001 by Cassidy who reported ten patients among them seven patients were similar to those reported by Louthrenoo. It seems that the reported cases in children from 1951, must be less than fifteen, and our patient is considered as the fourteenth case.

CSS in adults has been well described and is divided into 3 phases:

1. Prodromal phase consisting allergic rhinitis and asthma which could persist for 3-8 years.
2. The second phase consisted of eosinophilia of more than 10%
3. Third or vasculitic phase (consists of: fever, rash, arthralgia,...).<sup>7-9</sup>

In children, the diagnosis should always be considered in severe asthmatic children with fever and significant eosinophilia.

In childhood, presentation of the disease with prominence of respiratory symptoms such as in our patient, other more common respiratory diseases such as infectious respiratory diseases should be considered. Tuberculosis pneumonitis with different presentations also remains a dilemma.<sup>10</sup>

Other more common chronic lung problems with eosinophilia are loffler syndrome and allergic bronchopulmonary aspergillosis.

In this case, we could document vasculitis after obtaining a skin biopsy specimen and the treatment was carried out with steroids and immunosuppressives.

All reported cases were recommended for prolonged follow up and low doses of steroids for a long period and slow tapering, because severe flare up was seen with rapid tapering of drugs. We also observed this problem in our patient.

In conclusion we recommend that CSS should be considered as a possibility in any case of severe asthma in childhood. A registration center for CSS and other rare childhood vasculitis is a need in our country (Iran).

## ACKNOWLEDGMENT

We would like to thank the Center for Development of Clinical Research of Nemazee Hospital and Dr. Davood Mehrbani for editorial support.

## REFERENCES

1. Cassidy JT, Patty RE. Vasculitis. In: Textbook of pediatric rheumatology. Philadelphia: W.B. Saunders, 2001, 608-612.
2. Louthrenoo W, Norasetthada A, Khunamornpong S, Sreshthaputra A, Sukitawut W. Childhood churg-strauss syndrome. *J Rheumatol* 1999; 26(6):1387-93.
3. Lin TL, Wang CR, Liu MF, Chen PC, Shan YS, Jin YT, et al. Multiple colonic ulcers caused by churg-strauss syndrome in a 15-year-old girl. *Clin Rheumatol* 2001; 20(5):362-4.
4. Wang SJ, Yang YH, Lin YT, Tsai MJ, Chiang BL. Childhood churg-strauss syndrome report of a case. *J Microbiol Immunol Infect* 2000; 33(4):263-6.
5. Masi AT, Hunder GG, Lie JT, Michel BA, Bloch DA, Arend WP, et al. The American college of Rheumatology 1990 Criteria for the classification of Churg-Strauss syndrome. *Arthritis Rheum* 1990; 33(8):1094-100.
6. Frayha RA. Churg-Strauss syndrome in a child. *J Rheumatol* 1982; 9:807-9.
7. Lanhan JG. Churg Strauss Syndrome. *Br J Hosp Med* 1992; 47:667-673.
8. Lanham JG, Elkon KB, Pusey CD, Hughes GR. Systemic vasculitis with asthma and eosinophilia. *Medicine* 1984; 63(2):65-81.
9. Case records of the Massachusetts General hospital. Weekly clinicopathologic exercises A 32-year-old woman with asthma and eosinophilia and a sensorimotor neuropathy. *N Engl J Med* 1990; 323(12):812-22.
10. Brigden ML. A practical workup for eosinophilia. You can investigate the most likely causes right in your office. *Postgrad Med* 1999; 105(3):193-4, 199-202, 207-10.