

S.R. Hosseini MD¹
 B. Mohtashami MD²
 M. Ghasem Mohseni MD³
 Sh. Gooran MD⁴
 Sh. Dadgari MD⁵

1. Assistant Professor, Department of Urology, Sina Hospital, Tehran University of Medical Sciences, Tehran, Iran.
 2. Associate Professor, Department of Radiology, Imam Hossein Hospital, Shahid Beheshti University of Medical Sciences, Tehran, Iran.
 3. Associate Professor, Department of Urology, Sina Hospital, Tehran University of Medical Sciences, Tehran, Iran.
 4. Department of Urology, Sina Hospital, Tehran University of Medical Sciences, Tehran, Iran.
 5. Department of Radiology, Imam Hossein Hospital, Shahid Beheshti University of Medical Sciences, Tehran, Iran.

Corresponding Author:
 Seyed Reza Hosseini
 Address: Department of Urology, Sina Hospital, Hassan abad square, Hafez Street, Tehran, Iran.
 Tel: +98-21-6701041
 Fax: +98-21-6701041
 E-mail: srhosseini@tums.ac.ir

Received March 16, 2006;
 Accepted after revision July 31, 2006.

Summer 2006; 4: 43-45

Malacoplakia as a Renal Mass

Renal malacoplakia is a rare benign disease. Affected patients are often the debilitated, immunosuppressed, or those with chronic disease. On CT scan, foci of malacoplakia appear less dense than the enhanced surrounding parenchyma. Radiologically, renal malacoplakia can resemble renal cell carcinoma (RCC), and thus should be considered as a differential diagnosis of RCC.

We report an unusual presentation of renal malacoplakia.

Keywords: malacoplakia, kidney, CT scan

Introduction

Malacoplakia, a Greek word meaning “soft plaque”, is an unusual inflammatory disease that was originally described to affect the bladder, but has been found to affect the genitourinary and gastrointestinal tracts, skin, lungs, bone, and mesenteric lymph nodes.¹

Malacoplakia is a rare benign disease, with no specific clinical picture. The diagnosis is histological. The pathophysiology is infectious in association with localized dysfunction of macrophages. The treatment primarily consists of antibiotics and cholinergic drugs. Surgical removal is necessary only when the lesion is locally destructive.²

Case Report

A 63-year-old male patient presented with flank pain of one month duration and microscopic hematuria. His past medical and family histories were not significant. The patient was not anemic, and the physical examination was normal, and no palpable abdominal pathology was detected.

The symptoms were not characteristic enough for making a clinical diagnosis, so that a preoperative diagnosis of renal cell carcinoma was assumed.

Urine analysis showed RBC 20–25/ hpf and WBC1–2/hpf. Blood cell count and liver function tests were normal.

Chest x-ray appeared normal. On ultrasonography, the left kidney was enlarged, bearing a heterogenic mass of 4×6 cm without calcification, in the middle and the upper pole of left kidney. On CT scan with contrast, an enhanced heterodense mass, 4.5×6.5 cm, was in the anterior and middle parts of the left kidney, which caused indentation of the renal pelvis posteriorly. There were no lymphadenopathies or renal vessels involvement, but perirenal fat was involved and metastatic lesion were seen (Figures 1a and b).

At operation, the enlarged left kidney was firm, and perinephric inflammation and two enlarged perihillar lymph nodes were evident. Radical nephrectomy was performed.

In gross pathology, the kidney measured 10×6×4 cm. The renal cut surface showed a yellow lesion, 6 cm in its greatest diameter, extending from the middle part of the kidney to its upper pole. The microscopic view showed renal tissue

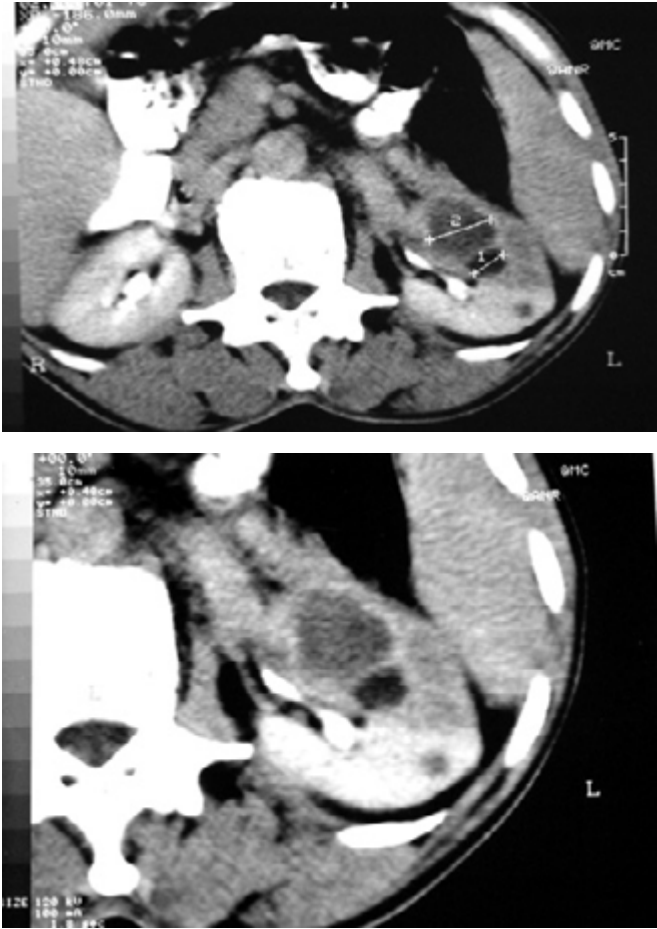


Fig 1. a) Abdominal contrast-enhanced CT scan demonstrating 4.5 x6.5 cm renal mass in the left kidney. The mass without calcification. **b)** Abdominal contrast-enhanced CT scan showing heterodense mass without lymphadenopathy and renal vessels involvement, although perirenal fat was involved.

with multiple foci of severe chronic interstitial inflammation with complete loss of tubules and glomeroli. The inflammatory cells consisted predominantly of mature small lymphocytes, many scattered isolated histiocytes in which the cytoplasm was filled by concentrate lamellated PAS-positive bodies (Michaelis-Gutman bodies) as well as some PMNs. Sections from the resected lymph nodes showed reactive follicular hyperplasia (Figures 2a and b).

Discussion

Malacoplakia is a rare granulomatous disorder characterized by inflammatory benign tumors composed primarily of macrophages and plasma cells.³ There have been more than 50 reported cases of renal malacoplakia.⁴ Diagnosis is made by biopsy, identifying the characteristic lesions that contain large histio-

cytes, known as Von Hansemann cells, and small basophilic extracytoplasmic or intracytoplasmic calcu-lospherules called Michaelis-Gutmann bodies which are pathognomonic.

Malacoplakia is a disease that predominantly affects old women. The female-to-male ratio with urinary tract malacoplakia is 4:1. Most patients are older than 50.⁵ The association between malacoplakia and chronic urinary tract infections (UTI) is strong, with 90% of cases having positive cultures for gram-negative enteric bacteria, mostly *E. coli*.^{5,6}

The clinical presentation of malacoplakia varies with the site of involvement. Concurrent systemic illnesses or other debilitating conditions are not infrequent. Bladder involvement is suggested by hematuria and dysuria. Renal lesions may present with colicky flank pain, fever and a flank mass.⁵

In general, the symptoms of malacoplakia can

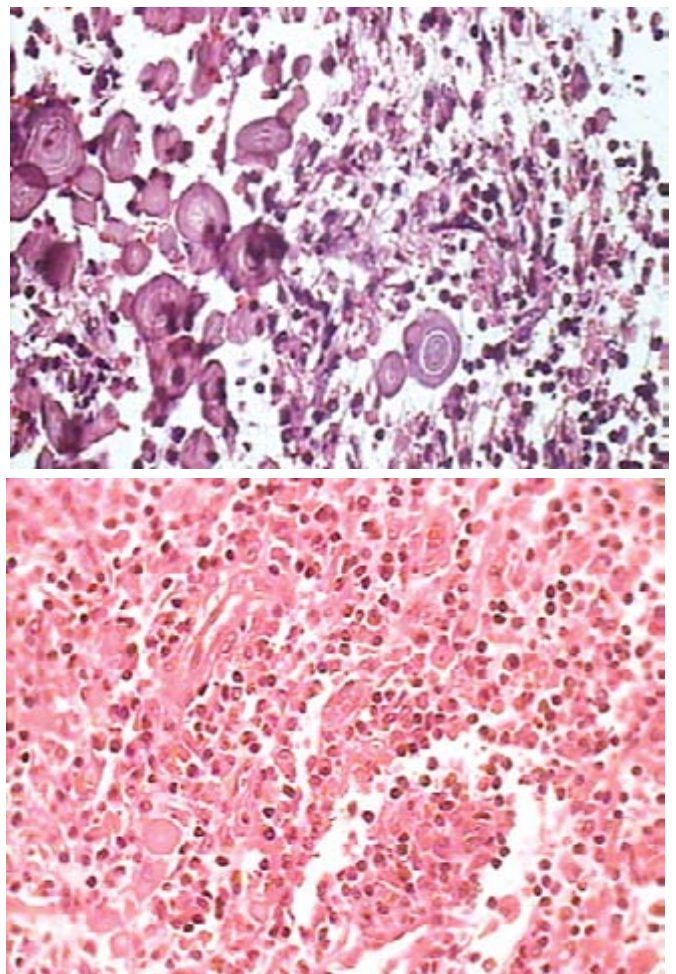


Fig 2. a) PAS positive bodies (Michaelis-Gutman bodies) in renal parenchyma (x40). **b)** Multifocal severe chronic inflammation. Inflammation leading to loss of tubules and glomeroli (x40).

mimic those of several other more common urinary states like UTI, as well as genitourinary malignancies.

In patients with lower tract symptoms, cystoscopy usually reveals mucosal plaques or nodules. As the disease progresses, these lesions can become large fungating masses. At this point, IVU may reveal filling defects in the affected portions of the collecting system. The inflammatory mass can also cause urethral obstruction and hydronephrosis. On ultrasonography, multiple foci of renal involvement may appear as renal enlargement and a general increase in the parenchymal echotexture. On CT scan, hypodense parenchymal masses may be seen focally or diffusely.⁷ CT scan can also demonstrate any extension to the outside of the urinary tract. Angiography generally shows a hypovascular mass with peripheral neovascularity.⁸

Successful medical therapy depends on treatment with antibiotics to achieve an adequate intracellular drug level. Although multiple long-term antimicrobial agents, including many antituberculosis agents have been used, sulfonamides, rifampin doxycycline and trimethoprim are thought to be especially useful for their higher intracellular bactericidal activity.⁹ Although somewhat controversial, bethanechol and ascorbic acid have been recommended to enhance the

phagolysosomal activity.¹⁰ The treatment of ureteral plus renal disease, however, usually involves nephroureterectomy plus antibiotic therapy.⁶ When renal disease is bilateral, the prognosis is poor and patients rarely survive beyond 6 months.

References

1. Anthony J.Schaeffer. Infections of urinary tract. In: Walsh, Retic, Vaughan. Campbell's Urology. 8th ed. Philadelphia: Saunders, 2002: 565-566.
2. Ben Amna M, Hajri M, Oumaya C, Anis J, Bacha K, Ben Hassine L et al. Genito- urinary malacoplakia. *Ann Urol.* 2002; 36(6); 388-91
3. Simon N. Bacterial Infections of the Genitourinary Tract In: Emil A. Tanagho, Jack W. McAninch. *Smith's General Urology.* 15th ed. New York: McGraw-Hill; 2000: 251-252.
4. Tynski, MacLennan Z, Gregory T. Renal pseudotumors. *J Urol* 2005; 173(2): 600.
5. Stanton MJ, Maxted W. Malakoplakia: a study of the literature and current concepts of pathogenesis. *J Urol* 1981; 125:139-146.
6. Long Jp, Althausen Af. Malacoplakia: a 25-year experience with a review of the literature. *J Urol* 1989; 141:1328-1331
7. Hartman DS Davis CJ Jr, Lichtenstein JE, Goldman SM. Renal parenchymal malakoplakia. *Radiology* 1980; 136:33-42
8. Cavins JA, Goldstein AMB: Renal Malacoplakia. *Urology* 1977; 10:155-158.
9. Maderazo EG, Berlin BB, Marhardt C. Treatment of malacoplakia with trimethoprim- sulfamethoxazole. *Urology* 1979; 13:70-73
10. Abdou NI, NaPombejara C, Sagawa A, Ragland C, Stechschulte DJ, Nilsson U et al: Malakoplakia: Evidence of monocyte abnormality correctable by cholinergic agonists in vitro and in vivo. *N Engl J Med* 1977; 297:1413-1419.