

An Unusual Case of Bilateral Maxillary and Mandibular Supernumerary Teeth

Y. Refoua^{1,2✉}, M. Arshad³

¹Assistant Professor, Department of Oral and Maxillofacial Surgery, Faculty of Dentistry, Medical Sciences/ University of Tehran, Tehran, Iran

²Assistant Professor, Dental Research Center, Medical Sciences/ University of Tehran, Tehran, Iran

³Dentist, Private Practice

Abstract:

The presence of supernumerary teeth is not uncommon in the general population. They occur more frequently in patients with a family history of such teeth but it is rare to find multiple supernumeraries in individuals with no other associated disease or syndrome. There have been very few documented cases of bilateral maxillary and mandibular supernumeraries, distal to the third molars. Supernumerary teeth may affect the permanent dentition if not removed. A 24 year-old male with five distomolars and a complete dentition is presented.

Key Words: Fourth molars; Fifth molars; Distomolars; Supernumerary molars

Journal of Dentistry, Tehran University of Medical Sciences, Tehran, Iran (2006; Vol: 3, No.3)

✉ Corresponding author:

Y. Refoua, Department of Oral and Maxillofacial Surgery, Faculty of Dentistry, Tehran University of Medical Sciences, Tehran, Iran.

yoshiaho_refoua@yahoo.com

Received: 23 November 2005

Accepted: 10 May 2006

INTRODUCTION

Teeth serve an important role in chewing, phonetics, and the morphological make-up of the face [1]. Hyperdontia is the development of an increased number of teeth in the primary or permanent dentition, and the additional teeth are termed supernumerary. The majority of supernumerary teeth are considered to develop as a result of horizontal proliferation or a hyperactivity of the permanent or deciduous dental lamina. Supernumerary teeth can have normal morphology and are referred to as “supplementary teeth”. On the other hand, these teeth may be rudimentary in shape and smaller in size [1-3].

The incidence of supernumeraries is reported to be 1-2% of the general population. They are twice more common in the permanent than in the primary dentition. Approximately 90% of cases present in the maxilla with a strong predilection for the incisor region (mesiodens),

followed by maxillary and mandibular fourth molars (distomolars or distodens), premolars, canines and lateral incisors [3,4]. Hyperdontia exhibits a 2:1 male predominance [5].

Unerupted supernumeraries are sometimes associated with cleft palates, as well as certain disorders such as cleidocranial dysplasia, and Gardner syndrome [4]. However it is rare to find multiple supernumeraries in individuals with no other associated disease or syndrome [5].

Bilateral fourth molars affecting both jaws are extremely rare. We describe the occurrence of non-syndromic multiple distomolars in a male patient [4,6,7].

CASE REPORT

A 24-year-old male was referred to the Department of Oral and Maxillofacial Surgery, Faculty of Dentistry, Tehran University of Medical Sciences for a routine check-up of the

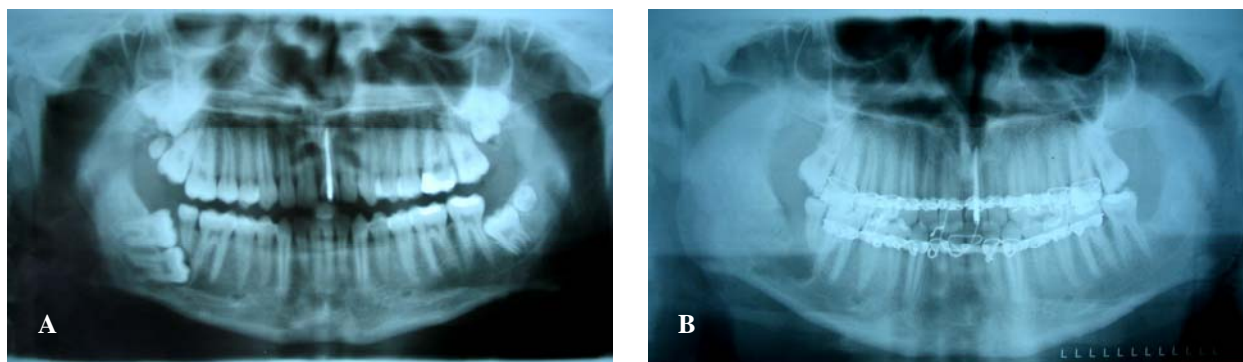


Fig.1: Radiographs of patient with bilateral supernumerary teeth before (A) and after (B) surgery.

mandibular third molars. There was no relevant medical history and the patient was otherwise healthy. Radiographic examination revealed the presence of five impacted bilateral maxillary and mandibular distomolars. A pericoronal radiolucency was also observed associated with the lower right third molar. In the maxilla there were three distomolars, two on the right and one on the left side. Two distomolars were also found in the mandible, one on each side (Fig. 1A).

The maxillary right fourth and fifth molars were bone-impacted and the upper right third molar was soft tissue impacted. Surgical findings included proximity of the right upper fourth and fifth and the left third and fourth molars to the maxillary sinus, a mesioangular impacted lower left third molar and a buccolingually positioned mandibular left fourth molar and horizontally lower right third and fourth molars.

All impacted teeth were extracted during four sessions under local anesthesia. Due to the minimal amount of residual bone in the right mandibular angle and the increased risk of fracture in this area, elastic traction was applied for 10 days before the last surgery programmed to extract the third and fourth right lower molars. Following this procedure, the right mandibular nerve was severed which caused mild parasthesia in the lip. In the postsurgical radiograph, there was no sign of fractures and healing was uneventful (Fig. 1B).

DISCUSSION

Supernumerary teeth may occur singly, multiply, unilaterally or bilaterally in the maxilla, mandible or both. Their shape and size may resemble the group of teeth at the site where they are found in the jaws or there may be little or no resemblance at all [5].

Several theories have been suggested for the occurrence of supernumerary teeth. Abnormal activity of the dental lamina can result in the formation of extra tooth buds by additional formation or splitting of the existing ones. According to the dichotomy theory, supernumerary teeth may arise from clumps of remaining epithelium after the breaking up of the tooth band which subsequently becomes activated to form new teeth. The association of heredity has also been suggested and most cases are determined by multifactorial inheritance [8].

Obtaining a complete medical history is critical when a patient with multiple supernumeraries is to be treated. In order to consider multiple supernumeraries as non-syndromic, associated conditions like cleft lip with or without cleft palate and syndromes such as cleidocranial dysostosis and Gardner Syndrome should be ruled out [8].

Supernumerary teeth may erupt normally, remain impacted, appear inverted or assume an ectopic position or an abnormal path of eruption. Their development might precipitate a variety of complications such as crowding,

delayed eruption, development of a diastema, cystic lesions such as dentigerous cysts and resorption or rotation of adjacent teeth. Therefore early diagnosis, proper evaluation and appropriate treatment are essential [5].

Treatment options for impacted teeth include observation, intervention, relocation and extraction. On occasion, there may be some overlap between these treatment options. Observation involves no treatment other than monitoring the patient clinically and radiologically [9]. Kokich describes the surgical and orthodontic management of impacted teeth and identifies their position and angulation, length of treatment, available space and the presence of keratinized gingival tissue as critical factors that can affect the prognosis and treatment outcomes [10].

Appropriate and thorough radiographs, especially in mandibular third molars, are essential for correct diagnosis and management of multiple supernumeraries [5,11].

REFERENCES

- 1- Kokten G, Balcioglu H, Buyukertan M. Supernumerary fourth and fifth molars: a report of two cases. *J Contemp Dent Pract*. 2003 Nov 15;4(4):67-76.
- 2- Gorlin RJ, Goldman HM. Thoma's oral pathology. 6th ed. St Louis: C V Mosby; 1970.
- 3- Neville BW, Damm DD, Allen CM, Bouquot JE. *Oral and maxillofacial pathology*, 2nd ed. Philadelphia, PA: WB Saunders; 2002.
- 4- Williams P. An unusual case of hyperdontia. *Br Dent J* 1998 Apr 25;184(8):371-2.
- 5- Ramsaran AS, Barclay S, Scipio E, Ogunsalu C. Non-syndromal multiple buried supernumerary teeth: report of two cases from the English-speaking Caribbean and a review of the literature. *West Indian Med J* 2005 Oct;54(5):334-6.
- 6- Eley BM. Periodontosis occurring with supernumerary molars. *J Dent* 1974 Jul;2(4):167-70.
- 7- Schofield JJ. Multiple symmetrical supernumerary molar teeth. *Br Dent J* 1973 Nov 20;135(10):455-6.
- 8- Batra P, Duggal R, Parkash H. Non-syndromic multiple supernumerary teeth transmitted as an autosomal dominant trait. *J Oral Pathol Med* 2005 Nov;34(10):621-5.
- 9- Kokich VG, Mathews DP. Surgical and orthodontic management of impacted teeth *Dent Clin North Am* 1993 Apr;37(2):181-204.
- 10- Kokich VG, Mathews DP. Surgical and orthodontic management of impacted teeth. *Dent Clin North Am* 1993;37(2):181-204.
- 11- Fisher SE. Maxillary sixth molars. *Br Dent J* 1982 May 18;152(10):356.