

Original Article

Intestinal Parasitic Infections in Renal Transplant Recipients

M Nateghi Rostami¹, H Keshavarz¹, E Eskandari², EB Kia^{1,*}, M Rezaeian¹

¹ Dept. of Medical Parasitology and Mycology, School of Public Health, Medical Sciences/University of Tehran, Iran

² Center for Research and Training in Skin Diseases and Leprosy, Medical Sciences/University of Tehran, Iran

(Received 20 Apr; accepted 15 Jun 2007)

Abstract

Background: Organ transplant recipients can experience serious diseases from infections due to emerging and reemerging parasitic infections. This study was carried out to evaluate the prevalence of intestinal parasites among renal transplant recipients of Iran.

Methods: This cross-sectional study was conducted from June 2003 to August 2004 on renal transplant recipients in Iran. A total of 706 fecal samples obtained from randomly selected population originated from all over Iran. Patient's information was recorded in a questionnaire before sampling. A sample of stool was taken from each person. Direct wet smear examination, formalin-ether concentration, Ziehl-neelsen staining, and agar plate culture were done for each sample.

Results: Totally 32 patients (4.5%) were positive for parasitic infections. In searching for emerging parasitic infections, the most prevalent parasites were found to be *Blastocystis hominis*, *Giardia lamblia* and *Entamoeba coli*, respectively. The merely ova which were seen were related to *Hymenolepis nana*. With investigation of healthy control, no significant difference was found between transplanted and normal population.

Conclusion: The population showed controlled rate of intestinal infections probably due to regular awareness concerning risks of opportunistic infections; albeit regular surveillance through routine examination of stool samples for parasites seems considerably advantages the transplant recipient patients.

Keywords: Intestinal parasites, Renal transplant recipients, Emerging parasitic infections, Iran

Introduction

Intestinal parasites continue to be a significant health problem in both developed and developing countries. Immunocompromised patients, including patients with AIDS, solid organ transplant recipients, and patients on immunosuppressive therapy for disorders, are at risk for infections-particularly opportunistic parasites (1). Because of the continuous administration of immuno-suppressive drugs among renal transplant recipients, they are prone to acquire many opportunistic parasite infections. There exists a growing quantity of case reports from numerous countries around the world that have linked

the emerging parasites like *Cryptosporidium* spp., to clinical manifestations such as diarrhea, abdominal pain, and anorexia (2-4).

Many of these pathogens, particularly the intracellular protozoa that predominantly affect the small intestine, produce their most overwhelming effects in patients with immune deficiency (5). Parasites important to transplantation are largely those that can replicate in humans and that cause infection, the intensity of which is regulated by immune mechanisms in the normal host (6). Although parasitic infections generally are asymptomatic in otherwise healthy individuals, their manifestations in immunocompromised individuals, including pa-

*Corresponding author: Tel: +98 21 88951392, E-mail: rezaian@sina.tums.ac.ir

tients receiving immunosuppressive therapy with corticosteroids, are more devastating.

Organ transplant recipients can experience serious diseases from infection due to the parasites like Microsporidia, *Strongyloides stercoralis*, *Cryptosporidium parvum*, and *Giardia lamblia*. For instance, *Cryptosporidium* has emerged as a cause of infectious disease in AIDS patients, organ transplant recipients, children, travelers, and the elderly (3, 7, 8). In strongyloidiasis, hyperinfection is a recognized complication of *S. stercoralis* in kidney recipients. Occult intestinal infection can remain quiescent for many years, becoming apparent after initiation of immunosuppression (9). In spite of these notable features, in Iran renal transplant donors and recipients are not routinely screened for intestinal parasitic infections.

In monitoring of emerging parasites, this study was conducted to determine the prevalence of intestinal parasitic infections in renal transplant recipients.

Materials and Methods

Study population

This cross-sectional study was conducted at the laboratory of intestinal protozoa, School of Public Health, Tehran University of Medical Sciences, Iran from June 2003 to August 2004. The people included in this study were residents of different areas all over the country who passed between 1 to 20 yr of their transplantation. A total of 706 stool samples were obtained from randomly selected patients referred to the Shafaa Central Clinic for renal transplant patients, in Tehran. Each case was asked to fill out a questionnaire including demographic and baseline data and socioeconomic conditions.

Specimens' collection

One sample of stool was taken from each person in special plastic container and transferred to laboratory at the end of each working day. Stool samples were divided to two parts: One part added with formalin reservoir to be examined by concentration method. The second part

designated for direct smear, Ziehl-neelsen staining and agar plate culture.

Direct wet smear examination

Wet films are particularly appropriate for immediate detection of trophic forms of protozoa, allowing the study of mobility of the organisms. A small portion of feces was mixed with a drop of normal saline on a clean slide and a coverslip was placed on the preparation. After thoroughly checking under low power of the microscope, an iodine stain was prepared by adding a small drop of the reagent to the wet film.

Formalin-ether concentration method

About 1 g of stool emulsified in a small volume of 10% formalin in a tube, using an applicator stick, made up to about 3 ml, and mixed well. Then about 3 ml of ether was added and shook vigorously for 30- 40 seconds. The tube topped up to about 15 ml with 10% formalin, remixed, and poured through a mesh gauze sieve into a 15 ml glass conical centrifuge tube which then centrifuged at 450 g for 5 min. Three upper layers carefully discarded and deposit used to prepare smears for staining. Preparations examined for ova and cysts of parasites.

Ziehl-neelsen staining method

A small quantity of fecal material smeared in a uniform film on a slide and allowed to air dried. Then fixed in methanol for 3 min and stained with strong carbol fuchsin for 15- 20 min. After rinsing thoroughly in tap water, slides were decolorized in acid alcohol (1% HCl in methanol) for 15- 20 seconds followed by rinsing thoroughly in tap water. For counterstain, 0.4% methylene blue was used for 30- 60 seconds. After last rinsing thoroughly and air drying, slides were examined using lightfield microscope under x 40 and x 100 objectives (10). Totally 95 samples were examined in this method.

Agar plate culture

Around 300 samples were cultured on agar plate for detection of *S. stercoralis* larva infections. Agar medium was autoclaved and dispensed in sterilized dishes. After drying on room temperature, approximately 3 g of fresh stool specimen

was placed in the center of the plate. The plates sealed with adhesive tape and incubated at room temperature for 48 h. Plates then examined by naked eye for the presence of larval tracks and also reexamined under the microscope at low magnification. The plates kept for 5 d to confirm that they are negative.

Statistical methods

Data was analyzed using SPSS (version 12) software. Significance of difference was analyzed by Chi-squared test. $P < 0.05$ was considered significant.

Results

General basic data is outlined in Table 1. The included population was being asked for history of previous parasitic infection and chronic diseases like Diabetes-mellitus and gastro-intestinal disorders.

Totally 32 cases (4.5%) were positive for intestinal parasite infection (Table 2). *Blastocystis hominis* infected 12 patients who consisted 1.7% of total population. Four other species of intestinal parasites were identified. Among them three were protozoa and one was helminthic infection. *Giardia lamblia* (1.4%) and *Entamoeba coli* (0.8%) ranked second and third in the prevalence, respectively. Among specimens, 2 were positive for *Idamoeba butchli* cysts. The only helminthic infection was *Hymenolepis nana* (0.3%).

For comparison, 100 stool specimens were collected from healthy people who did not receive kidney transplantation. The difference between patient group and healthy control subjects in regard of different parasitic infections rate was not statistically significant (Table 2).

The age distribution of population under study is outlined in Fig.1. The trend shows that most patients aged between 30 and 45 yr (middle-aged).

Table 1: Baseline characteristics of renal transplanted population studied for intestinal parasitic infections in Iran

Characteristics	Frequency No. (%)
Gender	
Male	414 (58.6)
Female	292 (41.4)
History of parasitic infection	
Yes	6 (0.8)
No	700 (99.2)
Chronic disease	
Yes	530 (75.1)
No	176 (24.9)
Education	
Illiterate	121 (17.1)
Elementary	216 (30.6)
Secondary	127 (18.0)
High school	163 (23.1)
University	79 (11.2)
Total	706 (100)

Table 2: Frequency of intestinal parasitic infections in renal transplant patients compared with healthy control in Iran

Infection	Frequency No. (%)	
	Patients	Healthy control
No infection	674 (95.5)	93 (93)
<i>Blastocystis hominis</i>	12 (1.7)	4 (4)
<i>Giardia lamblia</i>	10 (1.4)	2 (2)
<i>Entamoeba coli</i>	6 (0.8)	-
<i>Idamoeba butchli</i>	2 (0.3)	1 (1)
<i>Hymenolepis nana</i>	2 (0.3)	-
Total	706 (100)	100 (100)

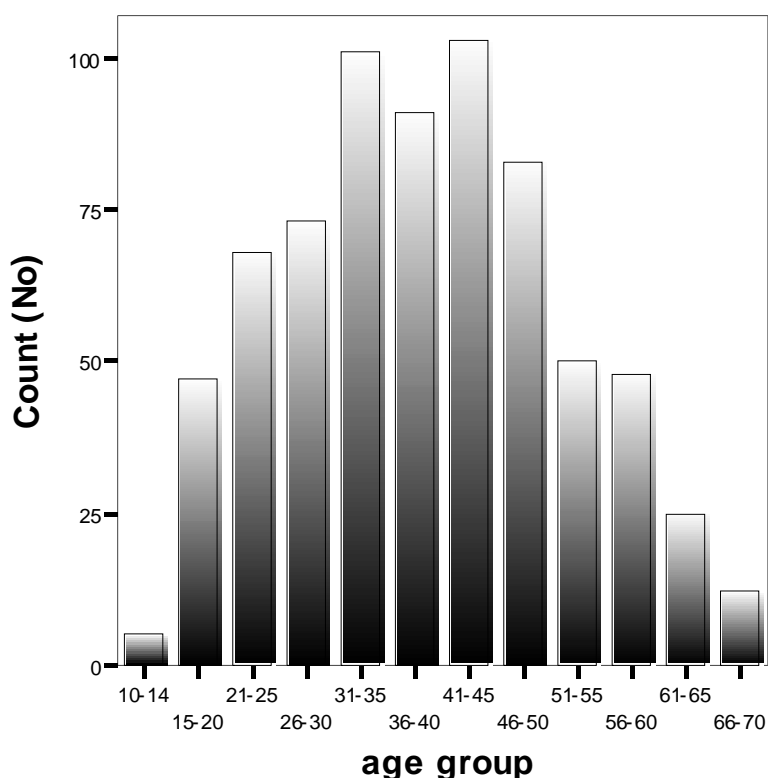


Fig. 1: Age distribution of renal transplanted population studied for intestinal parasitic infection in Iran

Discussion

Emerging intestinal parasites have gained increasing attention as important opportunistic pathogens responsible for clinically important infections in immunocompromised patients (1, 2, 11, 12). Some of these intestinal parasites are frequently seen in renal transplant recipients. These organisms are responsible for both acute and chronic diarrhea. Diarrhea is usually self-limiting, however, may last weeks to months, causing significant morbidity (13). We were searching for emerging and reemerging parasitic infections among the targeted population. Parasites of special interest, due to their role in pathogenicity in transplantation, include *Cryptosporidium parvum*, *Cyclospora cayetanensis*, *Entamoeba histolytica/dispar* and nematode *Strongyloides stercoralis*.

In this study, among 706 investigated specimens of patients, 4.5% (n= 32) of cases were

positive for intestinal parasite infection. Recently, retrospectively analysed 657 renal transplanted population, Valar *et al.* found the prevalence of parasitic infections 2.4% (16/657) (12).

We found no evidence of difference between transplanted subjects and normal healthy population for acquiring the focused parasitic infections. The reason that the results obtained from patients are similar to those of non infected population might lie in the fact that some of these infestations are not opportunistic, thus show no correlation to immune status of the patients. This is the same as results obtained from HIV+ patients in comparison with healthy control people (7).

It is a fact that, the use of Cyclosporine A (CsA) has become a cornerstone in prophylactic immunosuppression among renal transplant recipients. Cyclosporine A with powerful properties of immunosuppression, acts on parasitic

infections in various ways (14). In laboratory models, CsA reduces survival and growth in a wide range of protozoa and helminths. CsA is apparently antiparasitic against malaria, *Schistosoma*, adult tapeworms and filarial nematodes. By contrast, it acts as an immunomodulator against trypanosomes and *Giardia*, by exacerbating the infection. This more or less could explain the higher incidence of giardiasis infection among the population. There are few reports in the literature regarding giardiasis in immunocompromised hosts. In a retrospective analysis of 657 adult renal transplant recipients published in 2007, *S. stercoralis* (n= 11) was the most frequent agent, followed by *G. lamblia* (n= 3) (12).

There are considerable reports of cases of *S. stercoralis* hyperinfection as a consequence of immunosuppressive treatment following kidney transplantation (15- 19). In diagnosis, agar plate culture is a sensitive method for recovery of *Strongyloides* larva (20). The value of the preference of agar plate culture in detection of *S. stercoralis* compared to formalin ether concentration method reportedly is from 1.6 to 6 times (21). However, culture of roughly 300 stool specimens from renal patients yielded lack of infection with *S. stercoralis* larva. This might be under the influence of parasiticidal action of CsA. Reportedly CsA has reduced the incidence of strongyloidiasis in renal transplant recipients (11, 14). Although in the analysis of Valvar *et al.* the most prevalent infection was reported to be *S. stercoralis*, but none of infected patients received CsA in their immunosuppressive drug protocol (12).

Parasites such as *Cryptosporidium* spp. and *Blastocystis hominis* are often asymptomatic or responsible for limited signs in normal people, but may cause prolonged and life-threatening infections with gastrointestinal complaints, mainly diarrhea, in immunocompromised patients (22). The staining we used is enough sensitive to detect coccidian oocysts from feces. Modified Ziehl-Neelsen staining was introduced for staining cryptosporidial oocysts by many workers

and has proved useful in the laboratory diagnosis of other coccidia (23-26). In the work of Ok *et al.* of the 69 recipients, 13 (18.8%) had *Cryptosporidium* spp. in at least one fecal specimen (22). Results of a study on 23 renal transplanted individuals showed 34.8% were infected with *C. parvum* (27).

Blastocystis hominis is an intestinal protozoan that is emerging as an important cause of diarrhea in the immunosuppressed population. We found *B. hominis* the most frequent protozoal infection among transplanted patients. Based on another investigation of fecal specimens from renal transplant recipients, totally 27 (39.1%) had *B. hominis* (12). Rao *et al.* reported two cases of diarrhea caused by this organism in renal transplant recipients (4).

Cyclospora cayetanensis is a recently described protozoan capable of causing diarrhea in immunocompetent and immunodeficient patients. In accordance with our study, none of investigated specimens were positive regarding *C. cayetanensis* infection. One study in which *C. cayetanensis* were detected by using different types of fecal stains showed that the sensitivity of modified Ziehl-Neelsen is very high (100%) in comparison with the other stains (24).

In the present study, fecal examination for the ova of parasites revealed only 2 cases of *H. nana* in the specimens. Studies which made on intestinal helminthiasis by stool examination of 2427 inhabitants of 18 villages in the south of Iran revealed that the second most prevalent helminth was *Hymenolepis nana* with an overall prevalence of 16.8%. (28). Some investigators attribute a great importance to some helminthic infection amongst immunocompromised patients (6, 29, 30). But in many countries around the world, protozoa are more commonly the cause of gastrointestinal infections than are helminths (31). Consistent with our results, there are numerous studies which show intestinal protozoa are more prevalent than helminths in immunodeficient patients (1, 6, 8, 32-34) and also in healthy people (31, 35-37).

Lack of significant difference between patients and healthy people in the rate of infection might show the successful approaches to awareness of transplant recipients about the potential risks of acquisition of infectious diseases due to regular administration of suppressive drugs. Health system managers should continue to offer education that help prevention of infectious disease in this immunosuppressed patients. Improving the level of knowledge about parasitic infections and relevant risk factors would have obvious influence on the withdrawing the infection rate amongst this population.

Routine examinations of stool samples for parasites would significantly benefit the transplant recipient individuals by contributing to reduce morbidity. These results highlight the fact that unusual parasites like *B. hominis* as well as *G. lamblia* should be looked for and treated in cases of diarrhea occurring in renal transplant recipients.

In conclusion, since renal transplant patients are candidate to acquire many infections, general preventive measures against infection must be taken and patients must be screened for intestinal infections during administration of immunosuppressive medicine.

Acknowledgements

We are grateful for kind cooperation of clinical staff of Shafaa Central Clinic during patients' reception and sampling. This work was financially supported by the Vice Chancellor for Research, Tehran University of Medical Sciences, Iran.

References

1. Fantry L. Gastrointestinal infections in the immunocompromised host. *Current Opinion in Gastroenterology*. 2002; 18(1):34-9.
2. Huston CD, Petri WA. Emerging and re-emerging intestinal protozoa. *Current Opinion in Gastroenterology*. 2001; 17(1): 17-23.
3. Goodgame RW. Understanding intestinal spore-forming protozoa: Cryptosporidia, Microsporidia, *Isospora*, and *Cyclospora*. *Annals of Internal Medicine*. 1996; 124(4): 429-41.
4. Rao K, Sekar U, Iraivan KT, Abraham G, Soundararajan P. *Blastocystis hominis*- An emerging cause of diarrhoea in renal transplant recipients. *Journal of Association of Physicians of India*. 2003; 51:719-21.
5. Farthing MJG. Treatment options for the eradication of intestinal protozoa. *Nature Clinical Practice Gastroenterology & Hepatology*. 2006; 3(8):436-45.
6. Fishman JA. *Pneumocystis-carinii* and Parasitic Infections in Transplantation. *Infectious Disease Clinics of North America*. 1995; 9(4):1005.
7. Meamar AR, Rezaian M., Mohraz M, Zahabiun F, Hadighi R, Kia EB. A comparative analysis of intestinal parasitic infections between HIV+/AIDS patients and non-HIV infected individuals. *Iranian J Prasitol*. 2007; 2(1):1-6.
8. Zali MR, Mehr AJ, Rezaian M, Meamar AR, Vaziri S, Mohraz M. Prevalence of intestinal parasitic pathogens among HIV-positive individuals in Iran. *Japanese Journal of Infectious Diseases*. 2004; 57(6): 268-70.
9. DeVault GA, King JW, Rohr MS, Landreneau MD, Brown ST. Opportunistic infections with *S. stercoralis* in renal transplantation. *Rev Infect Dis*. 1990; 12(4):653-71.
10. Casemore DP. ACP Broadsheet 128: June 1991. Laboratory methods for diagnosing cryptosporidiosis. *J Clin Pathol* 1991; 44(6): 445-51.
11. Barsoum RS. Parasitic infections in organ transplantation. *Exp Clin Transplant*. 2004; 2:258.
12. Valar C, Keitel E, Dal Pra RL, Gnatta D, Santos AF. Parasitic infection in renal transplant recipients. *Transplant Proc*. 2007; 39: 460-2.

13. Weber R, Deplazes P. Emerging Parasitic Diseases in Man- Infection with Microsporidia and *Cyclospora Sp.* Schweizerische Medizinische Wochenschrift. 1995; 125(18): 909-23.
14. Chappell LH, Wastling JM. Cyclosporin A: antiparasite drug, modulator of the host-parasite relationship and immunosuppressant. Parasitology. 1992; 105 Suppl: S25-40.
15. Meyrier A, Sraer JD, Kourilsky O. Fatal Pulmonary strongyloidiasis after kidney transplantation. Ann Med Interne. 1980; 131:153-6.
16. Waller IV, Copland P, Gabriel R. S. *stercoralis* infection in renal transplant recipients. Br Med J. 1981; 282(6263):524.
17. Van der Woude FJ, Kager PA, Weits J, van der Jagt EJ. S. *stercoralis* hyperinfection as a consequence of immunosuppressive treatment. Neth J Med. 1985; 28(8): 315-7.
18. Stone WJ, Schaffner W. *Strongyloides* infections in transplant recipients. Semin Respir Infect. 1990; 5(1):58-64.
19. Reddy IS, Swarnalata G. Fatal disseminated strongyloidiasis in patients on immunosuppressive therapy: report of two cases. Indian J Dermatol Venereol Leprol. 2005; 71:38.
20. Koga K, Kasuya S, Khamboonruang C, Sukhavat K, Ieda M, Takatsuka N, *et al.* A modified agar plate method for detection of *Strongyloides stercoralis*. Am J Trop Med Hyg. 1991; 45(4):518-21.
21. Kia EB, Mahmoudi M, Zahabiun F, Meamar AR. An evaluation on the efficacy of agar plate culture for detection of *Strongyloides stercoralis*. Iranian J Parasitol. 2007; 2(1):29-34.
22. Ok UZ, Cirit M, Uner A, Ok E, Akcicek F, Basci A *et al.* Cryptosporidiosis and blastocystosis in renal transplant recipients. Nephron. 1997; 75(2):171-4.
23. Henriksen SA, Pohlenz JFL. Staining of cryptosporidia by a modified Ziehl-Neelsen technique. Acta Vet Scand. 1981; 22:594-6.
24. El Nagggar HH, Handousa AE, El Hamshary EM, El Shazly AM. Evaluation of five stains in diagnosing human intestinal coccidiosis. J Egypt Soc Parasitol. 1999; 29(3): 883-91.
25. Clarke SC, McIntyre M. Acid-fast bodies in faecal smears stained by the modified Ziehl-Neelsen technique. Br J Biomed Sci. 2001; 58(1):7-10.
26. El-Shazly AM, Gabr A, Mahmoud MS, Aziz SS, Saleh WA. The use of Ziehl-Neelsen stain, enzyme-linked immunosorbent assay and nested polymerase chain reaction in diagnosis of cryptosporidiosis in immuno-competent, -compromised patients. J Egypt Soc Parasitol. 2002; 32(1):155-66.
27. Chieff PP, Sens YA, Paschoalotti MA, Miorin LA, Silva HG, Jabur P. Infection by *C. parvum* in renal patients submitted to renaltransplant or hemodialysis. Rev Soc Bras Med Trop. 1998; 31(4):333-7.
28. Ghadirian E, Missaghian G. Studies on intestinal helminthiasis in the south of Iran. II. The areas of Kazeroun, Borazjan and Bandar Bushehr. Iran J Publ Hlth. 1973; 1(3):126-37.
29. Da Silva CV, Ferreira MS, Borges AS, Costa-Cruz JM. Intestinal parasitic infections in HIV/AIDS patients: Experience at a teaching hospital in central Brazil. Scandinavian Journal of Infectious Diseases. 2005; 37(3):211-5.
30. Hailemariam G, Kassu A, Abebe G, Abate E, Damte D, Mekonnen E *et al.* Intestinal parasitic infections in HIV/AIDS and HIV seronegative individuals in a teaching hospital, Ethiopia. Japanese Journal of Infectious Diseases. 2004; 57(2):41-3.
31. Harp JA. Parasitic infections of the gastrointestinal tract. Current Opinion in Gastroenterology. 2003; 19(1):31-6.
32. Moreno A, Gatell JM, Mensa J, Valls ME, Vila J, Claramonte X *et al.* The Incidence of Enteropathogens in Patients Infected by the Human-Immunodeficiency- Virus. Medicina Clinica. 1994; 102(6):205-8.

33. Wiwanitkit V. Intestinal parasite infestation in HIV infected patients. *Current Hiv Research*. 2006; 4(1):87-96.
34. Escobedo AA, Nunez FA. Prevalence of intestinal parasites in Cuban acquired immunodeficiency syndrome (AIDS) patients. *Acta Tropica*. 1999; 72(1):125-30.
35. Motakef M, Rezvani H, Elahi R. A survey of intestinal parasitic infestation in Khorasan Province, Iran. *Pahlavi Medical journal*. 1977; 8(2):208-19.
36. Rossignol JF. Parasitic gut infections. *Current Opinion in Infectious Diseases*. 1998; 11(5): 597-600.
37. Juckett G. Intestinal protozoa. *American Family Physician*. 1996; 53(8):2507-16.