



## Myocardial Infarction in a Patient with Prosthetic Aortic Valve

Seyed Kianoosh Hoseini, MD\*, Maryam Mehrpooya, MD

Tehran Heart Center, Tehran University of Medical Sciences, Tehran, Iran.

Received 2 October 2006; Accepted 9 November 2006

### Abstract

A 45-year old man with a history of Aortic Valve replacement presented with acute chest pain which was diagnosed to be anterior wall myocardial infarction. He received thrombolytic therapy with streptokinase. Echocardiography and fluoroscopy showed normally functioning ball and cage aortic prosthesis. Coronary arteriography showed globular filling defect in midportion of left anterior descending coronary artery, most probably embolized thrombus. The patient underwent medical treatment especially warfarin with higher range of INR without any intervention. He had a smooth in-hospital course and uneventful recovery.

The Journal of Tehran Heart Center 3 (2006) 171-172

**Keywords:** Aortic prosthesis • Myocardial infarction • Ball and cage valve

### Introduction

Approximately 6 percent of all patients with STEMI do not have coronary atherosclerosis demonstrated by coronary angiography or at autopsy. Many of these cases are caused by coronary artery spasm and or thrombosis; perhaps with underlying endothelial dysfunction or small plaques that are not apparent on coronary angiography. One of the additional causes includes coronary emboli (perhaps from small mural thrombosis, a prolapsed mitral valve or a myxoma).<sup>1</sup>

We report the case of a patient with myocardial infarction caused by an uncommon etiology that was an embolized clot.

### Case Report

A 45-year-old man, with a 20-year history of aortic valve replacement and under occasional treatment with warfarin

5mg and INR (about 2), was admitted because of acute, severe chest pain which was initiated 10 hours before presentation. He had clinical scenario of acute coronary syndrome and 12-lead- ECG showed ST-Elevation and T- wave Inversion on v2-v6, a characteristic of acute anterior wall MI. The diagnosis was documented with increase in Troponin level and creatine kinase MB.

The echocardiography showed akinesia in apical segments and normally functioning ball and cage valve in aortic position. Thrombolytic therapy was done with streptokinase infusion. After a good hospital course, the patient was discharged and was referred to our hospital, which is a tertiary center. The perfusion scan with technetium 99 showed stress induced perfusion defect in the apical segment: so coronary angiography was planned. Fluoroscopy revealed normally functioning Starr-Edward, Aortic prosthesis. In selective coronary arteriography, Right coronary and left circumflex

\*Corresponding Author: Seyed Kianoosh Hoseini, Assistant Professor of Cardiology, Tehran University of Medical Sciences, Tehran Heart Center, Karegar Ave, Tehran, Iran. 1411713138. Tel: +98 21 88029702. Fax: +98 21 88029731. E-mail: K\_Hoseini@TUMS.ac.ir.

coronary arteries were normal. Left anterior descending artery was free of atherosclerotic plaques but there was a globular filling defect in mid to distal portion of LAD after major diagonals (Figure 1). This filling defect was most probably an embolized thrombus from ball and cage valve. The case was presented at the weekly conference of our center and general consensus about him was medical treatment and continuation of warfarin with higher levels of INR and intermittent follow up. He had excellent and uneventful in hospital course and discharge. In a follow up visit after 3 months, the patient was good without symptoms of myocardial ischemia.

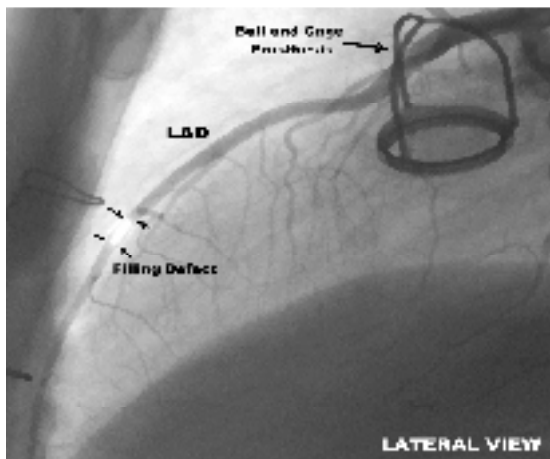


Figure 1. Coronary angiography of the patient in lateral view which shows globular filling defect in the mid-part of left anterior descending artery

## Discussion

Embolic complications due to prosthetic heart valves are common. One report documented a left main coronary artery thrombus extending from a Starr – Edward's aortic valve prosthesis 22 years after its placement. It resulted in unstable angina and a small myocardial infarction. This rare complication illustrates the importance of adequate anticoagulation.<sup>2</sup> The most common etiology for obstructive prosthetic heart valve thrombosis (PVT), is thrombus formation due to inadequate anticoagulation.<sup>3</sup> A short course of thrombolytic therapy may be considered first line therapy for PVT.<sup>4</sup> In a necropsy observation of 20 patients Who died after AVR with a Hufnagel trileaflet prosthesis, it was revealed that four of seven patients dying early had extensive PVT causing obstruction of one coronary arterial ostium on both sides.<sup>5</sup> Some emboli seemed triggered by the valve prosthesis.<sup>6</sup> Acute coronary syndrome might be caused by isolated thrombus on aortic prosthetic valve without any insufficiency of prosthesis and embolic finding due to thrombosed valve.<sup>7</sup> Therefore, we must take into account any embolized clot in any patient with acute coronary syndrome and prosthetic valve.

## References

1. Antman EM, Braunwald E. ST-Elevation Myocardial Infarction: pathology, pathophysiology and clinical features. In: Braunwald E, Zipes DP, Libby P, eds. Braunwald's Heart Diseases. 7th ed. Philadelphia: Elsevier Saunders; 2001. p. 1150-1151.
2. Jain A, Mazanek GJ, Armitage JM. Unstable angina secondary to left main coronary thrombus extending from prosthetic aortic valve. *Cathet Cardiovasc Diagn* 1998;15:271-272.
3. Bollag L, Attenhofer Jost CH, Vogt PR, Linka AZ, Rickli H, Oechslin E. Symptomatic mechanical heart valve thrombosis: high morbidity and mortality despite successful treatment options. *Swiss Med Wkly* 2001;131:109-116.
4. Manteiga R, Carlos Souto J, Altes A, Mateo J. Short-course thrombolysis as the first line of therapy for cardiac valve thrombosis. *J Thorac Cardiovasc Surg* 1998;115:780-784.
5. Fishbein MC, Roberts WC, Golden A, Hafnagel CA. Cardiac pathology after aortic valve replacement using Hufnagel trileaflet prostheses: a study of 20 necropsy patients. *Am Heart J* 1975;89:443-448.
6. Mistiaen W, Van Cauwelaert P, Muylaert P, Sys SU. Thromboembolic events after aortic valve replacement in elderly patients with a Carpentier-Edwards Perimount pericardial bioprosthesis. *J Thorac Cardiovasc Surg* 2004;127:1166-1170.
7. Chikazawa G, Nakano H, Nagata H, Tabuchi T. Huge thrombus growing on an aortic prosthetic valve detected in acute coronary syndrome. *Jpn J Thorac Cardiovasc Surg* 2005;53:386-388.