

# MÖEBIUS SYNDROME AND CORPUS CALLOSUM AGENESIS; A CASE REPORT

M. R. Ashrafi\*, I. Hussain and S. M. A. Zamani

Department of Pediatric Neurology, Children's Hospital Medical Center, Medical Sciences/  
University of Tehran, Tehran, Iran

---

**Abstract-** Moebius Syndrome is a rare congenital disorder of the facial and abducens nerve. Other cranial nerves may be involved, such as V, IX and XII. Several central nervous system anomalies including hypoplastic or dysplastic brain stem, straightening of the fourth ventricle floor, focal necrosis and calcifications of cranial nerve nuclei have been reported in association with Moebius syndrome, but we report a 18 months old boy of moebius syndrome with corpus callosum agenesis that has not been reported yet.

*Acta Medica Iranica*, 44(6): 432-434; 2006

© 2006 Tehran University of Medical Sciences. All rights reserved.

**Key words:** Moebius syndrome, corpus callosum agenesis, the straightening of fourth ventricle floor.

---

## INTRODUCTION

Moebius syndrome is a rare congenital disorder of the facial and abducens nerve. Other cranial nerves may be involved, such as V, IX, and XII, resulting in speech and communication problems. Known associations of this syndrome that have been reported in literatures are oro-facial malformations, musculoskeletal defects, cardiac malformations, and mental retardation (1). Lower brain stem hypoplasia, hypoplastic cerebellum, focal necrosis and calcifications of cranial nerve nuclei and straightening of the fourth ventricle floor have been reported in neuro-imaging of Moebius syndromes; we report a case of Moebius syndrome associated with corpus callosum agenesis.

## CASE REPORT

An eighteen months old boy was referred to our

Received: 2 Oct. 2005, Revised: 30 Nov. 2005, Accepted: 15 Feb. 2006

**\* Corresponding Author:**

M.R. Ashrafi, Department of Pediatric Neurology, Children's hospital  
Medical Center, Medical Sciences/University of Tehran, Tehran, Iran  
Tel: +98 21 66920982, Fax: +98 21 66923054  
E-mail: ashrafim@sina.tums.ac.ir

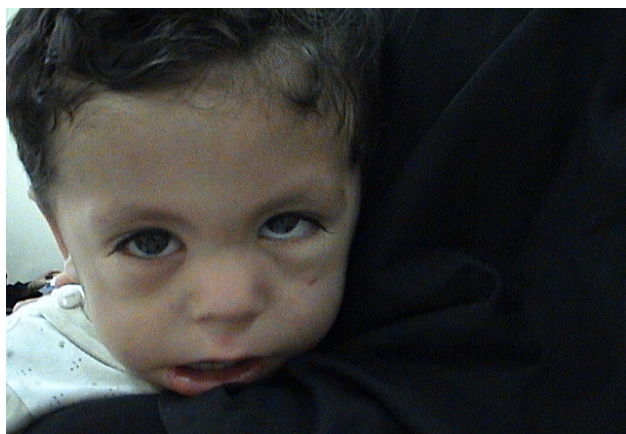
center because of neuro-developmental delay. He was the product of cesarean section delivery due to fetal distress.

His parents are not relative. The Apgar score was 4 and 8 at 1 and 5 minutes, respectively. The routine ultrasonography at 30<sup>th</sup> week of gestation age showed fetal hydrocephaly. No certain intervention was performed and his mother was just under observation until delivery.

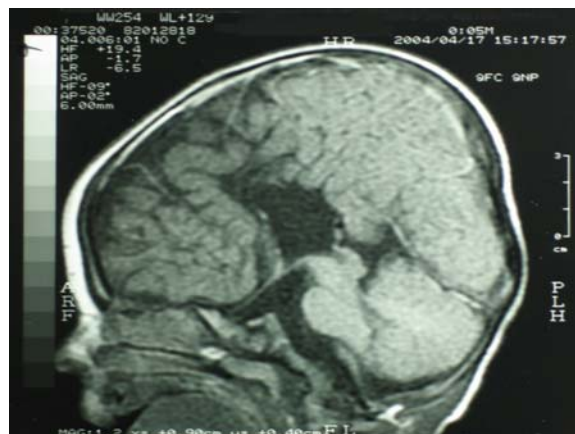
He was hospitalized in NICU for 10 days due to lethargy and respiratory distress. The head holding was completed at 6 months of age, he began to sit since 12 months of age and his current weight, head circumference and height are within normal limits. Neurologic examination revealed a hypotonic infant with inability to stand unsupported.

He was unable to blink his eyes, smile, or frown. He had facial diplegia and convergent strabismus secondary to bilateral palsy of the facial and abducens nerves.

No musculoskeletal abnormalities were found. The metabolic screening tests; serum lactate and ammonium were within normal limits. Brain CT scan and MRI shows corpus callosum agenesis and straightening in the floor of the fourth ventricle (Fig. 2, 3).



**Fig 1.** Facial diplegia and convergent strabismus.



**Fig. 3.** MRI shows corpus callosum agenesis.

## DISCUSSION

Congenital facial and abducens palsy was originally described by Von Graefe in 1880. In 1888, Möbius drew attention to patients with congenital nonprogressive bilateral facial and abducens palsy. The eponym Möbius syndrome has since been used for this condition.

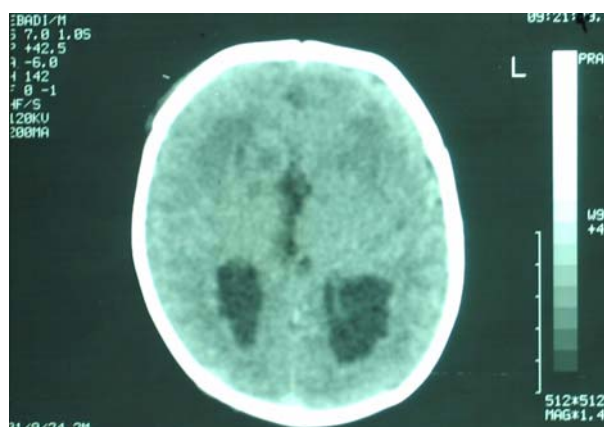
Moebius syndrome is frequently accompanied by dysfunction of other cranial nerves. The abducens nerve is typically affected, and often the hypoglossal nerve as well. In addition, orofacial malformations, defects of the musculoskeletal system, and mental retardation are seen in patients with Moebius syndrome. Most cases are sporadic, but familial occurrence can occur with variable inheritance. The etiology and pathogenesis of the Moebius syndrome are unclear (3), but two explanations have been

proposed: a primary genetic (4) and a primary ischemic cause (5).

The postulated etiologic mechanisms are based on limited pathologic observations, which include agenesis or hypoplasia of cranial nerve nuclei, atrophy of cranial nerve nuclei secondary to peripheral nerve involvement, and primary muscle involvement without abnormalities in the brainstem or cranial nerves (6).

Partial or complete absence of the corpus callosum is one of the common developmental anomalies of the brain. It has an incidence of 2.3% as detected by CT scan in the developmentally disabled population. The corpus callosum develops between the 8<sup>th</sup> and 22<sup>nd</sup> weeks of gestation and disturbed embryogenesis during this period can lead to corpus callosum hypogenesis or agenesis. The etiology of this anomaly is often unknown. It can be part of chromosomal syndrome (such as trisomy 8, 13, 18 or 21) as well as a number of X-linked syndromes (Aicardi's syndrome, FG syndrome and CRASH syndrome). Corpus callosum anomalies also can accompany some inborn errors of metabolism disorders. Corpus callosum agenesis can occur with other brain malformations such as migrational disorders, Chiari malformation II and encephalocele (7).

Hypoplastic or dysplastic brain stem, hypoplastic cerebellum, Dandy Walker variant malformation, focal necrosis and calcifications of cranial nerve nuclei, straightening of the fourth ventricle floor and absence of middle cerebellum peduncles have been reported in CT or MRI of patients with Moebius



**Fig. 2.** CT-scan shows parallel lateral ventricles with colpocephaly.

syndrome (8). In our knowledge corpus callosum agenesis in association with Moebius syndrome has not been reported yet. Although the Moebius syndrome reported as a syndrome of rhombencephalic maldevelopment involving motor nuclei and axons as well as traversing long tracts (2), therefore, corpus callosum agenesis can possibly be seen in Moebius syndrome, but needs other reports.

## REFERENCES

1. Peleg D, Nelson GM, Williamson RA, Widness JA. Expanded Moebius syndrome. *Pediatr Neurol.* 2001 Apr; 24(4):306-309.
2. Verzijl HT, van der Zwaag B, Cruysberg JR, Padberg GW. Moebius syndrome redefined: a syndrome of rhombencephalic maldevelopment. *Neurology.* 2003 Aug 12; 61(3):327-333.
3. Legum C, Godel V, Nemet P. Heterogeneity and pleiotropism in the Moebius syndrome. *Clin Genet.* 1981 Oct; 20(4):254-259.
4. Stabile M, Cavaliere ML, Scarano G, Fels A, Valiani R, Ventruto V. Abnormal B.A.E.P. in a family with Moebius syndrome: evidence for supranuclear lesion. *Clin Genet.* 1984 May; 25(5):459-463.
5. St Charles S, DiMario FJ Jr, Grunnet ML. Moebius sequence: further in vivo support for the subclavian artery supply disruption sequence. *Am J Med Genet.* 1993 Aug 15; 47(2):289-293.
6. Aicardi J. Malformations of the CNS. In: Aicardi J, editor. *Diseases of the nervous system in childhood.* 2<sup>nd</sup> edition. Mackeith Press; 1992. p. 108-202.
7. Marszal E, Jamroz E, Pilch J, Kluczevska E, Jablecka-Deja H, Krawczyk R. Agenesis of corpus callosum: clinical description and etiology. *J Child Neurol.* 2000 Jun; 15(6):401-405.
8. Ouanounou S, Saigal G, Birchansky S. Moebius syndrome. *AJNR Am J Neuroradiol.* 2005 Feb; 26(2):430-432.