

An Insight into Laser Revascularization of the Heart

Mahmood Mirhoseini, MD, FACS, FACC*, Mary Cayton RN, BSN, PA,
Suhas Shelgikar MD, FACC

Medical college of Wisconsin, Milwaukee, Wisconsin, U. S. A

The notion to revascularize the ischemic myocardium from left ventricular cavity is not a new concept. The possibility was first proposed by Wearn in 1933.¹

The work by mechanical means was followed by Walter, Massimo and later on by Sen.²⁻⁵ The fundamental concept was based on two factors; first a reptilian heart model and second the heart muscle structure which possesses a spongy character, en-meshed by sinusoids bathing the myocytes.

The Vineberg operation⁶ consisted of the insertion of a mammary artery into the heart muscle to establish a connection between the small capillaries (angiogenesis) and heart circulation in hopes of alleviating angina in ischemic heart disease.

In reptile hearts, the coronary arteries play a minor role in the perfusion of myocardium. Their circulation is supplied by canals from left and right ventricular cavities. So, ligation of coronary branches does not produce myocardial infarction (Figure 1-3).

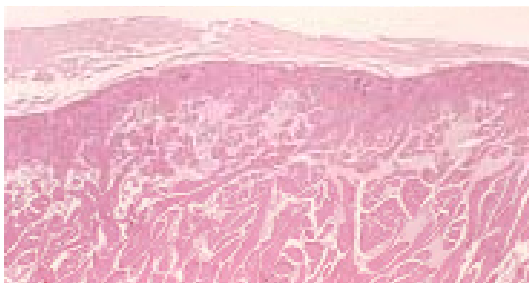


Figure 1 . In Reptilian heart, coronaries are small and most perfusions of the heart muscle is by way of channels directly from the ventricular cavity (Histology of snake heart muscle).




Figure 2. Schematic drawing of Reptile heart with channels from ventricular cavity and small size of coronaries

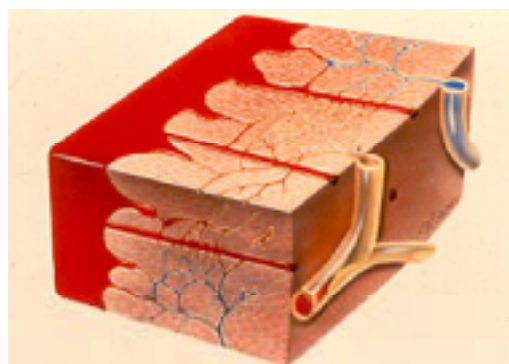


Figure 3. Laser channels connect left ventricular cavity to sinusoids and perfuse the myocardium (A schematic drawing)

The mechanical recanalization had a serious drawback. These channels were closed due to initial trauma, causing inflammatory reaction cell infiltration, fibrosis and eventual closure of the channels.

*Corresponding Author: Mahmood Mirhoseini, Professor of Cardiac Surgery, Tehran Heart Center, Experimental Research unit, North Kargar Street, Tehran, Iran. 14113138. Tel: +98 21 88029257. Fax: +98 21 88029256. E-mail: research@tehranheartcenter.org.

The discovery of laser (light Amplification by Stimulated Emission of Radiation) in early 1960 by Nobel Laureate, Dr Theodor Maimon inspired our team to examine the hypothesis of recanalizing the ischemic myocardium with CO2 laser^{7,8} (Figure 4).



Figure 4. Nobel Prize winner and inventor of laser Dr. T. Maimon

Our primary reason for selecting this wave length (10.6 micron) was because its excellent absorption by the water content of myocardium (80% of myocardium is water by weight). We were also encouraged because CO2 laser could be made to deliver pulses of short duration in order of milli seconds and of very high energy density.

Since the thermal relaxation time of myocardium is about 30 milli seconds and pulses of this order can be made, the thermal injury was very minimal and almost non existent (Mass conversion to energy photons and water vapor) ($E=mc^2$).

Consequently the channels would stay open and perfuse the myocardium.

This high powerful laser was loaned to us by scientist Dr. Polayni from the American optical company Boston. Mass. USA^{9,10} (Figure 5).




Figure 5. Original CO2 laser for TMLR puts approximately two million watts continuous wave, triggered electronically by P-R interval of ECG, with milliseconds Pulse duration (1970)

This laser with short pulse duration could produce channels

in myocardium clean and without thermal injury (Figure 6).

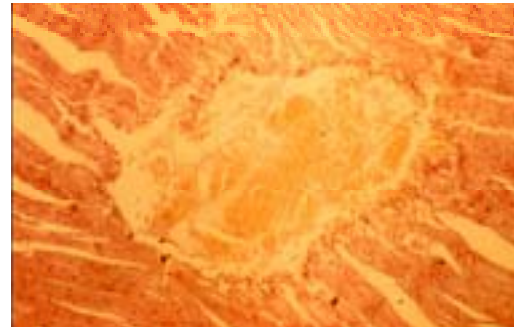


Figure 6. Thermal injury to myocardium was very small (less than one layer of cell)

With the help of my wife Mary Cayton, we worked in the laboratory (VA Center, Medical College of Wisconsin Milwaukee. Wis. USA), at nights, weekends and on holidays for over 24 years.¹¹⁻¹⁵

The expenses were paid by my own practice of cardiovascular surgery and some by the philanthropic foundation of St. Lukes Medical Center Milwaukee, USA.

The theory was proven to be correct and we published our work in 1970 in the Journal of Micro Surgery. This was a carefully randomized study on animals. The patency of the channels and their protection of ischemic myocardium were demonstrated in these animals after ligation of a major coronary artery.

As a matter of fact, we had one animal (a dog) in which all coronaries were ligated and she was lived for 2 years, kept in a kennel in rural area of Wisconsin.

Unfortunately, she died by being hit by a truck while chasing the vehicle. Since bringing this large laser equipment to an operating room for clinical trial was impossible, we designed a smaller co2 laser and experimented on cold cardioplegic heart.

Patency of these canals was also proven before clinical trail was allowed by Institutional Review Board Committee of St lukes medical center.

The initial trial was on 12 patients in combination with CABG.

The laser channels were made in areas that bypass was not possible, either due to total occlusion of the vessel or severe diffuse disease of the coronary.

Ischemic area was demonstrated prior to surgery by nuclear scan. Channels were made (one channel per each square centimeter). One of the pioneering patients expired 5 years later due to metastatic cancer of the Lung.

Patency of laser channels were demonstrated by tissue microscopy. These channels were covered by endothelium which proved to be true endothelium by DNA immunoperoxidase studies (Figure 7).

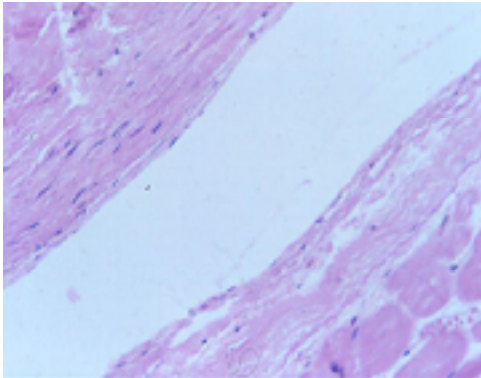


Figure 7. Patency of laser channels is demonstrated 51/2 years post of (autopsy specimen). The channels are covered by true Endothelium as proven by DNA immuno peroxides studies.

In some cases, ventriculogram showed patency of the channels (Figure 8).

The work was published in *Annals of Thoracic Surgery* in 1984, and later on in *Journal of clinical laser medicine and surgery*. Our laser laboratory noted that the laser pulse could produce arrhythmias (ventricular tachycardia and ventricular fibrillation) if pulse hits at ST segment of ECG in animals.

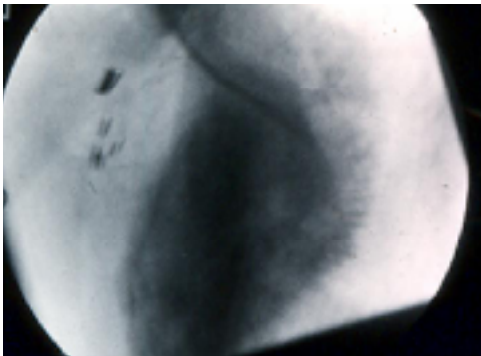


Figure 8. After 41/2 years, patency of laser channels are demonstrated by special technique of ventriculography during systole and diastole (Appreciation to General Electric Co. Milwaukee, U.S.A)

Therefore we synchronized the laser pulse at P-R intervals so the pulse would arrive at up stroke of R Wave.

This has two major advantages: 1. Prevents arrhythmias and 2. Laser arrives during diastole of cardiac cycle and the energy is quickly absorbed by the water content of blood; therefore it does not travel to the other side nor does it damage the interior of the left ventricular valves and cardio tendoneae.

During the last several years, numerous articles and even book chapters have been published presenting various techniques such as percutaneous, per catheter- by endoscopic and electromechanical imaging. Also different lasers and different wave lengths have been applied.

The TMLR (Trans-Myocardial Laser Revascularization) has been in the Armamentarium of the surgeon.

The alleviation of angina in end-stage coronary artery disease is proven.

Randomized multicenter studies conducted under auspices of FDA proved that this technique is superior to medical treatment in this group of patients. It relieves and drops angina class from class 4 or class 3 at least two classes and quality of life is also improved.¹⁶

The technique is used either as sole therapy or combined procedure with coronary bypass surgery.

One should keep in mind that the commercial lasers which are available do not meet the original standard on patency of the channels.

The channels usually close in a few weeks. The effect of laser at relieving pain is attributed to angiogenesis triggered by the laser channels.

The alleviation of angina is long lasting and some of our patients are 20 years past surgery. Therefore, placebo effect can not be considered. As a matter of fact, perfusion of myocardium in many patients has improved and demonstrated by nuclear scan and MRI; ejection fraction in a few patients has markedly increased.¹⁶

Since the commercial parties have rushed the production of this product and its presentation to the market without my personal approval, one could state with honesty that the final chapter in TMLR is not closed.

The goal should be to produce a laser like the first laser, to avoid thermal injury to myocardium in order to assure patency of laser channels and give patients the security of receiving the full-benefit of TMLR, the initial intention of this technique.

References

1. Wearn JT, Mettier SR, Klump TC, Zachiesche HJ. Nature of Vascular Communication between the coronary arteries and chambers of the heart. *Am Heart J* 1933;9:143-164.
2. Walter P, Hundeshagen H, Borst HG. Treatment of acute myocardial infarction by transmural blood supply from the ventricular cavity. *Eur Surg Res* 1971;3:130-138.
3. Walter P, Lamprecht W, Hundeshagen H, Borst HG. Myocardial blood flow and alterations in LDH isoenzymes in infarcted heart muscle after transmural punctures. *Cardiology* 1971;56:371-376.
4. Massimo C, Boffi L. Myocardial revascularization by a new method of carrying blood directly from the left ventricular cavity into the coronary circulation. *J Thor Surg* 1957;34:257-264.
5. M Mirhoseini M. Revascularization of the myocardium by laser. In: Davilla JC, ed. *Second Henry Ford Hospital International Symposium of Cardiac Surgery*. New York: Appleton Century Crofts; 1971. p. 398-420.
6. Vineberg AM. Development of an anastomosis between the coronary vessels and a transplanted internal mammary artery. *J Can Med Assoc* 1949; 18:839-850.
7. Mirhoseini M, Shelgikar S, Cayton MM. New Concepts in revascularization of the myocardium. *Annals of Thoracic Surg* 1988;45:415- 420.
8. Mirhoseini M, Cayton MM, Muckerheide M. Transventricular revascularization by laser. *Lasers Surg Med* 1982;2:187-198.



9. Polayni TG, Bredemeirer HC, David TW. A CO₂ laser for surgical research. *Medical Biological Engineering Comp* 1970;8:541-548.
10. Polayni TG. L Physics of the surgical laser. *Int Adv Surg Oncol* 1978;1:205-215.
11. Muhling OM, Wang Y, Jerosch-Herold M, Cayton MM, Wann LS, Mirhoseini MM, Wilke NM. Improved myocardial function after transmyocardial laser revascularization according to cine magnetic resonance in a porcine model. *J Thorac Cardiovasc Surg* 2004;128:391-395.
12. Wilke N, Jerosch Herold M, Cayton MM, Mirhoseini M. Transmyocardial laser revascularization protects ischemic tissue: quantitative monitoring with MRI. *J Magn Reson Imaging* 1997;8:85-89.
13. Wilke N, Cayton MM, Mirhoseini M. Ventricular function and volumes in acute ischemia after transmyocardial laser revascularization. *Lasers Surg Med* 1982;2:187-198.
14. Wilke N, Kroll K, Merkle H. Regional myocardial blood volume and flow: first pass MR imaging with polylysine-Gd-DTPA. *J Magn Reson Imaging* 1995;5:227-237.
15. Horvath KA, Cohn LH, Cooley DA, Crew JR, Frazier OH, Griffith BP, Kadipasaoglu K, Lansing A, Mannting F, March R, Mirhoseini MR, Smith C. Transmyocardial laser Revascularization Results of Multicenter Trial laser Revascularization as sole therapy. *J Thorac Cardiovasc Surg* 1997;113:645-654.
16. Muhling OM, Wang Y, Panse P, Jerosch-Herold M, Cayton MM, Wann LS, Mirhoseini MM, Wilke NM. Trans myocardial laser revascularization Preserves regional myocardial perfusion: an MRI first pass perfusion study. *Ca Vasc Research* 2003;57:63-70.